Normal anatomy on conventional radiographs

Brandon Owen
Consultant in Dental and Maxillofacial Radiology
Manchester University NHS Foundation Trust

Learning objectives

- Identify normal anatomical structures on dental radiographs.
- Differentiate common anatomical variations from pathology.

Why are conventional radiographs important?

- Lower radiation exposure
- More accessible
- Provide sufficient diagnostic information for many routine indications
- Less complex to interpret
- Aids justification and protocolling of CBCT examinations
- Complements interpretation of CBCT imaging

- *CBCT is not a replacement for conventional imaging*

Normal anatomy on conventional radiographs – Brandon Owen

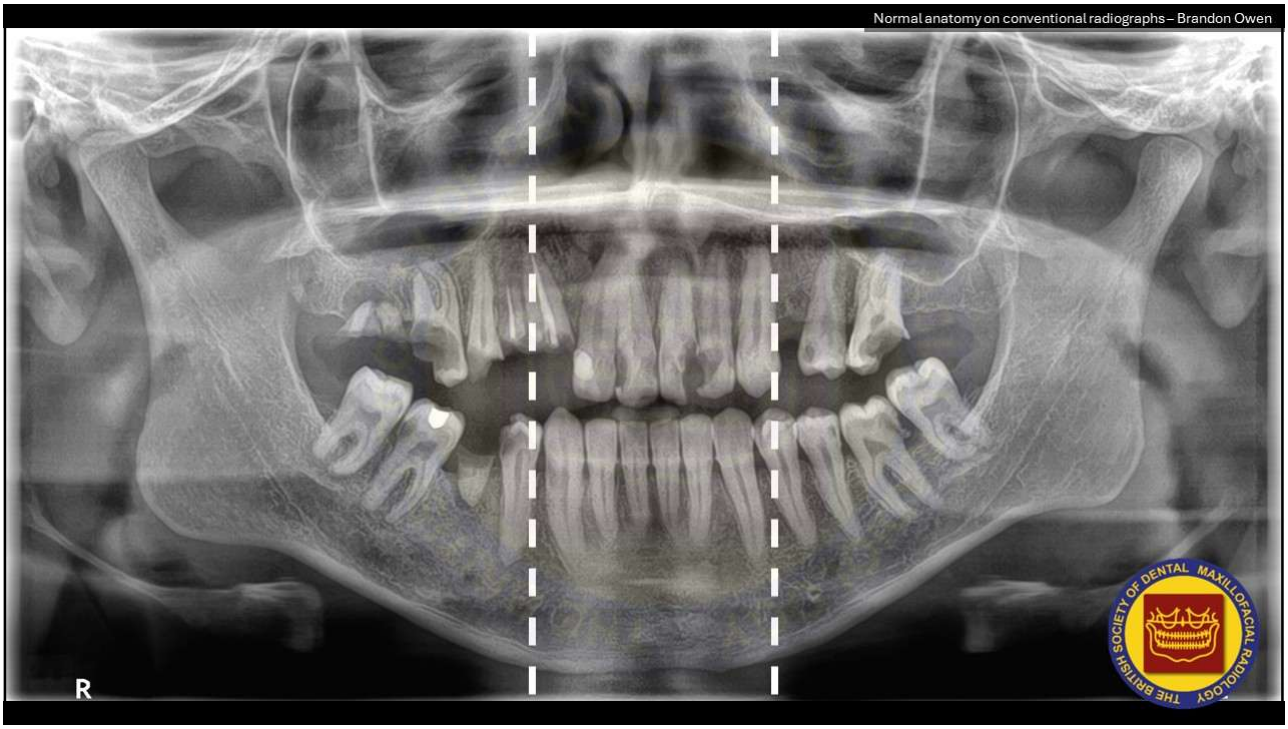

1)

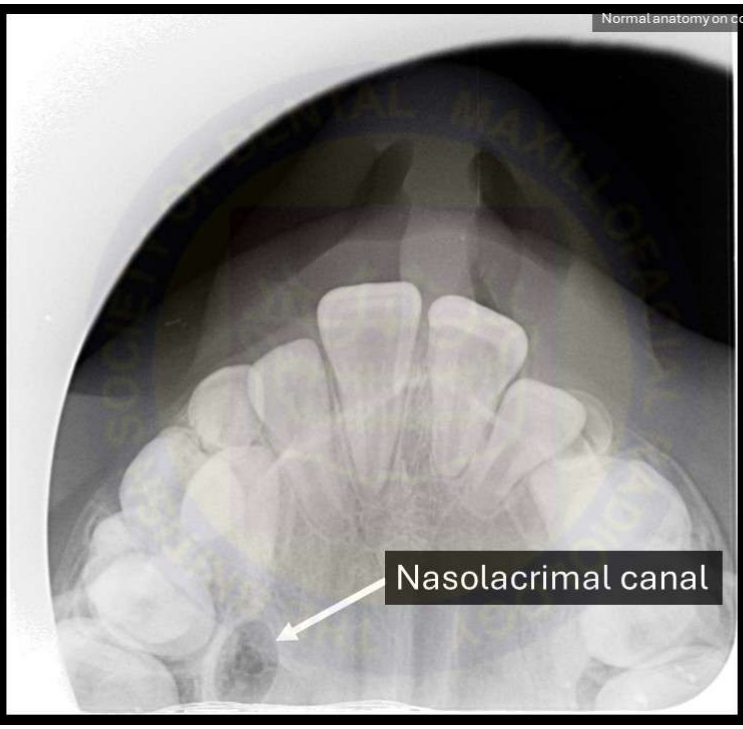
Normal anatomy on conventional radiographs – Brandon Owen
Nasolacrimal canal

2)

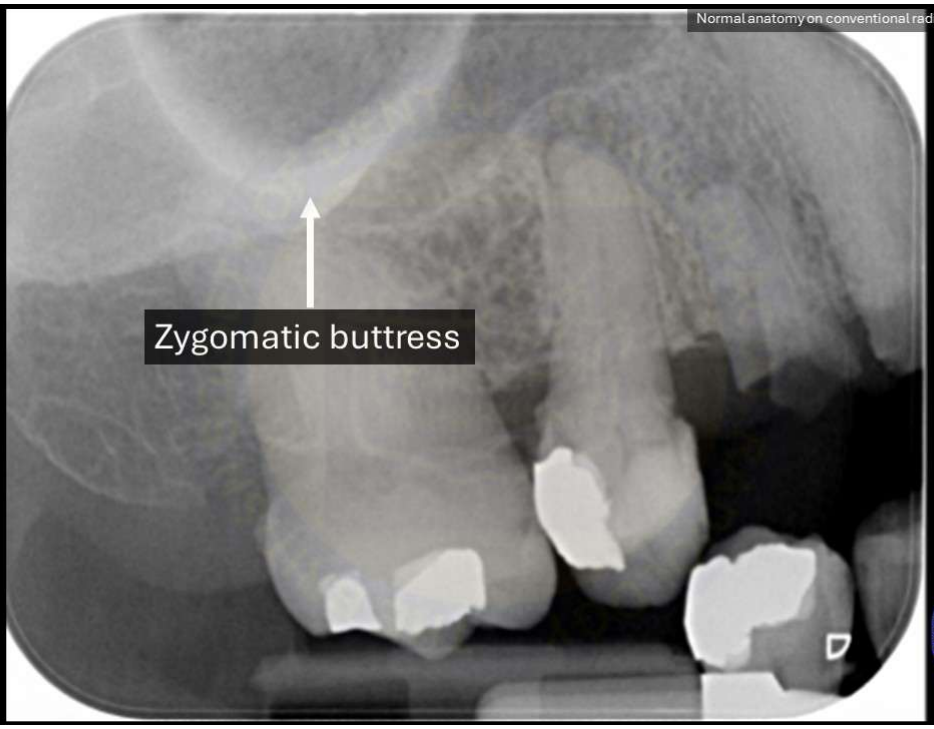
Normal anatomy on conventional radiographs – Brandon Owen
Zygomatic buttress

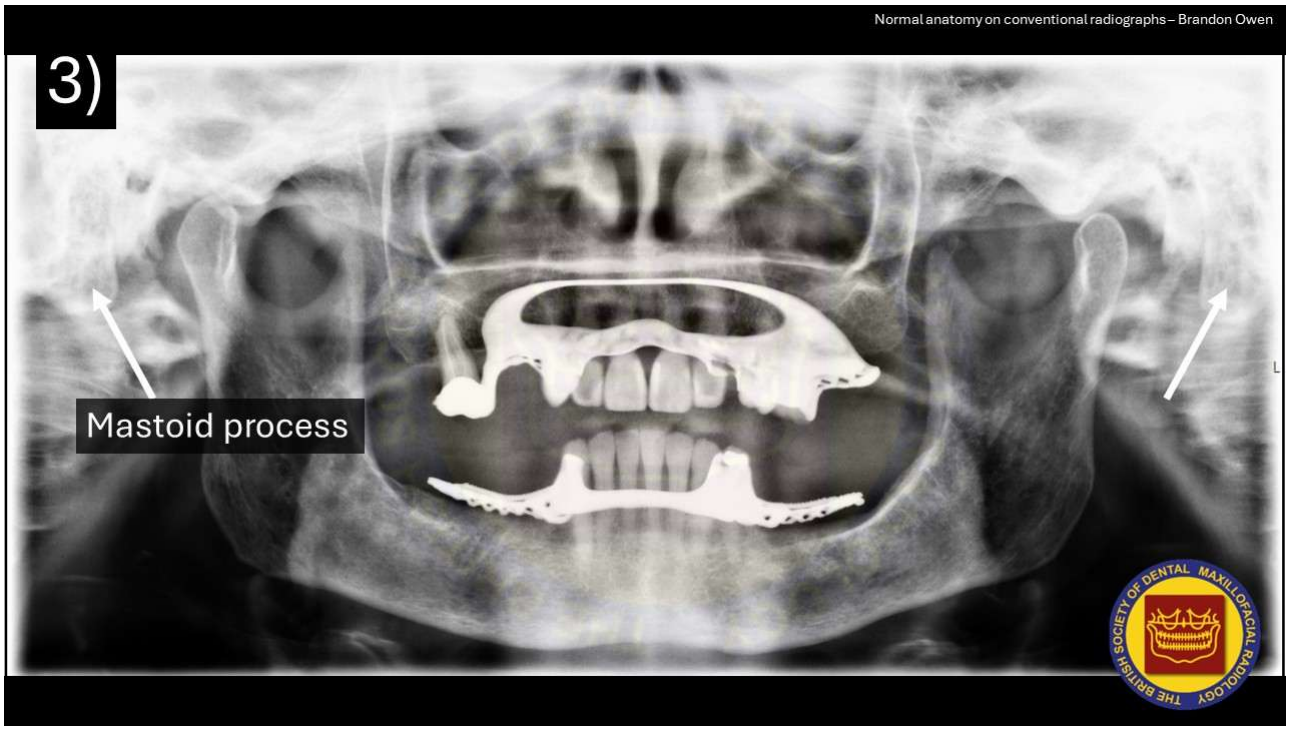
Normal anatomy on conventional radiographs – Brandon Owen
3)
Mastoid process
THE BRITISH SOCIETY OF DENTAL MAXILLOFACIAL RADIOLOGY

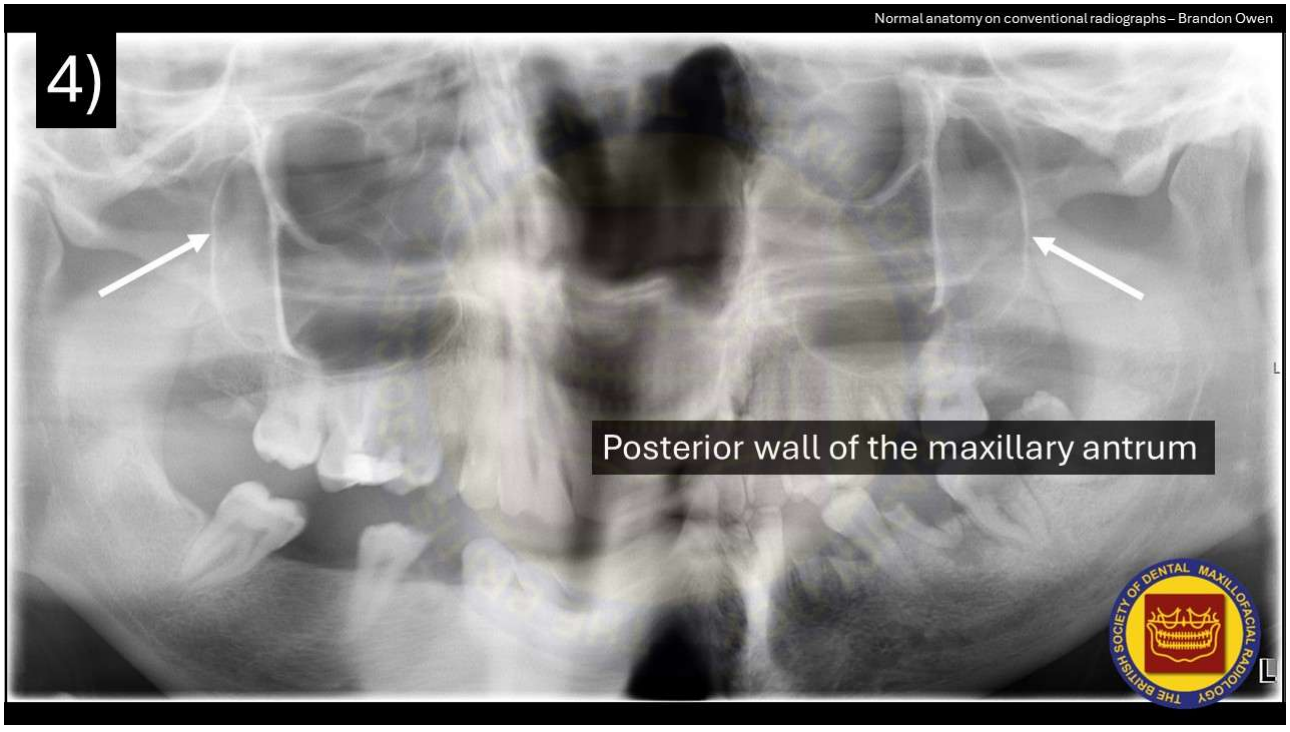
Normal anatomy on conventional radiographs – Brandon Owen
4)
Posterior wall of the maxillary antrum
THE BRITISH SOCIETY OF DENTAL MAXILLOFACIAL RADIOLOGY

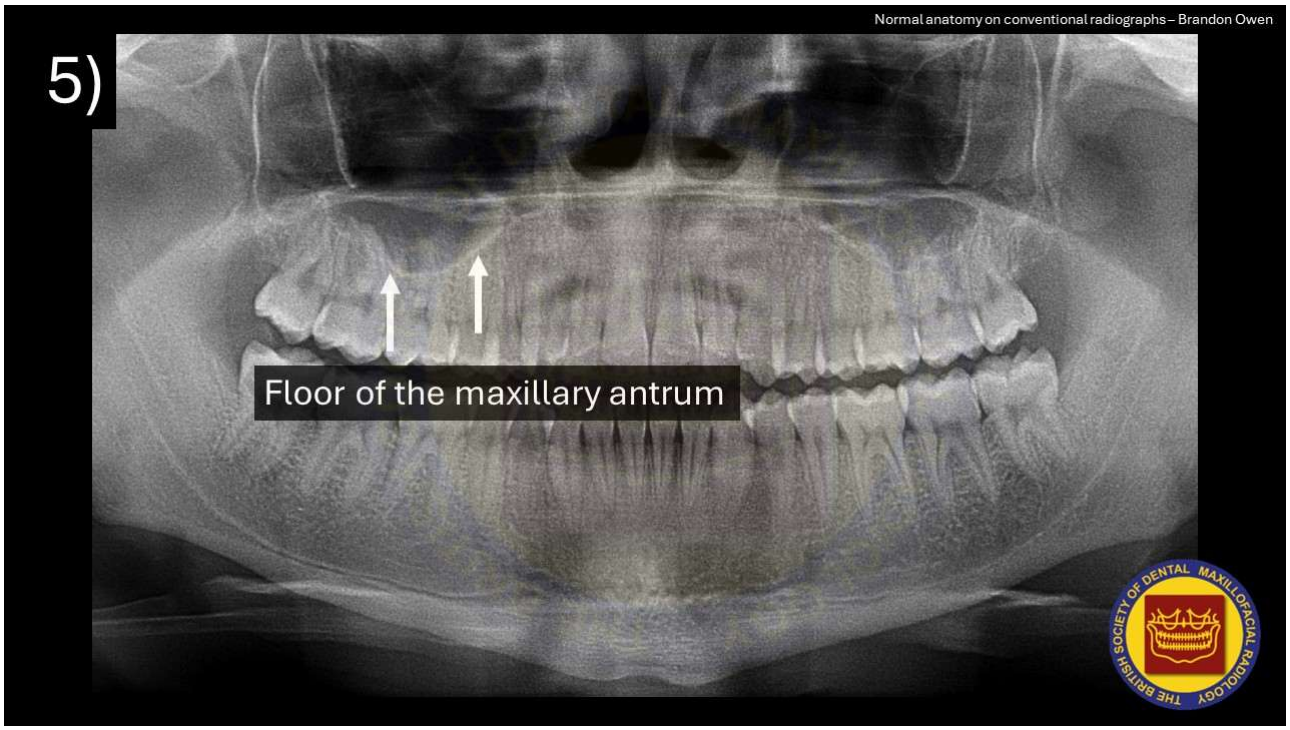
Normal anatomy on conventional radiographs – Brandon Owen
5)
Floor of the maxillary antrum

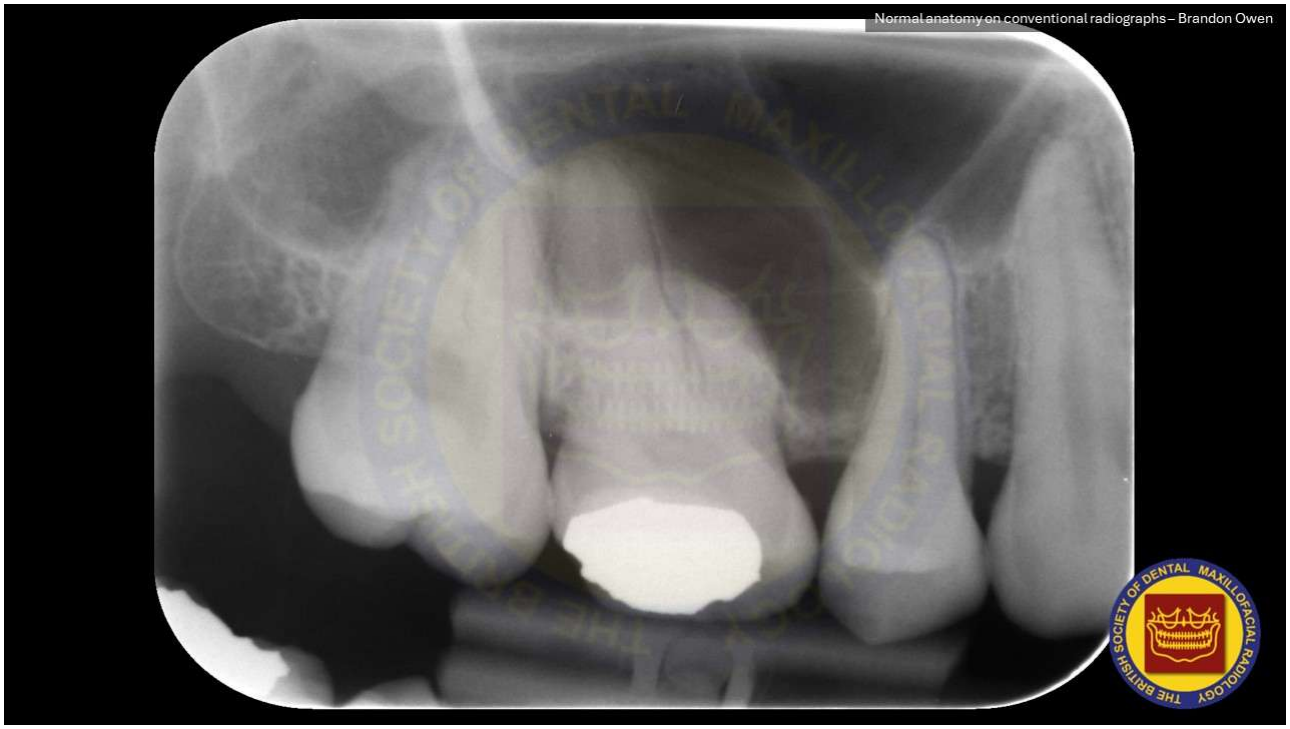
Normal anatomy on conventional radiographs – Brandon Owen

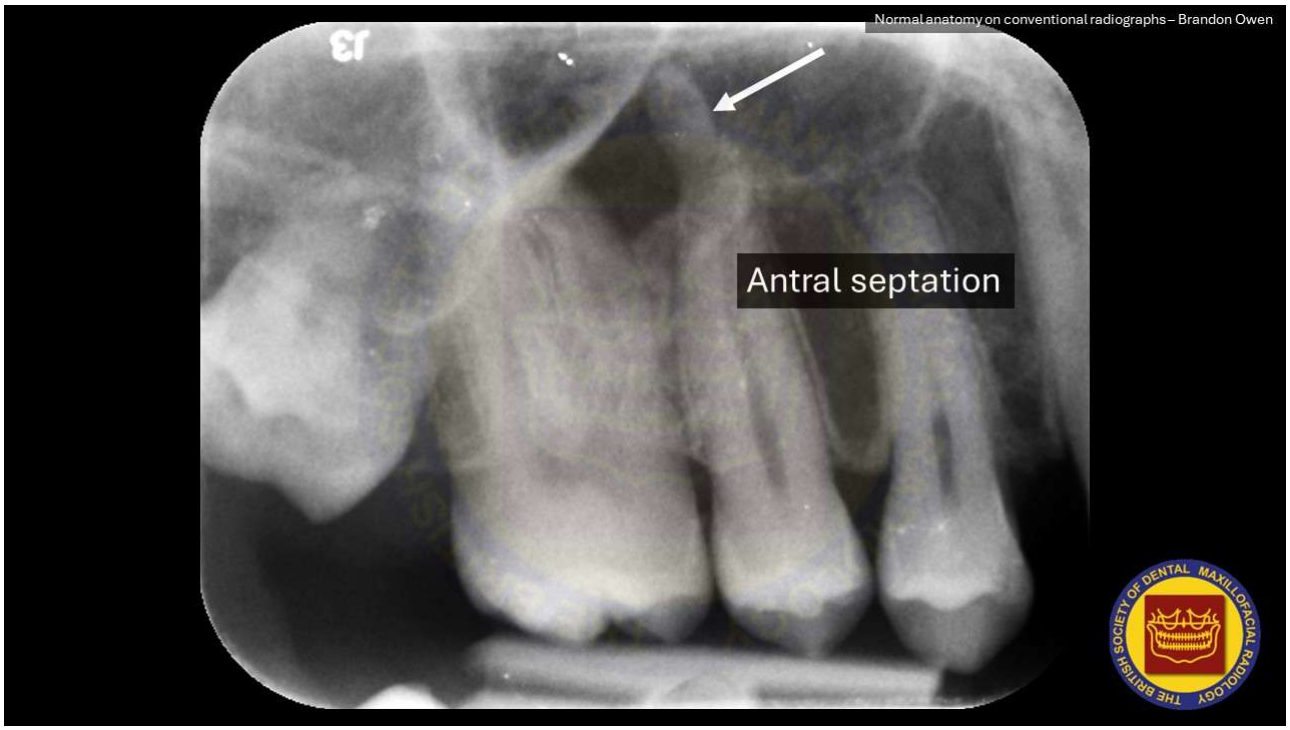
Normal anatomy on conventional radiographs – Brandon Owen
Antral septation
THE BRITISH SOCIETY OF DENTAL MAXILLOFACIAL RADIOLOGY

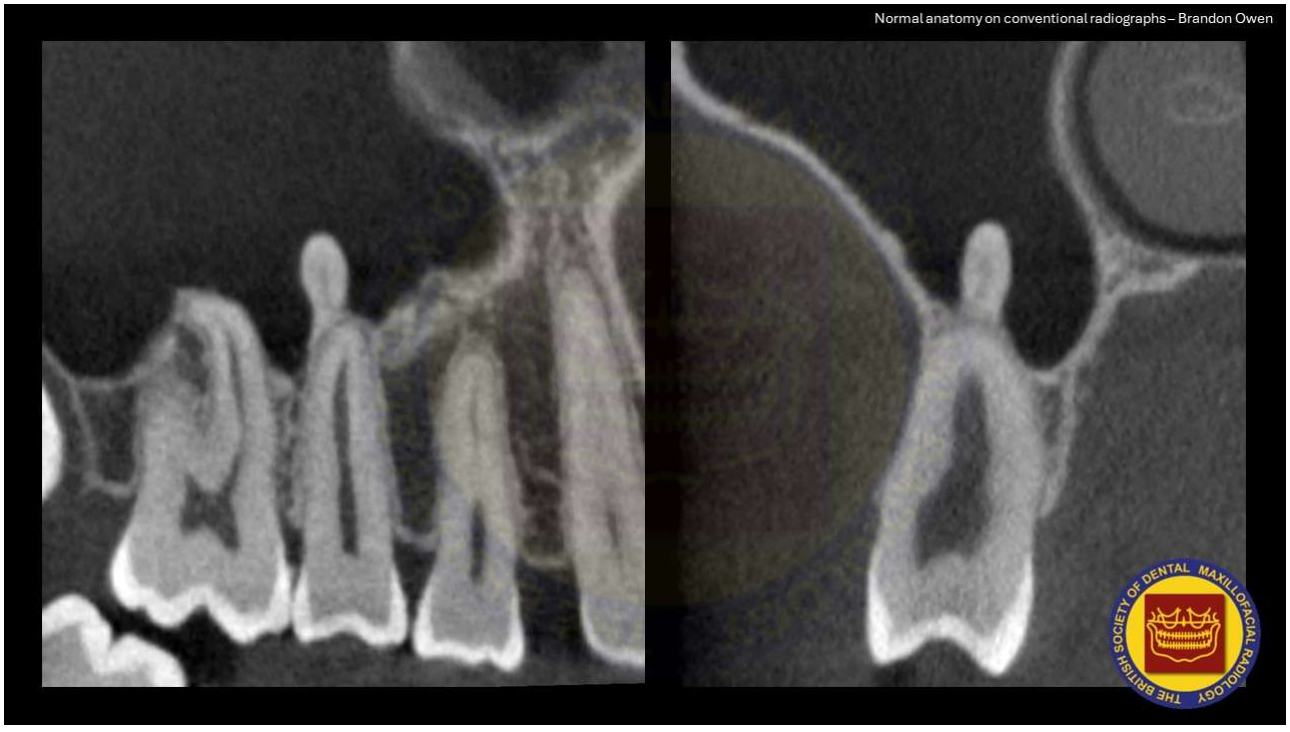
Normal anatomy on conventional radiographs – Brandon Owen
THE BRITISH SOCIETY OF DENTAL MAXILLOFACIAL RADIOLOGY

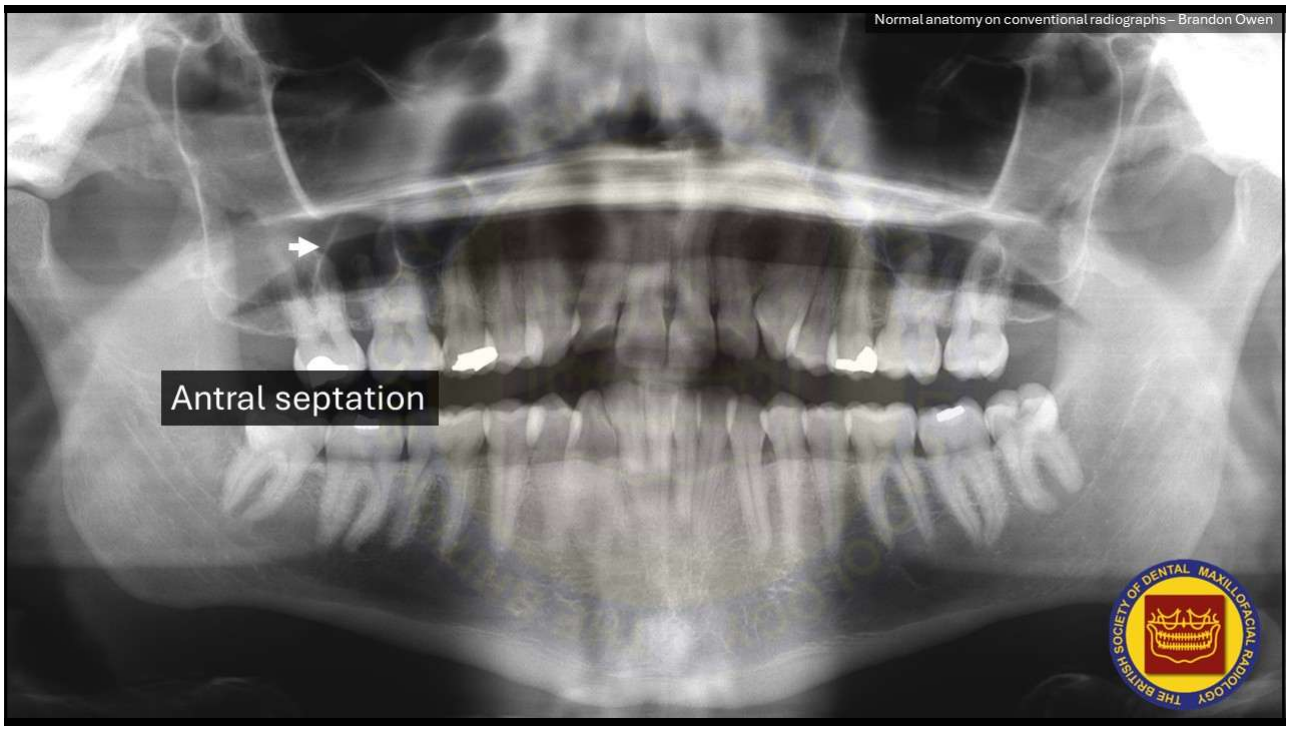
Normal anatomy on conventional radiographs– Brandon Owen
Antral septation

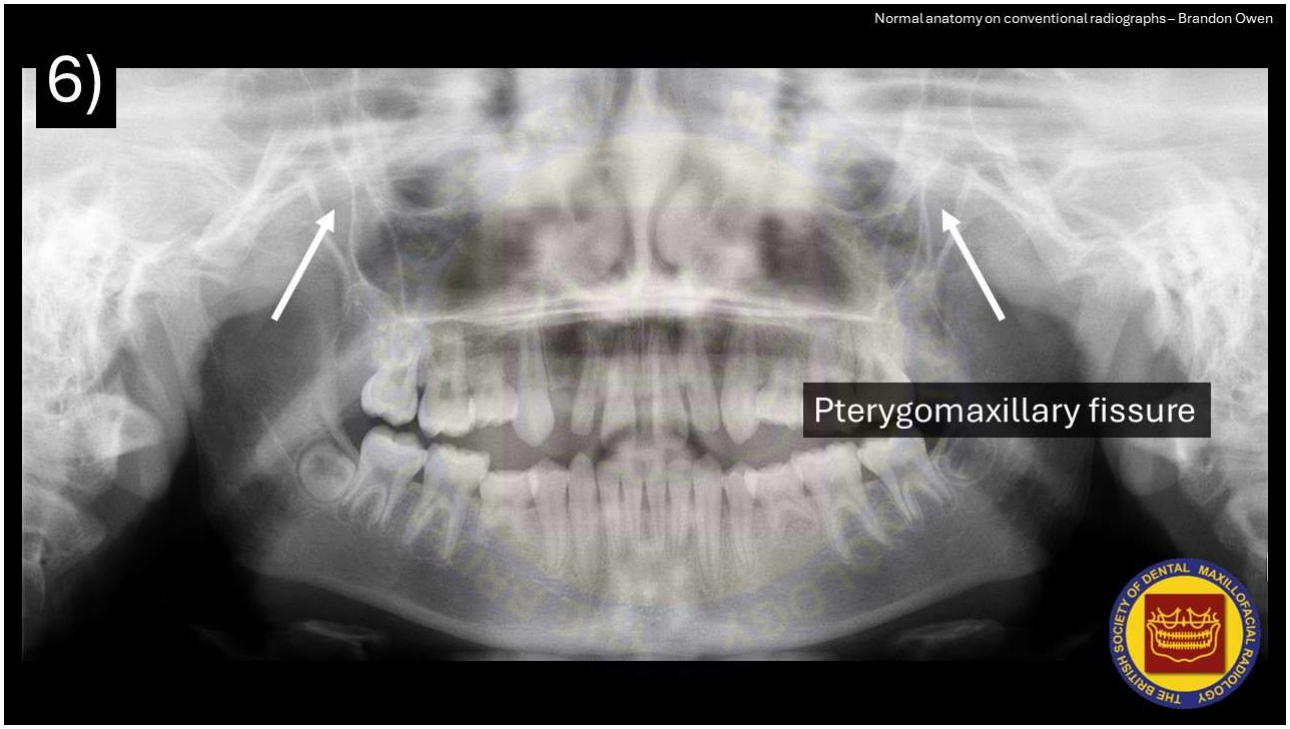
Normal anatomy on conventional radiographs– Brandon Owen
6)
Pterygomaxillary fissure

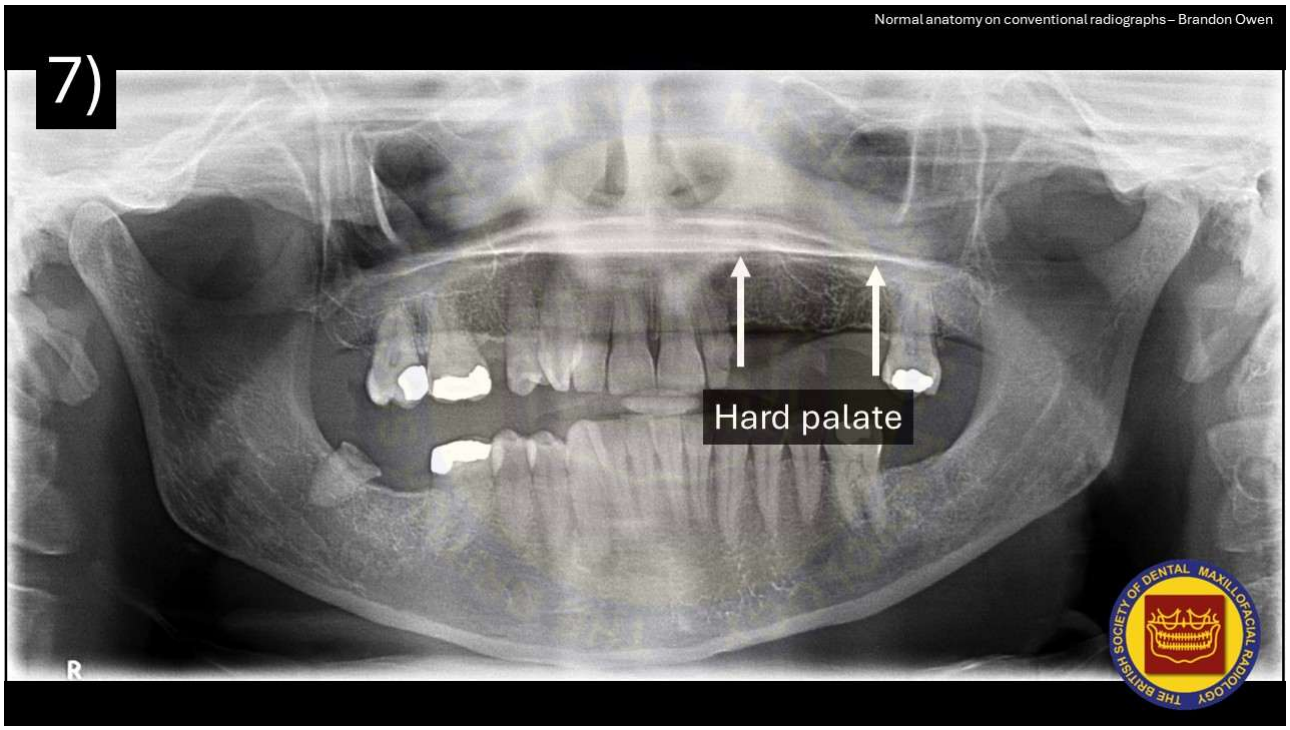
Normal anatomy on conventional radiographs – Brandon Owen
7)
Hard palate
R
THE BRITISH SOCIETY OF DENTAL MAXILLOFACIAL RADIOLOGY

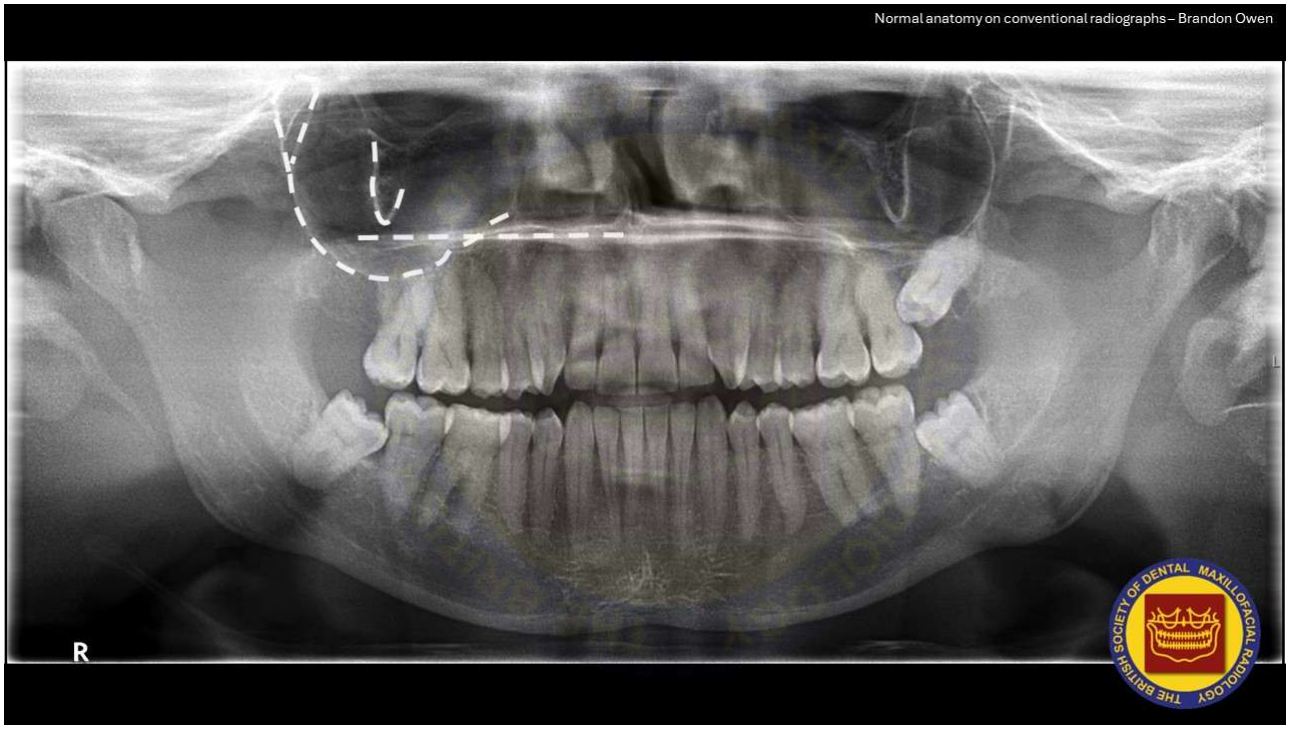
Normal anatomy on conventional radiographs – Brandon Owen
R
THE BRITISH SOCIETY OF DENTAL MAXILLOFACIAL RADIOLOGY

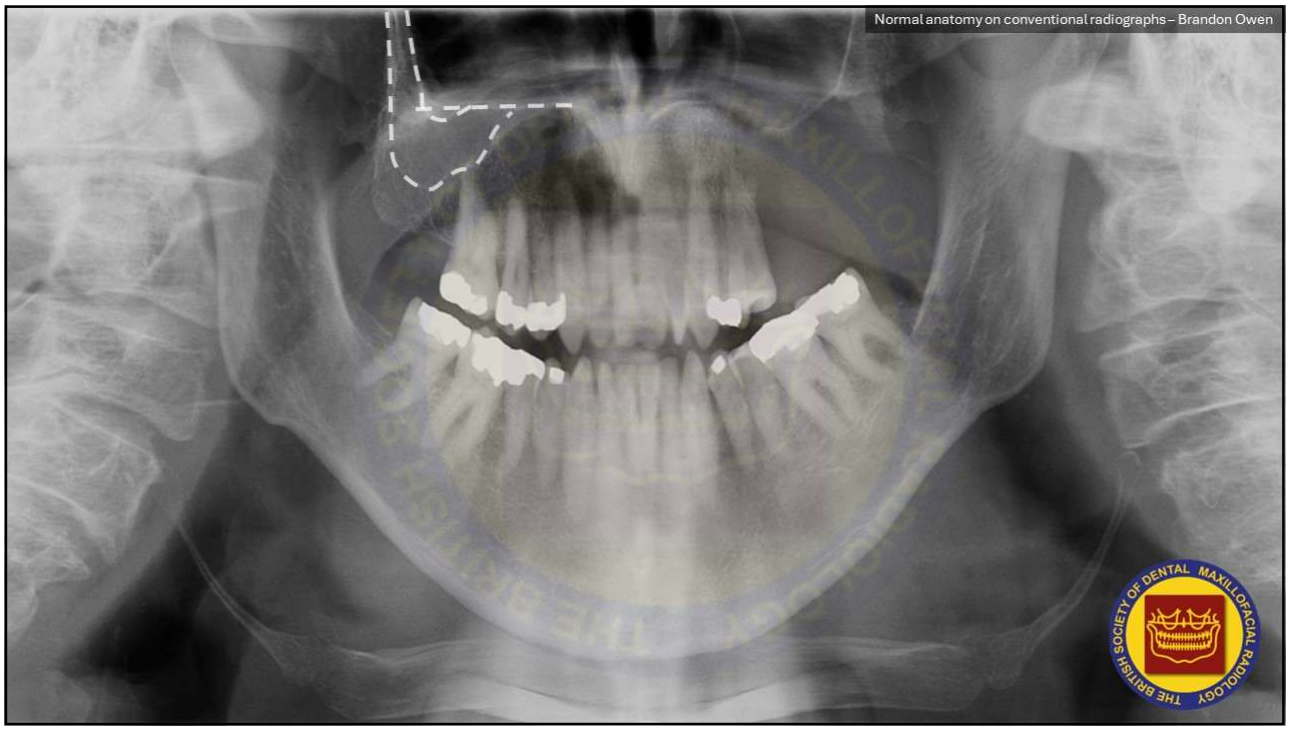
Normal anatomy on conventional radiographs– Brandon Owen
THE BRITISH SOCIETY OF DENTAL MAXILLOFACIAL RADIOLOGY

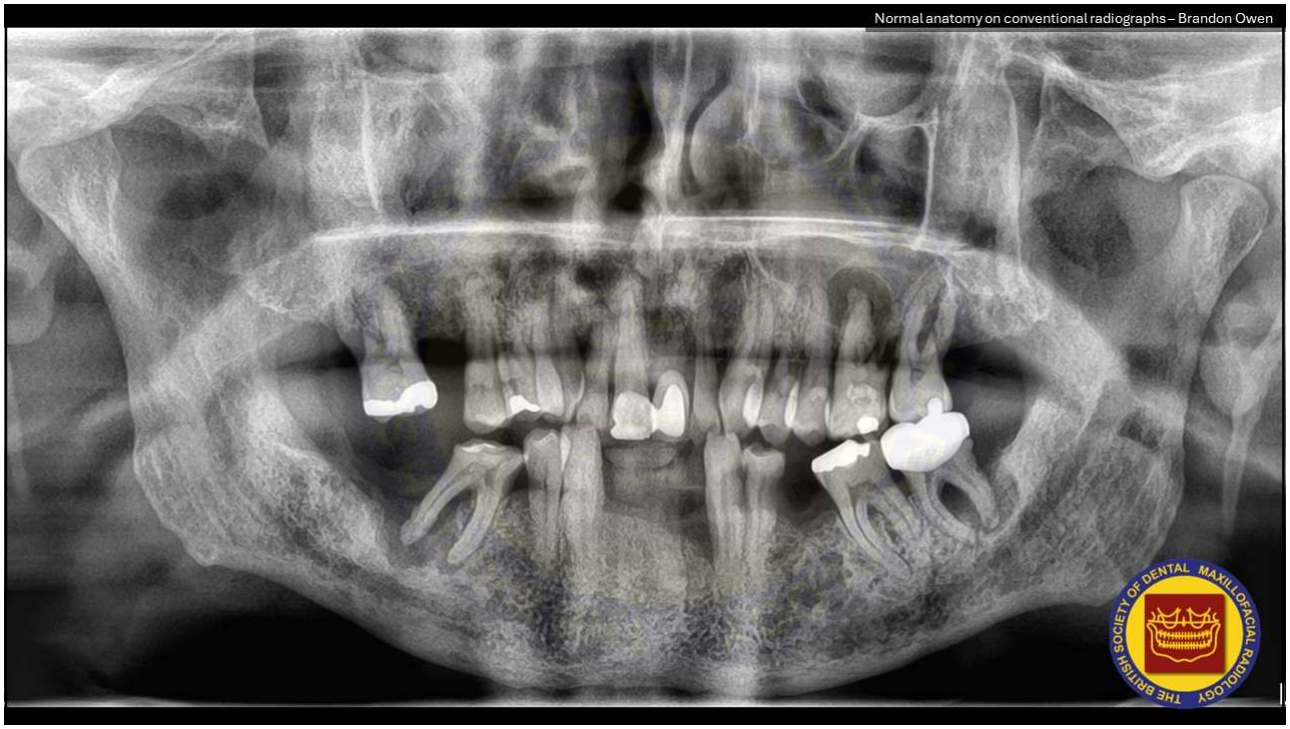
Normal anatomy on conventional radiographs– Brandon Owen
THE BRITISH SOCIETY OF DENTAL MAXILLOFACIAL RADIOLOGY

Normal anatomy on conventional radiographs – Brandon Owen

8)



Normal anatomy on conventional radiographs – Brandon Owen

9)

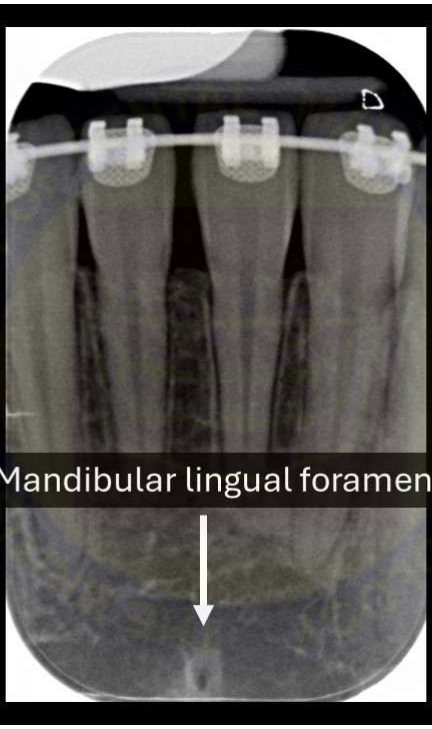

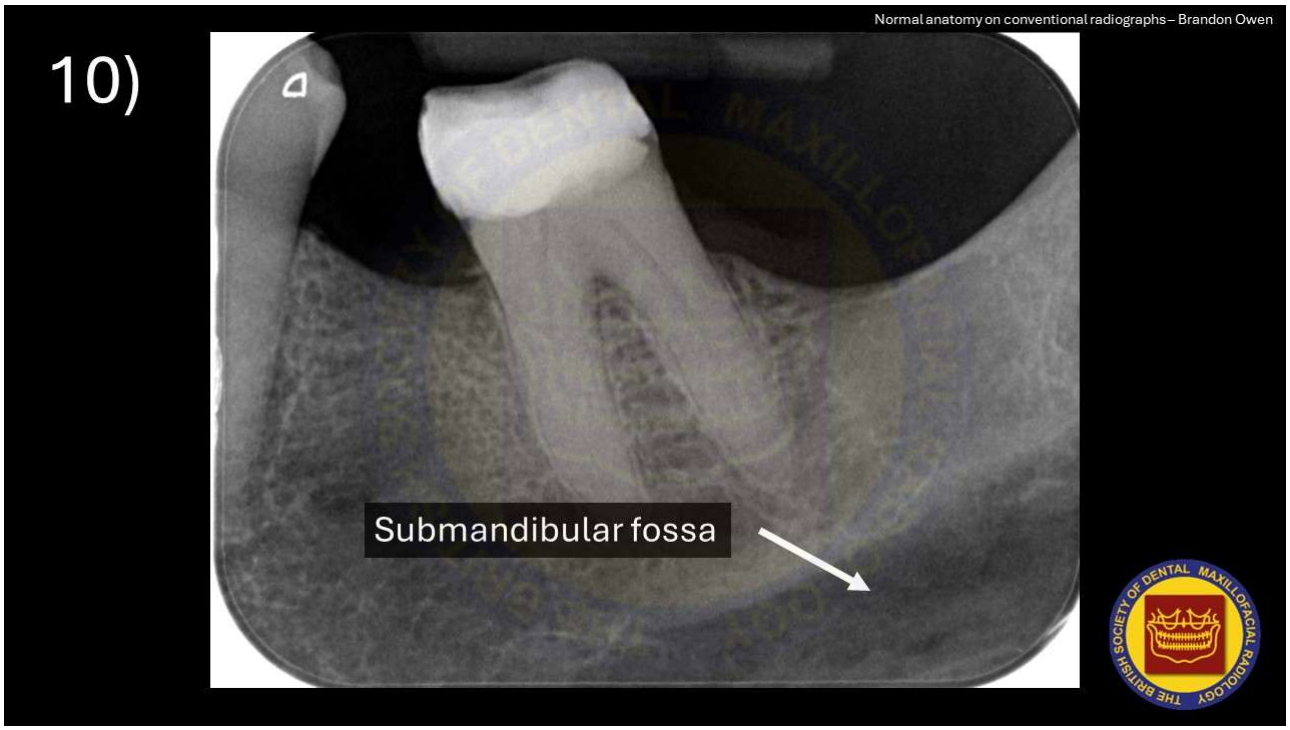
Normal anatomy on conventional radiographs – Brandon Owen
10)
Submandibular fossa

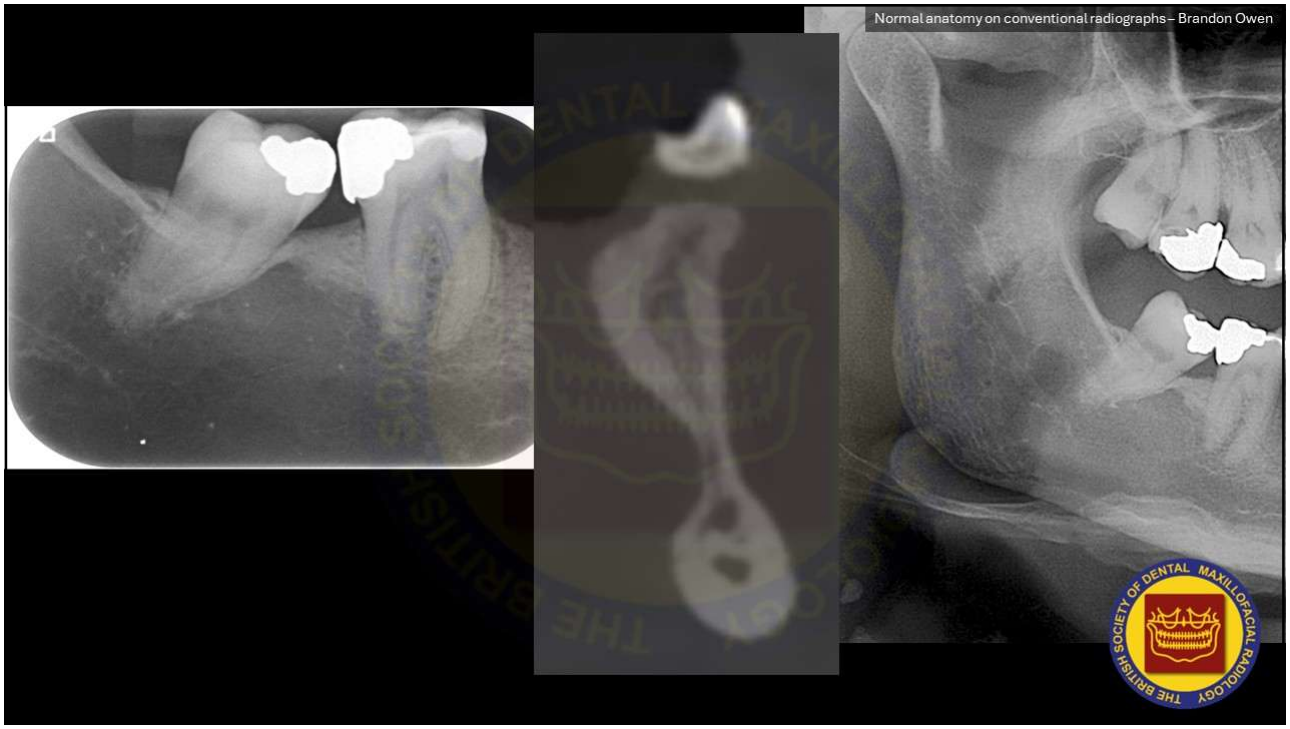
Normal anatomy on conventional radiographs – Brandon Owen

11)



Normal anatomy on conventional radiographs – Brandon Owen

Nasopalatine / Incisive foramen

Nasopalatine duct cyst



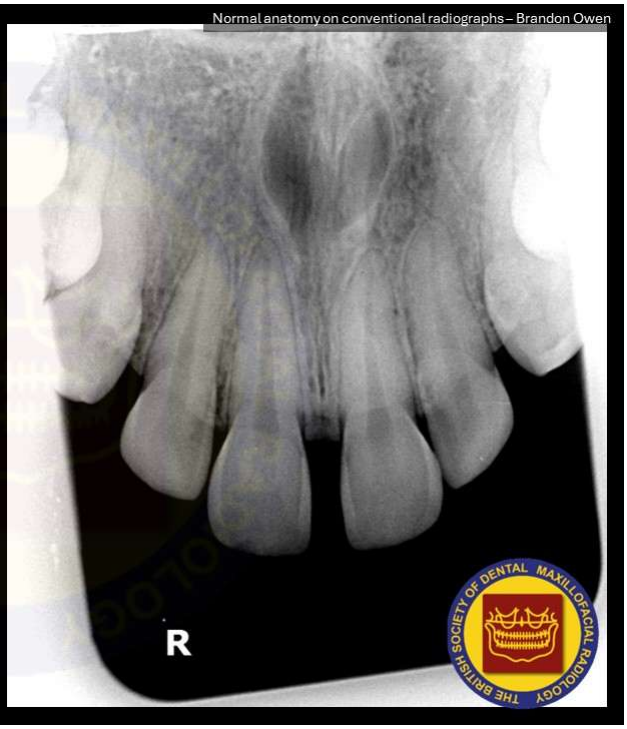

Normal anatomy on conventional radiographs – Brandon Owen

12)

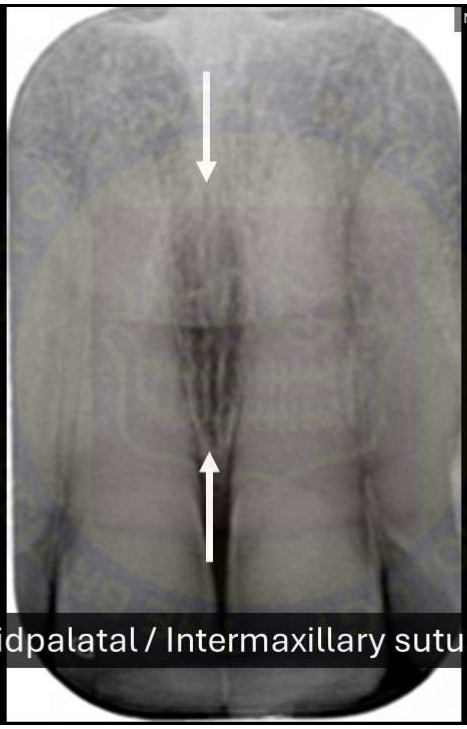
Normal anatomy on conventional radiographs – Brandon Owen
Midpalatal / Intermaxillary suture

13)

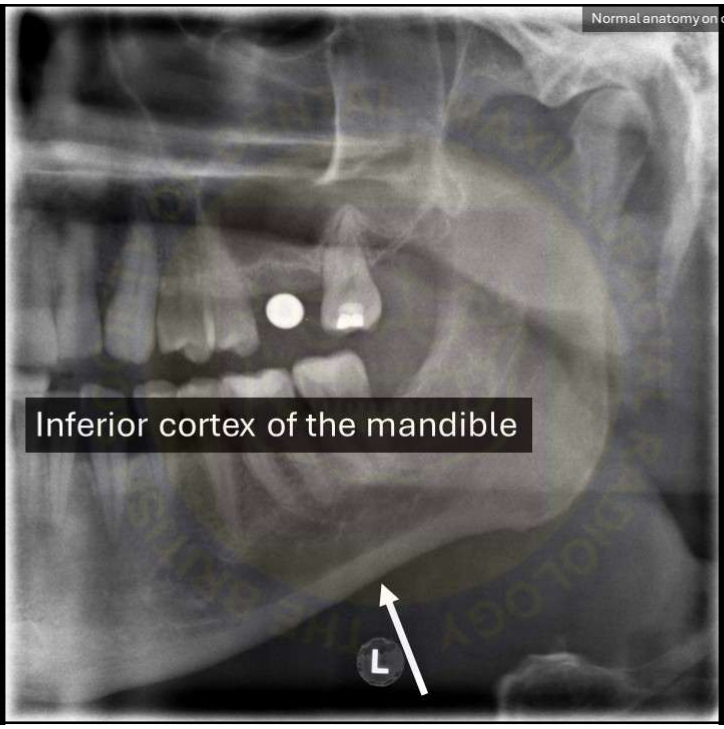
Normal anatomy on conventional radiographs – Brandon Owen
Inferior cortex of the mandible
L

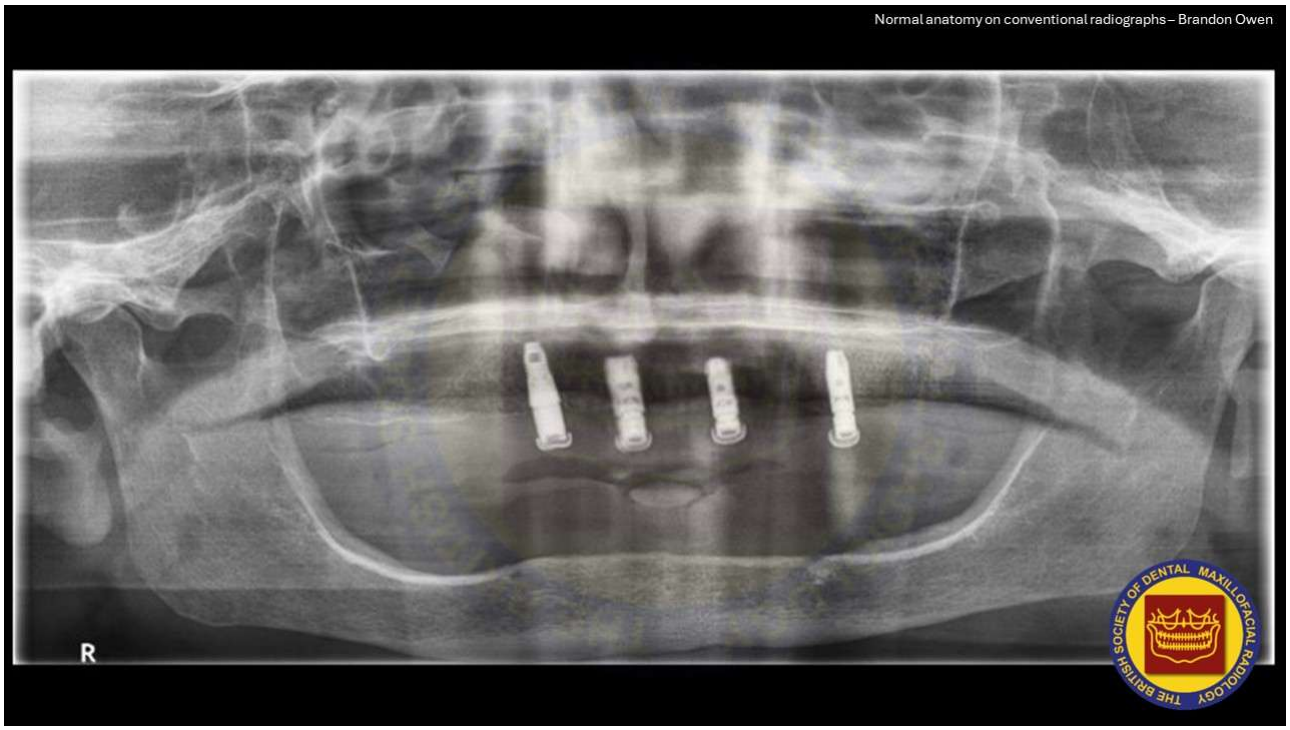
Normal anatomy on conventional radiographs – Brandon Owen
R
THE BRITISH SOCIETY OF DENTAL MAXILLOFACIAL RADIOLOGY

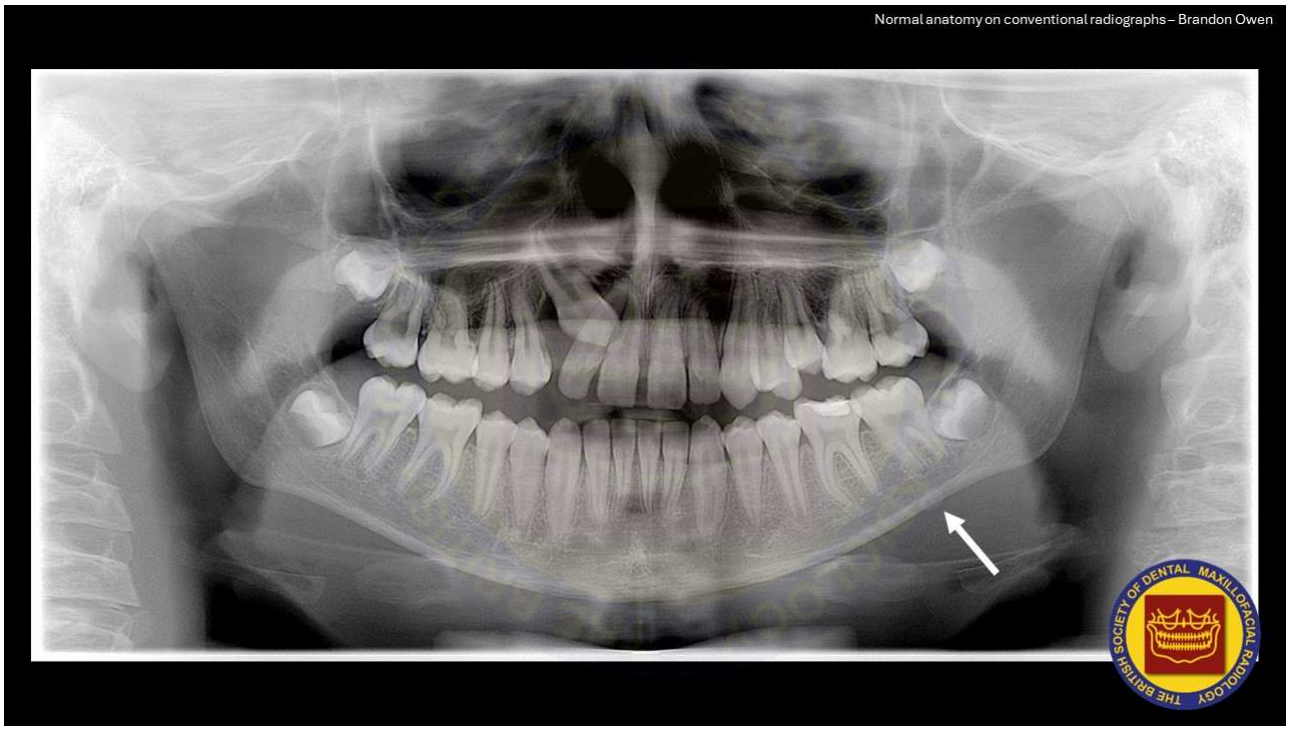
Normal anatomy on conventional radiographs – Brandon Owen
THE BRITISH SOCIETY OF DENTAL MAXILLOFACIAL RADIOLOGY

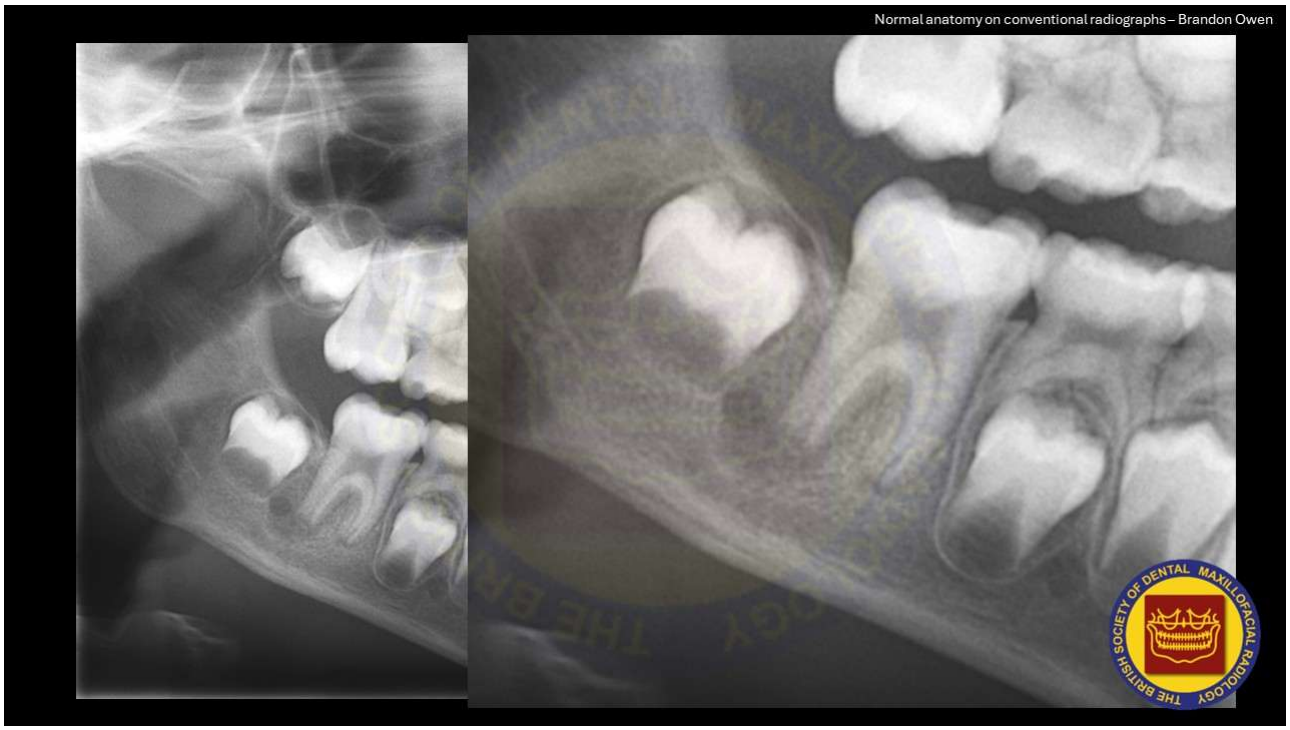
Normal anatomy on conventional radiographs – Brandon Owen

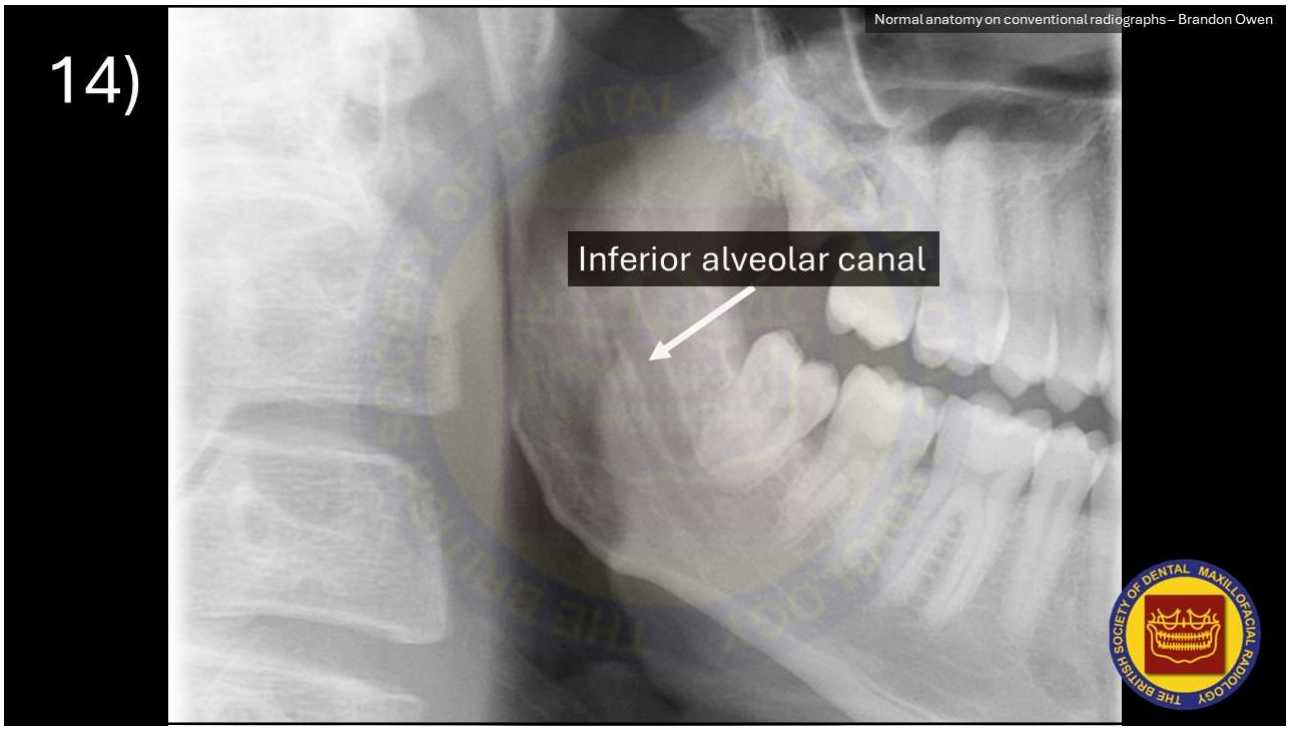
14)
Normal anatomy on conventional radiographs – Brandon Owen
Inferior alveolar canal

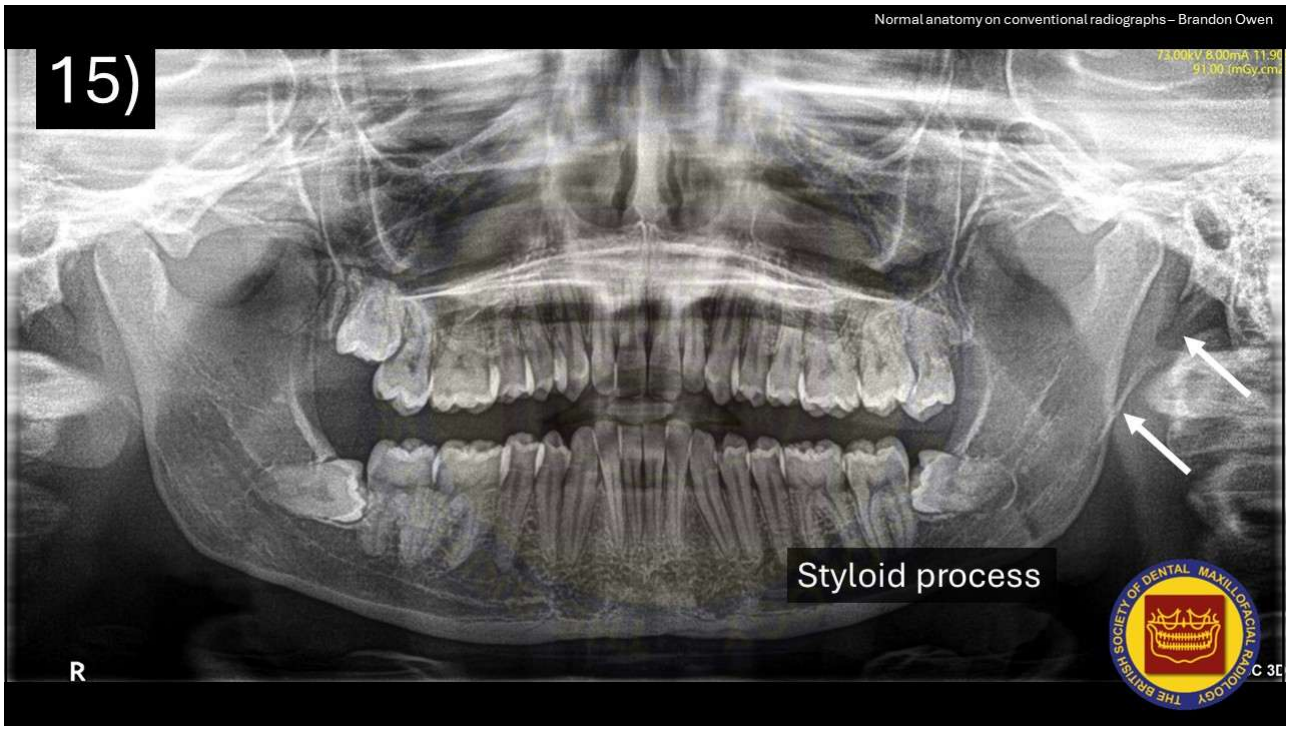
Normal anatomy on conventional radiographs – Brandon Owen
15)
Styloid process
R

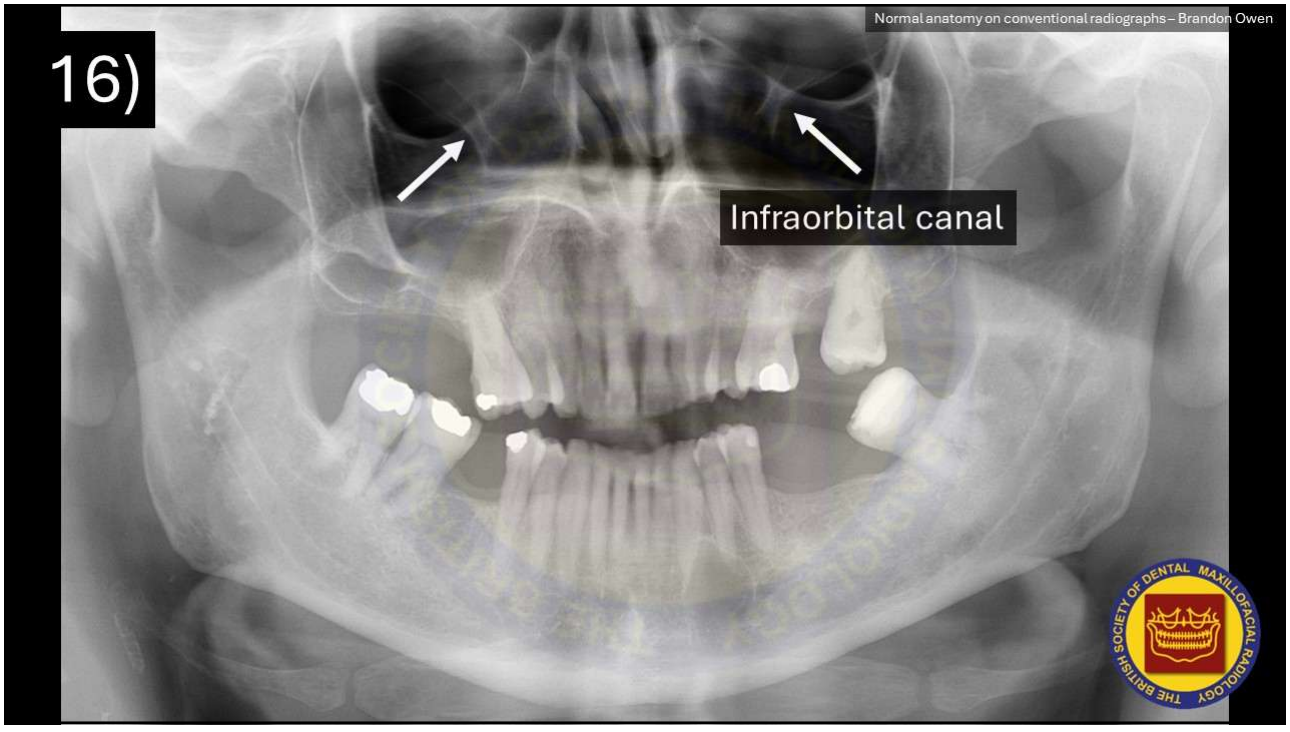
Normal anatomy on conventional radiographs – Brandon Owen
16)
Infraorbital canal

17)

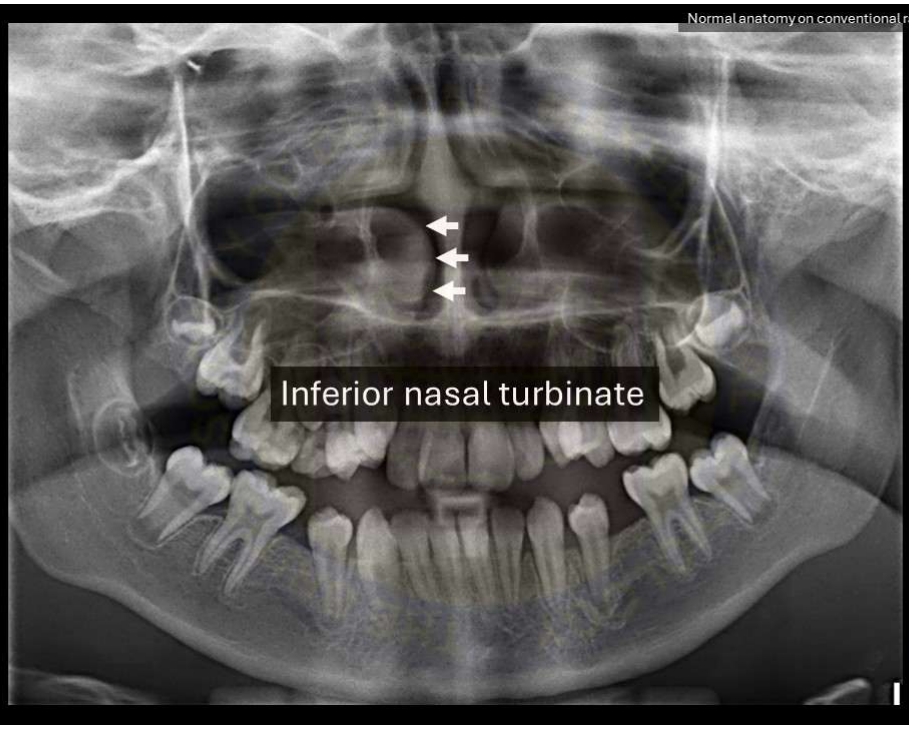
Normal anatomy on conventional radiographs – Brandon Owen
Inferior nasal turbinate

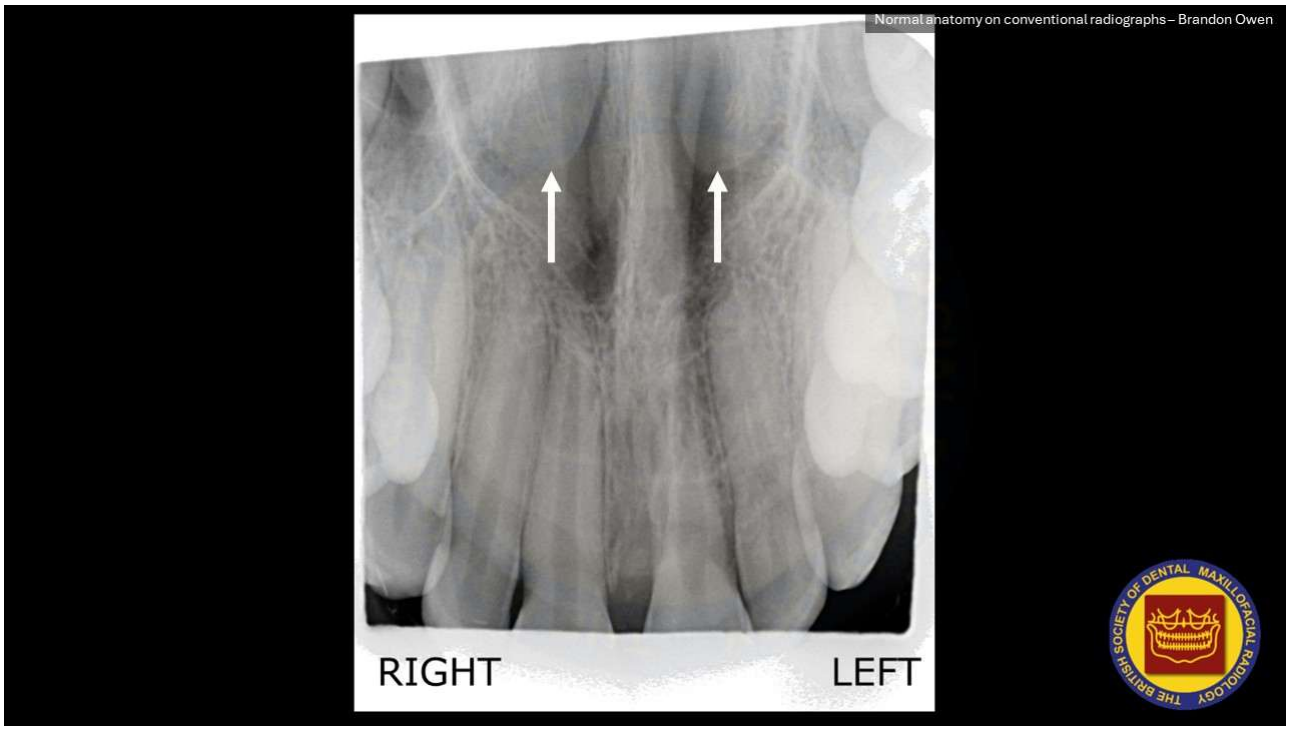
Normal anatomy on conventional radiographs – Brandon Owen
RIGHT
LEFT


Normal anatomy on conventional radiographs – Brandon Owen
THE BRITISH SOCIETY OF DENTAL MAXILLOFACIAL RADIOLOGY


Normal anatomy on conventional radiographs – Brandon Owen
"Second opinion please. Is there a cyst within the left maxillary antrum?"
THE BRITISH SOCIETY OF DENTAL MAXILLOFACIAL RADIOLOGY

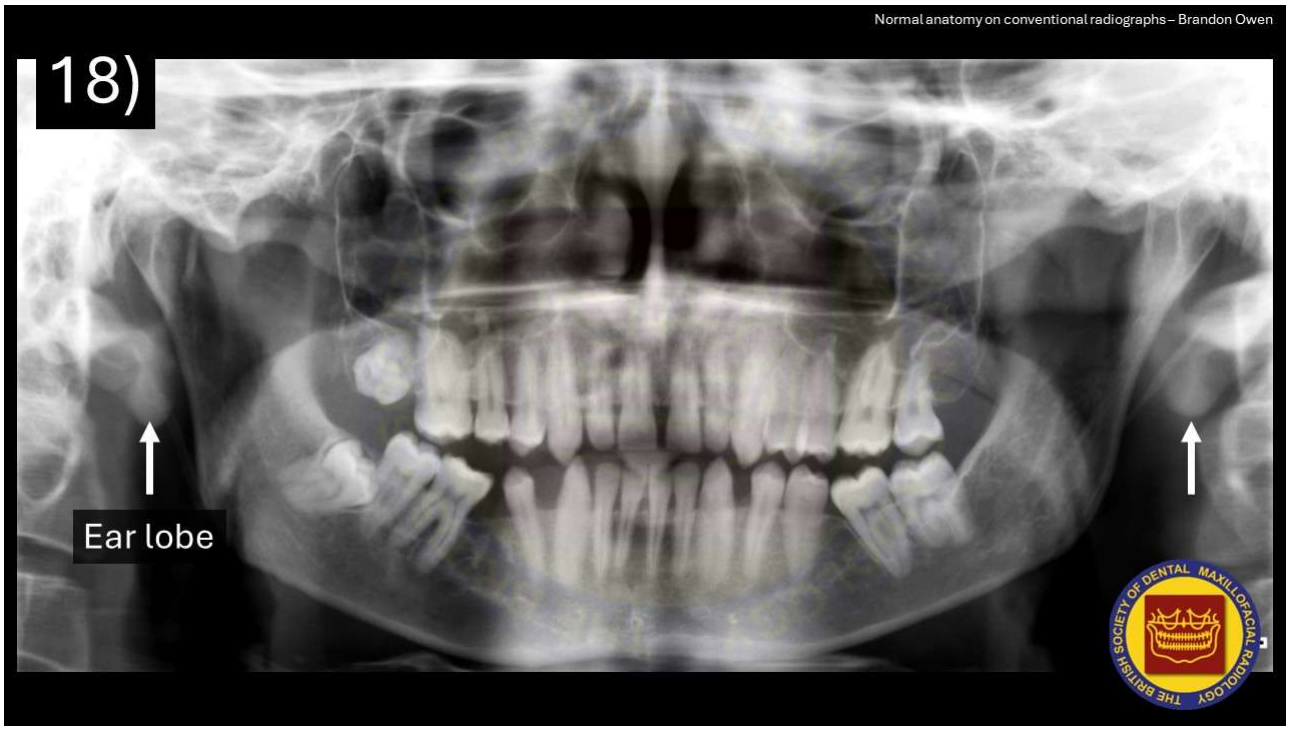
Normal anatomy on conventional radiographs – Brandon Owen
18)
Ear lobe
THE BRITISH SOCIETY OF DENTAL MAXILLOFACIAL RADIOLOGY

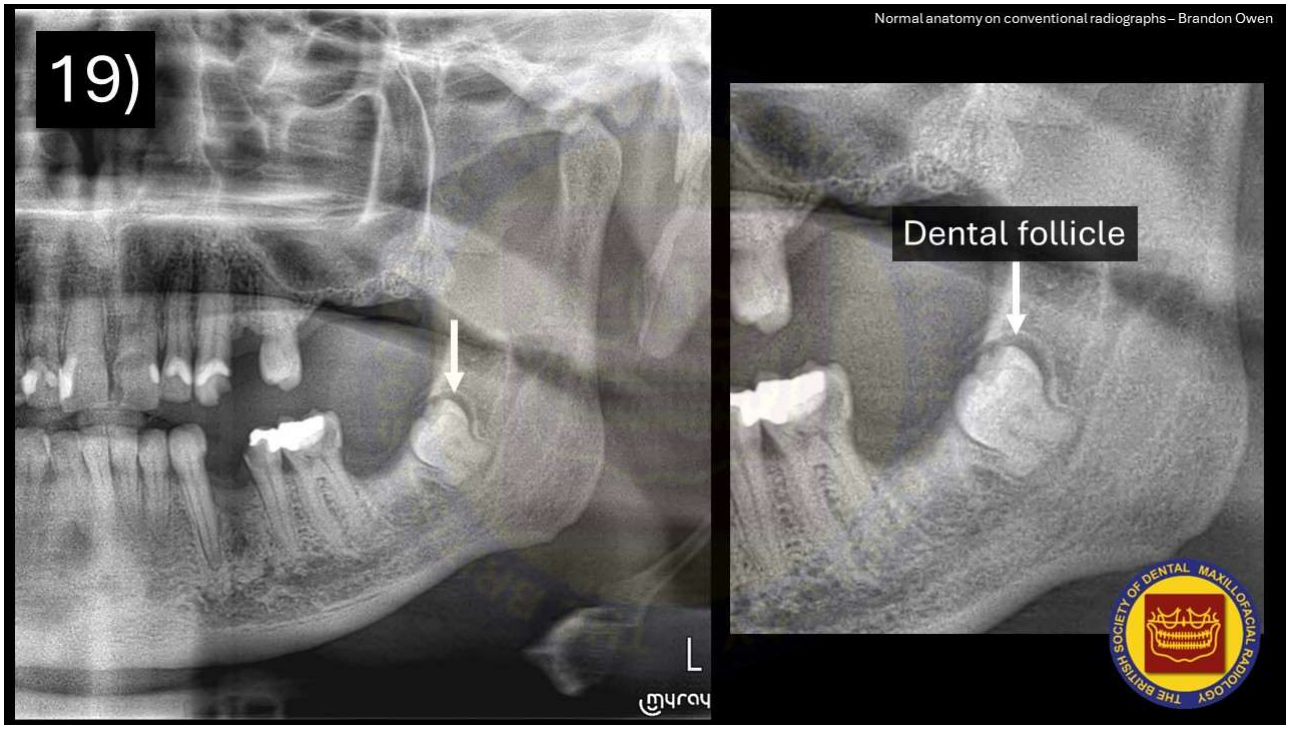
Normal anatomy on conventional radiographs – Brandon Owen
19)
L
myray
Dental follicle
THE BRITISH SOCIETY OF DENTAL MAXILLOFACIAL RADIOLOGY

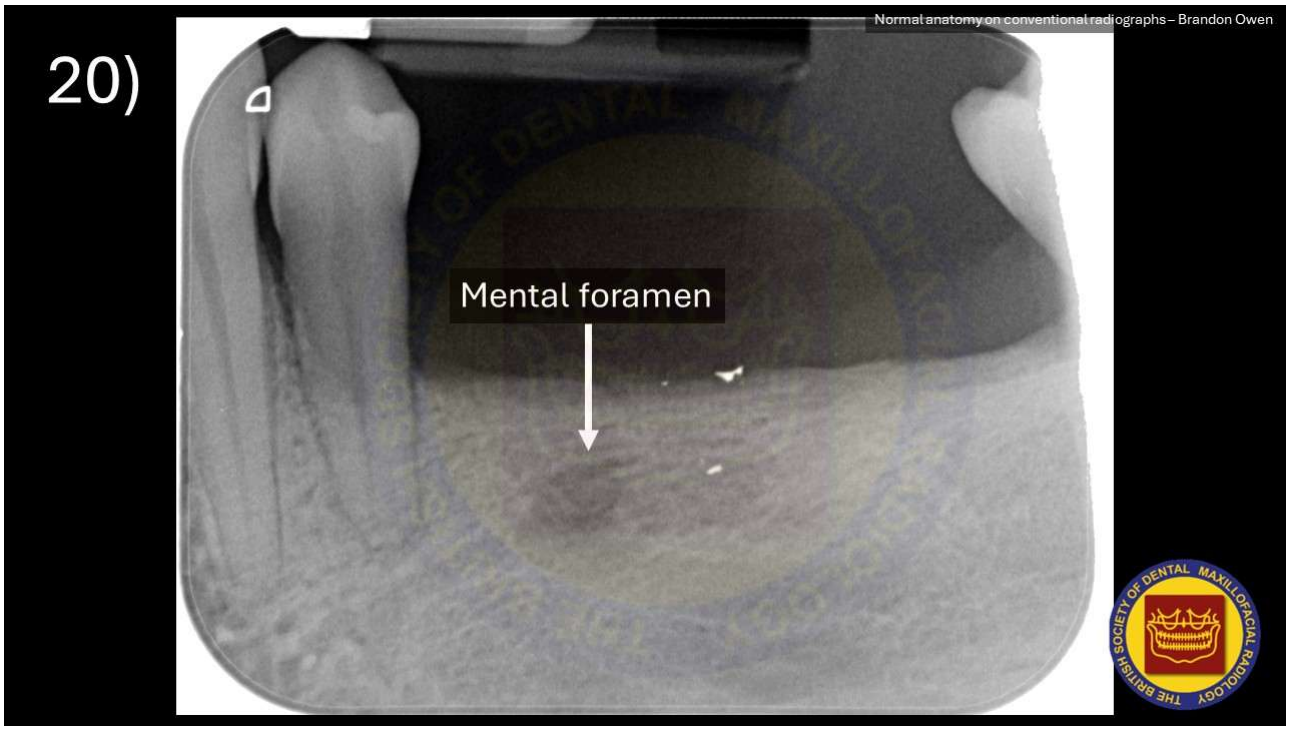
20)
Normal anatomy on conventional radiographs – Brandon Owen
Mental foramen

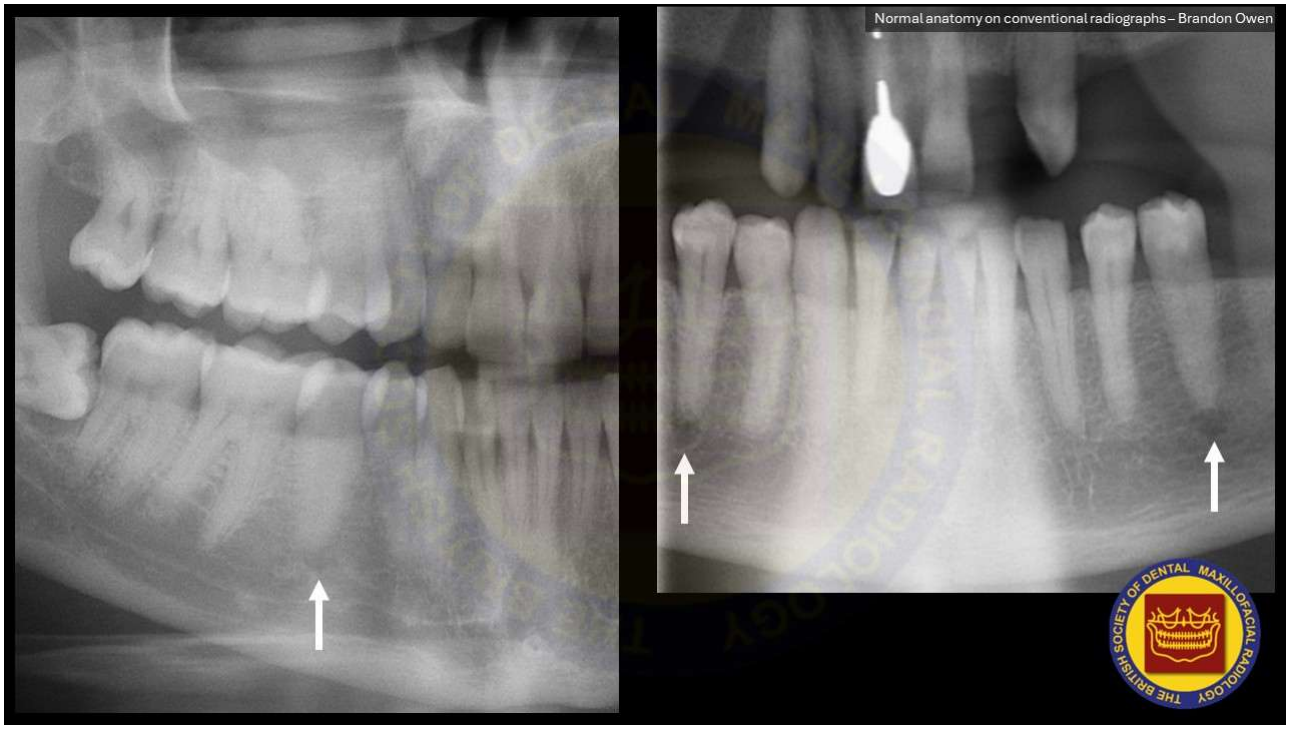
Normal anatomy on conventional radiographs – Brandon Owen

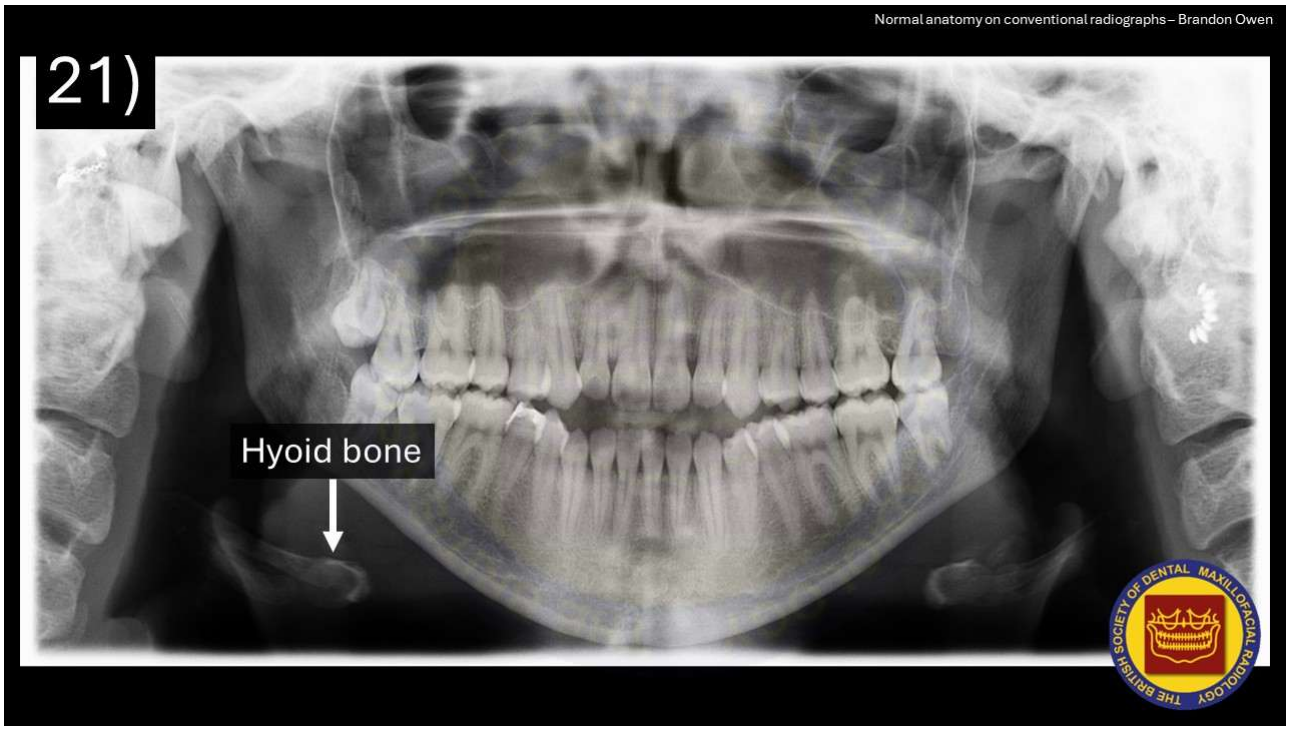
Normal anatomy on conventional radiographs – Brandon Owen
21)
Hyoid bone
THE BRITISH SOCIETY OF DENTAL MAXILLOFACIAL RADIOLOGY


Normal anatomy on conventional radiographs – Brandon Owen
THE BRITISH SOCIETY OF DENTAL MAXILLOFACIAL RADIOLOGY

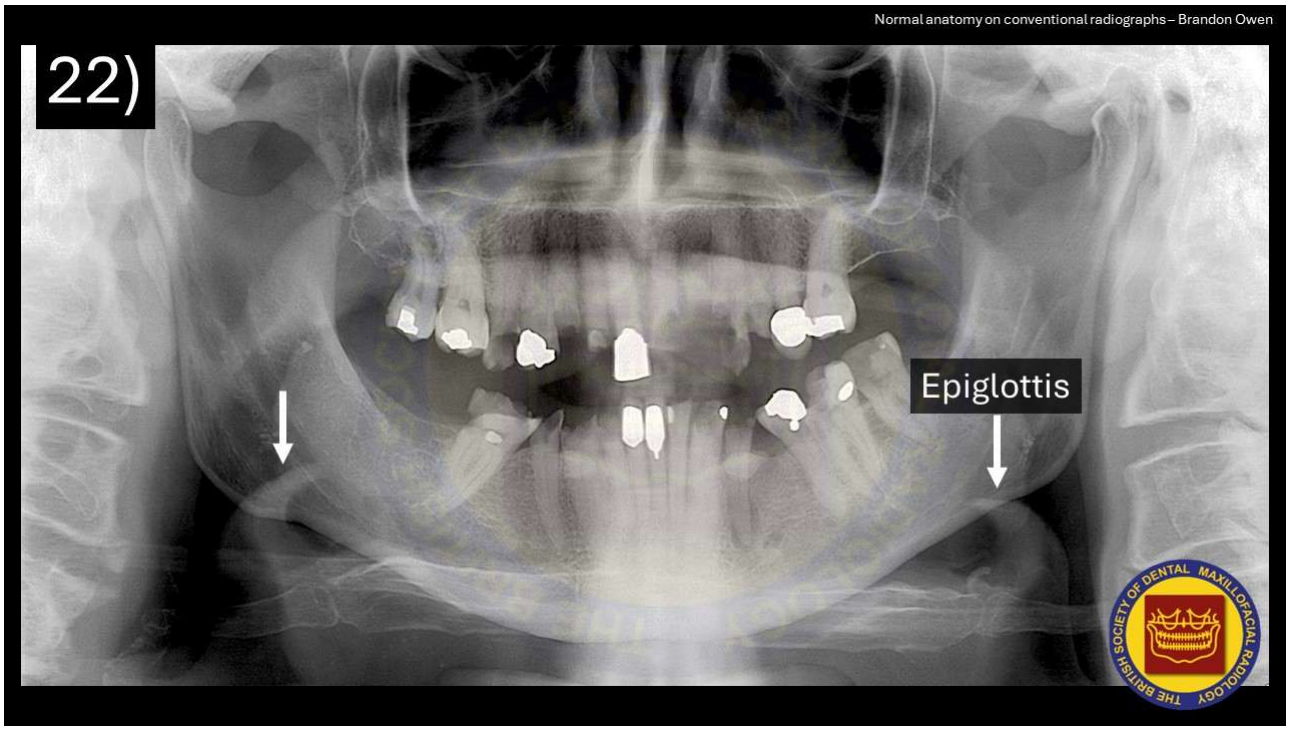
Normal anatomy on conventional radiographs – Brandon Owen
22)
Epiglottis
THE BRITISH SOCIETY OF DENTAL MAXILLOFACIAL RADIOLOGY


Normal anatomy on conventional radiographs – Brandon Owen
THE BRITISH SOCIETY OF DENTAL MAXILLOFACIAL RADIOLOGY

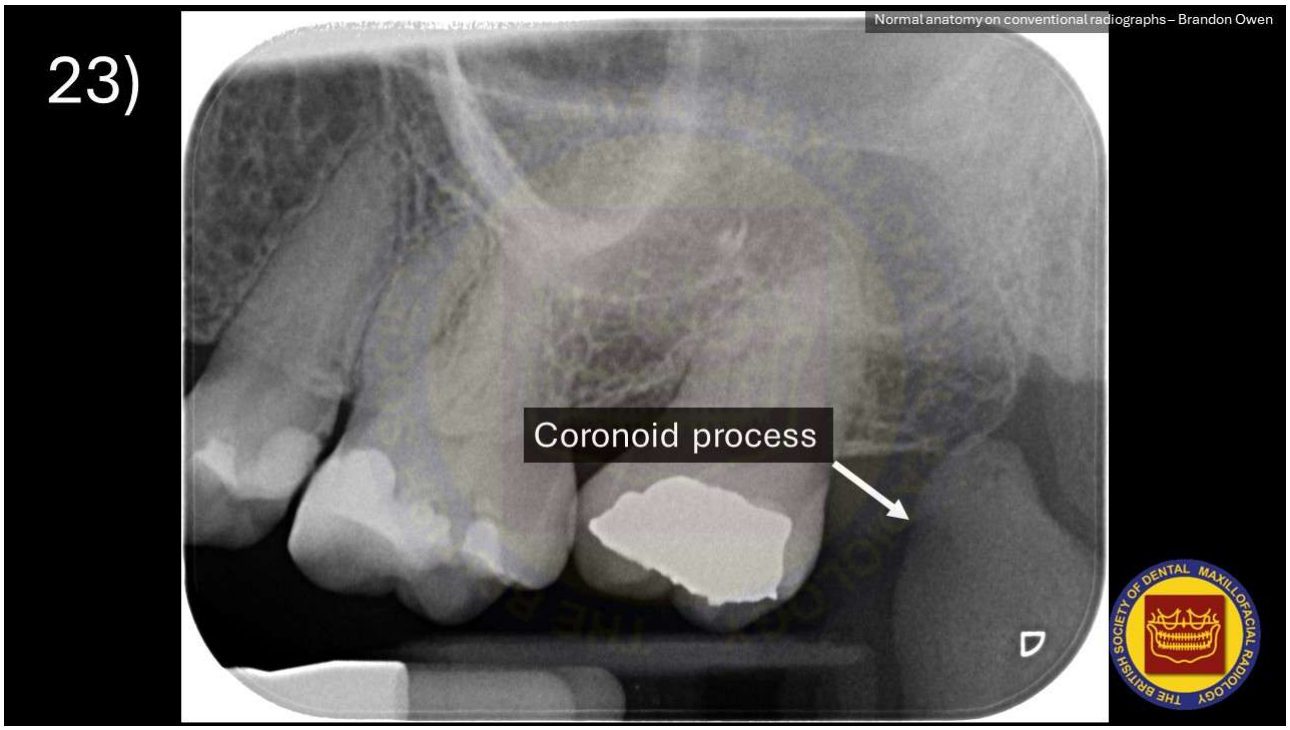
23)
Normal anatomy on conventional radiographs – Brandon Owen
Coronoid process

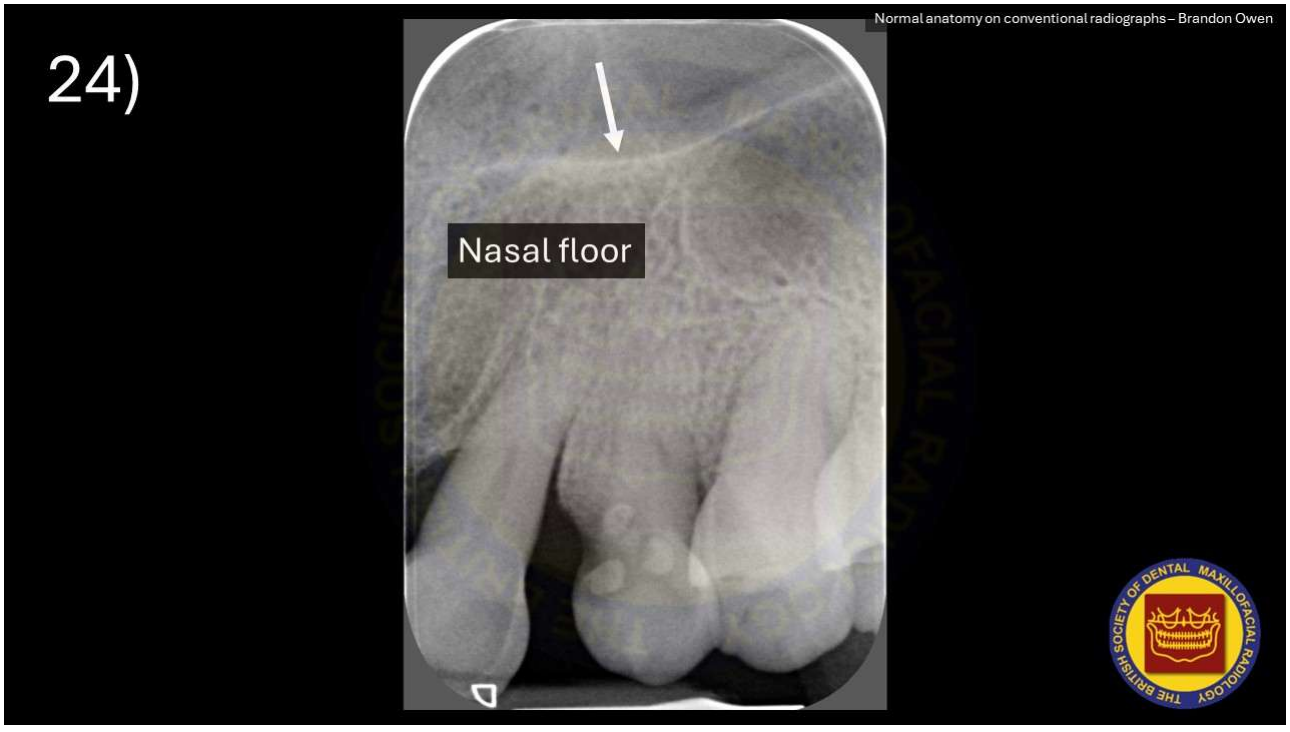
24)
Normal anatomy on conventional radiographs – Brandon Owen
Nasal floor

25)

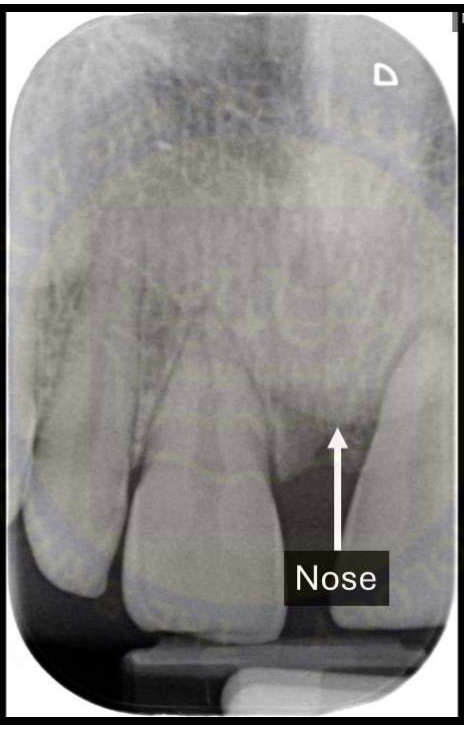

Normal anatomy on conventional radiographs – Brandon Owen

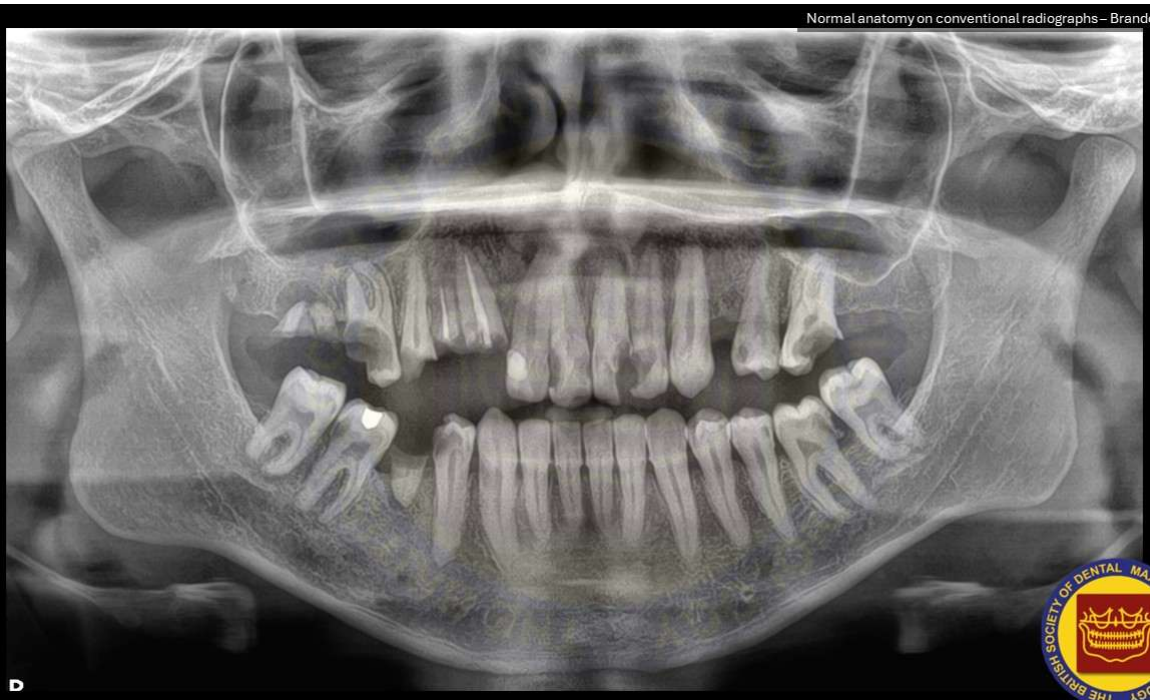

Normal anatomy on conventional radiographs – Brandon Owen

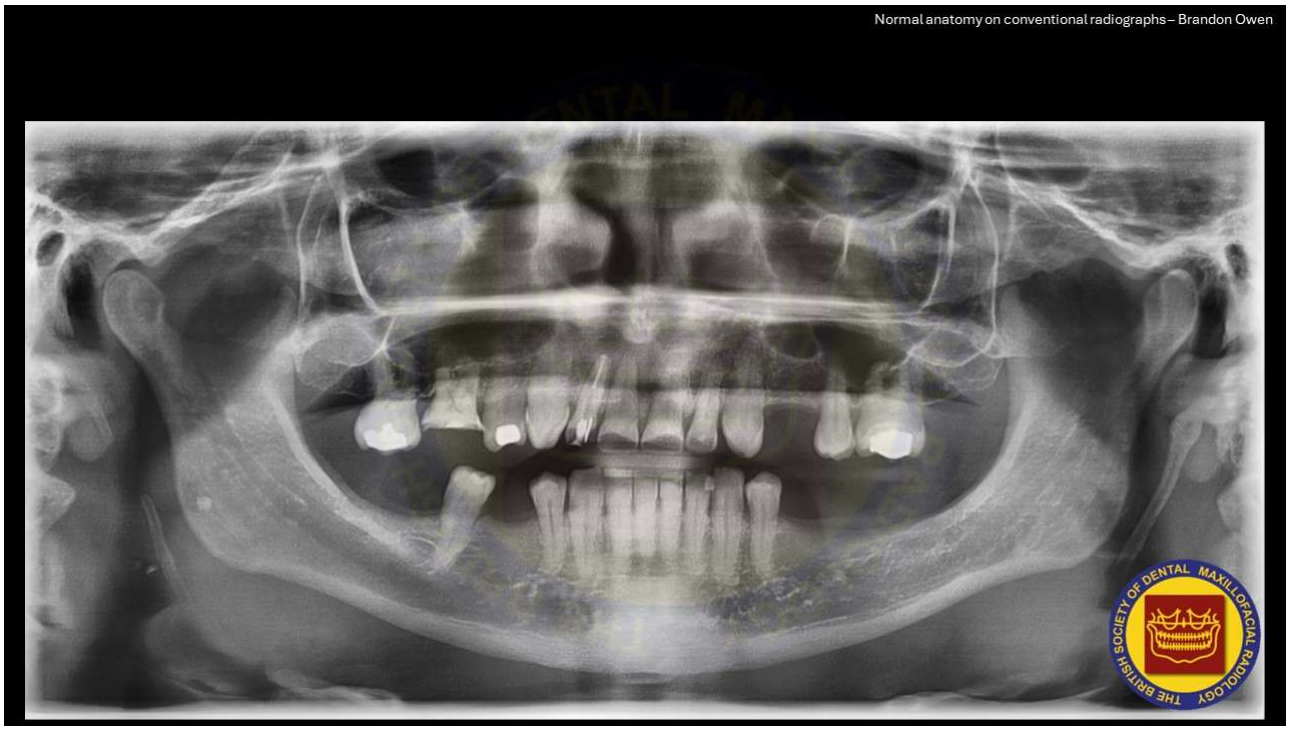
Normal anatomy on conventional radiographs – Brandon Owen
THE BRITISH SOCIETY OF DENTAL MAXILLOFACIAL RADIOLOGY

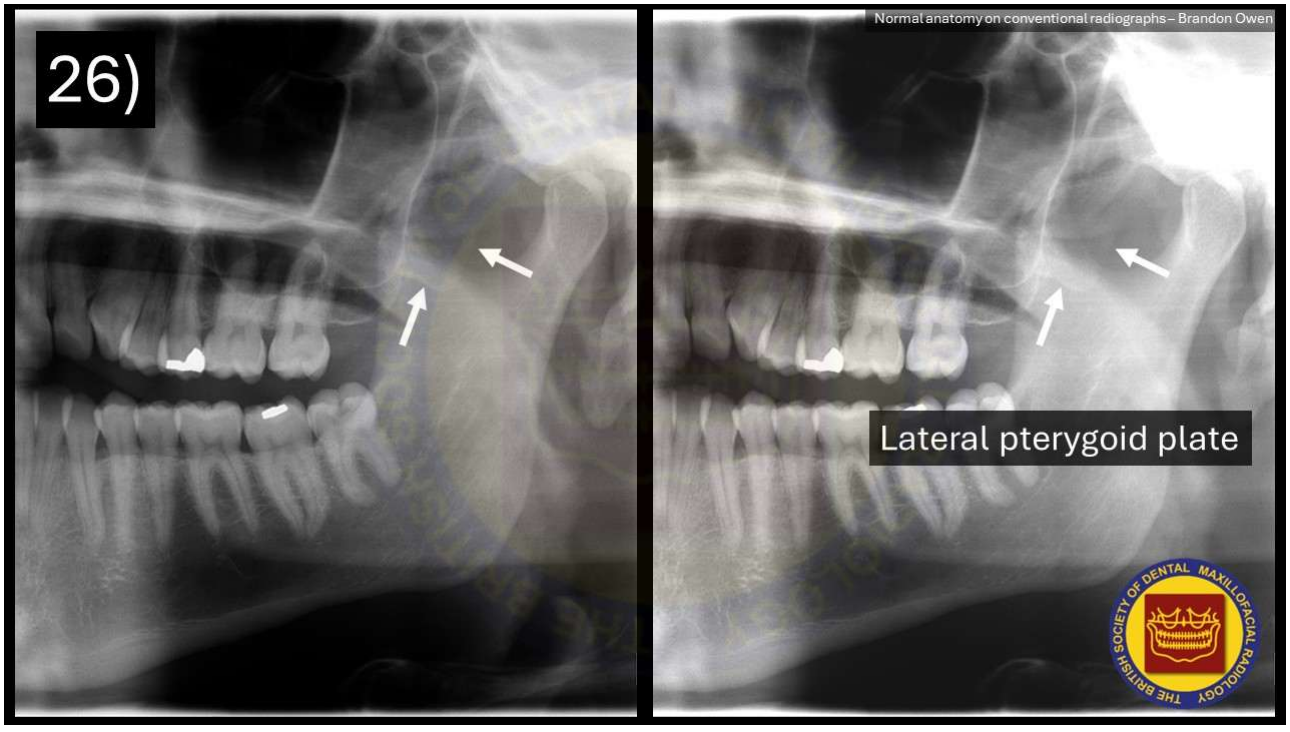
26)
Normal anatomy on conventional radiographs – Brandon Owen
Lateral pterygoid plate
THE BRITISH SOCIETY OF DENTAL MAXILLOFACIAL RADIOLOGY

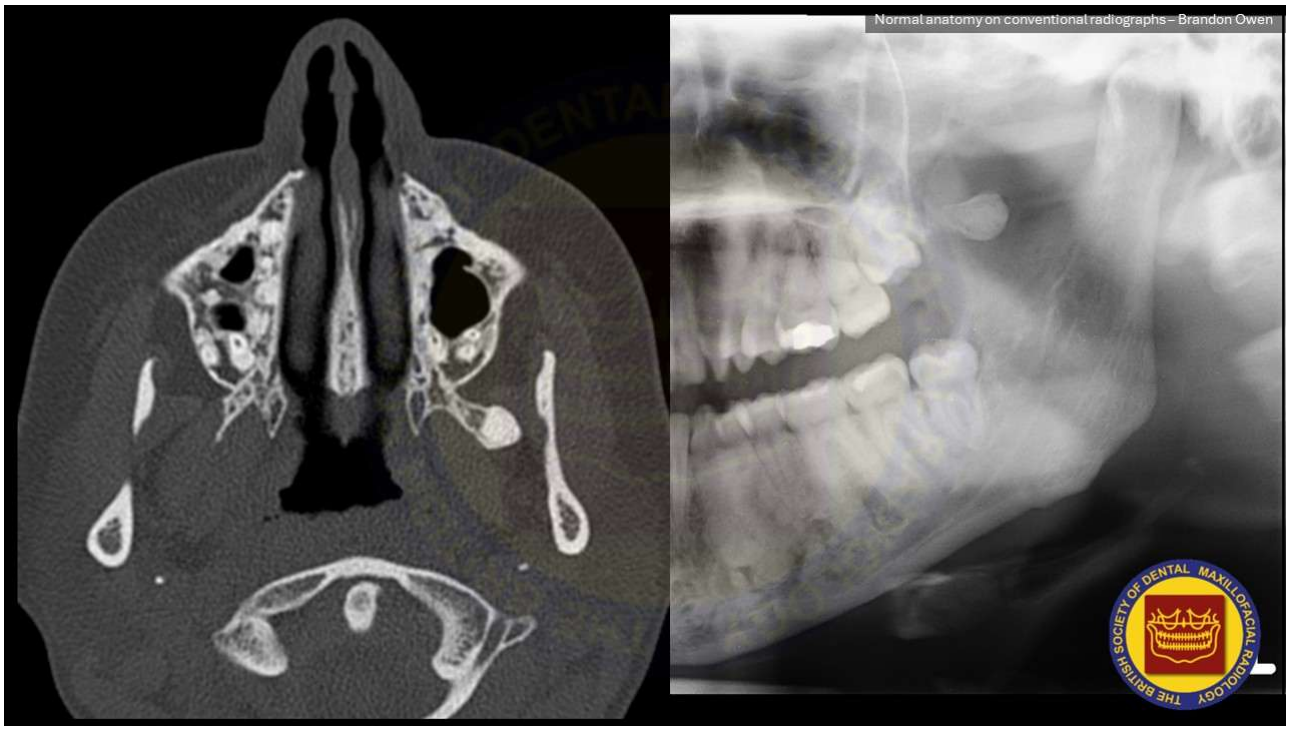
Normal anatomy on conventional radiographs – Brandon Owen
L

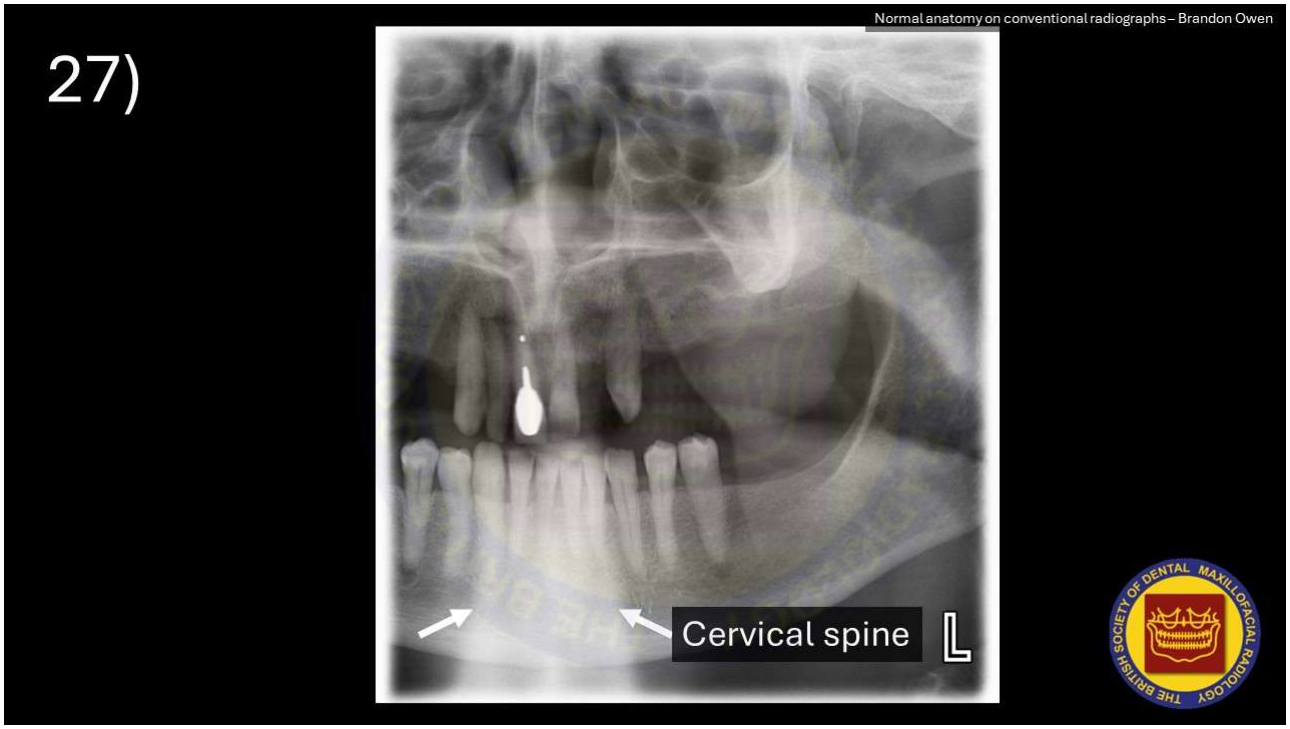
Normal anatomy on conventional radiographs – Brandon Owen
27)
Cervical spine
L

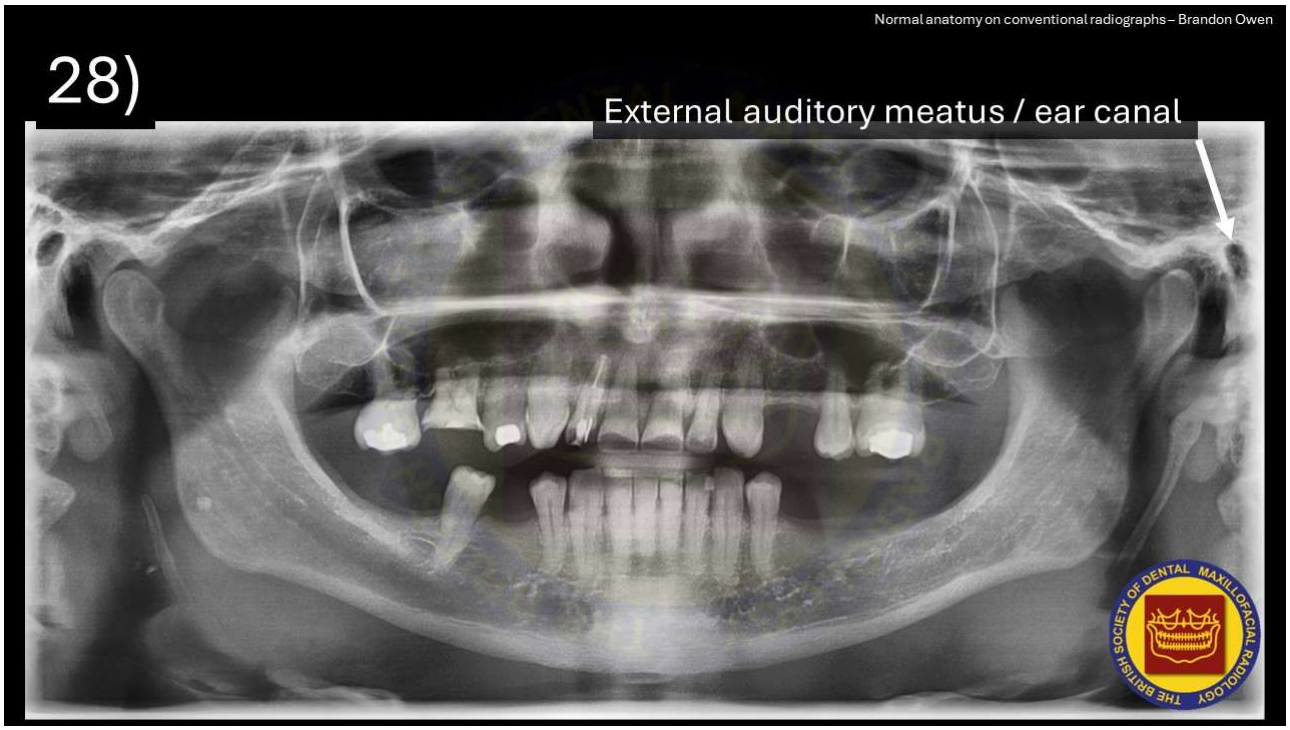
Normal anatomy on conventional radiographs – Brandon Owen
28)
External auditory meatus / ear canal
THE BRITISH SOCIETY OF DENTAL MAXILLOFACIAL RADIOLOGY

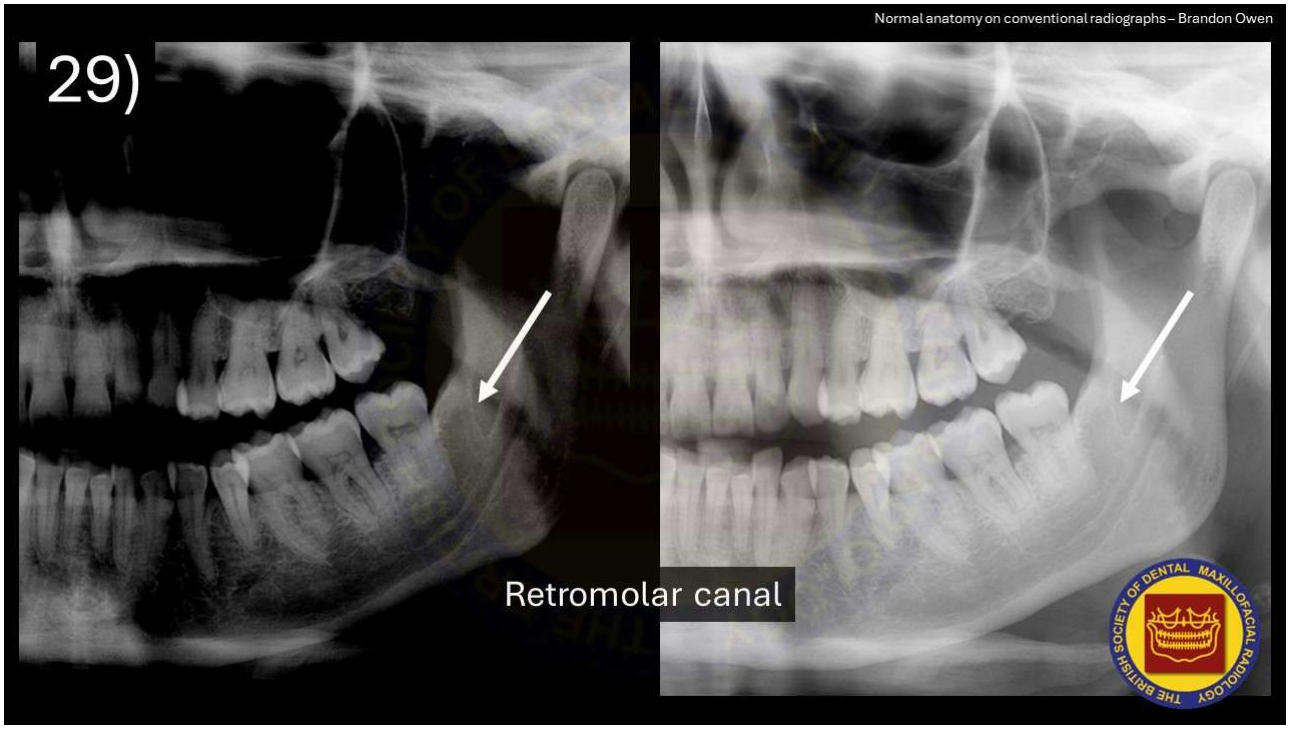
Normal anatomy on conventional radiographs – Brandon Owen
29)
Retromolar canal
THE BRITISH SOCIETY OF DENTAL MAXILLOFACIAL RADIOLOGY

30)

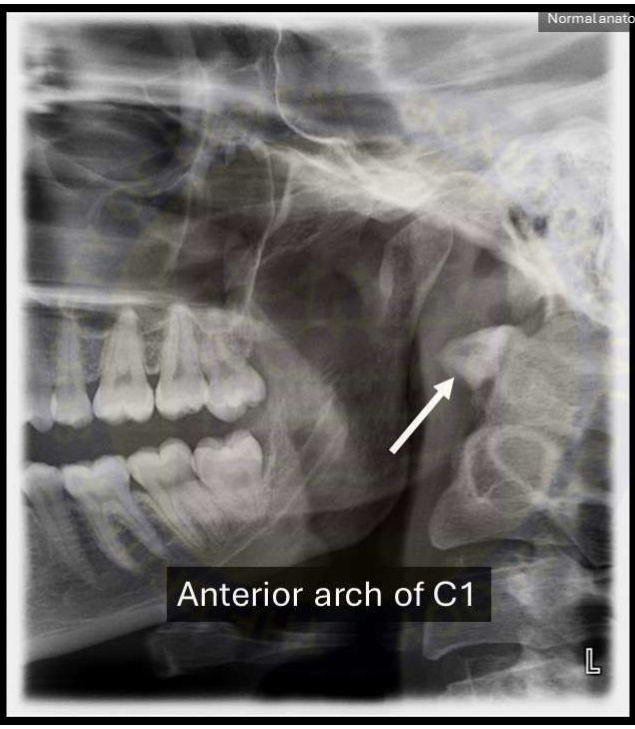
Normal anatomy on conventional radiographs – Brandon Owen
Anterior arch of C1
L

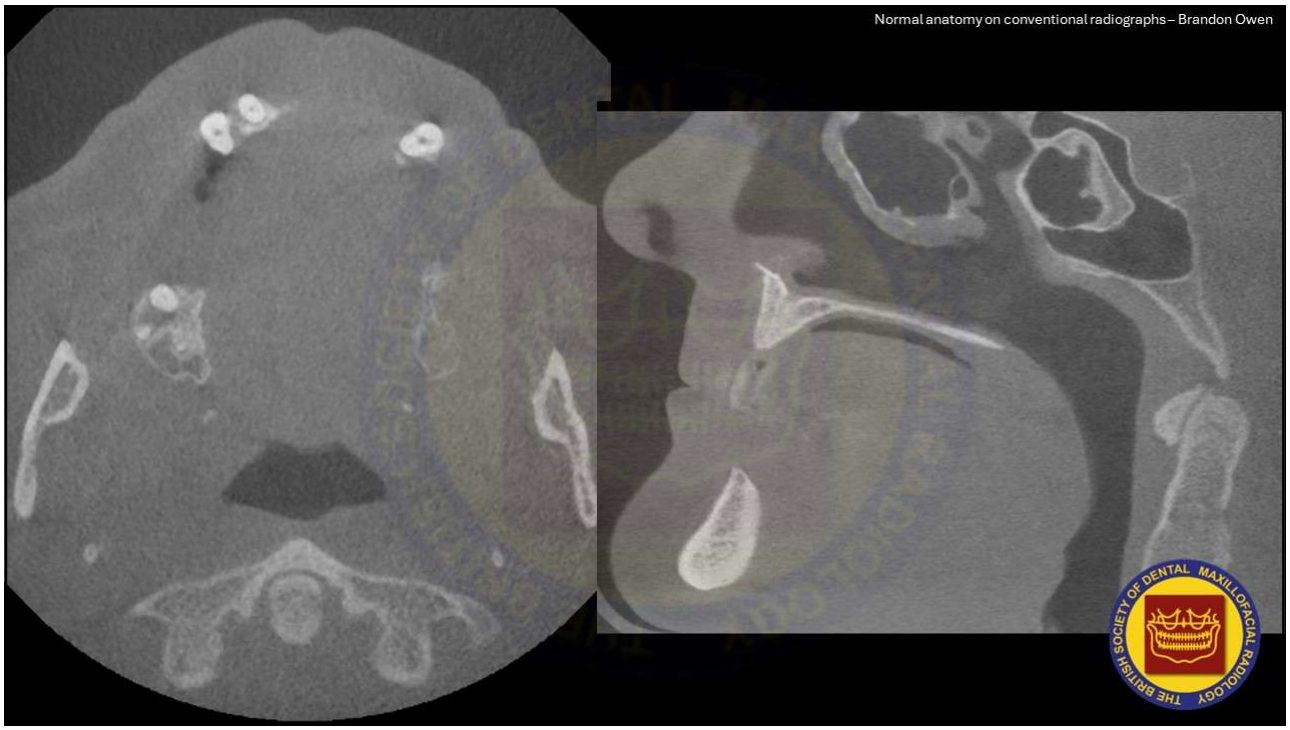
Normal anatomy on conventional radiographs – Brandon Owen

31)

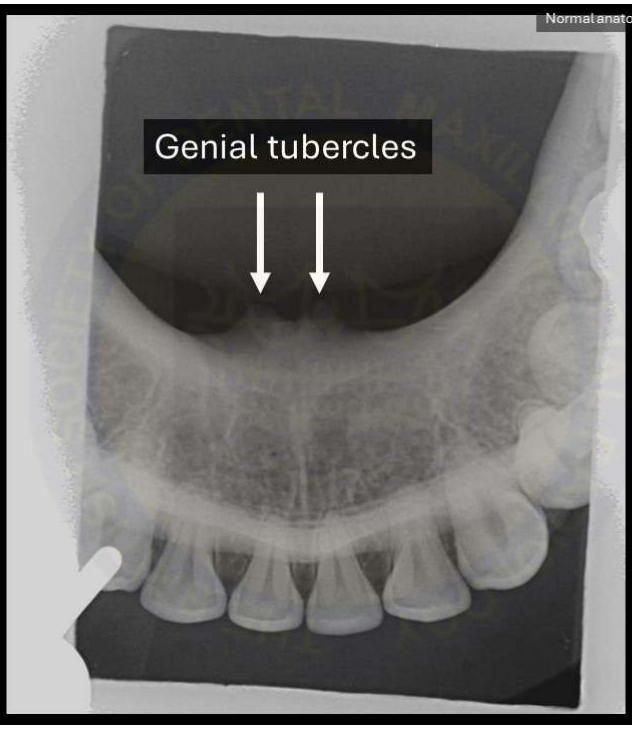
Normal anatomy on conventional radiographs – Brandon Owen
Genial tubercles

32)

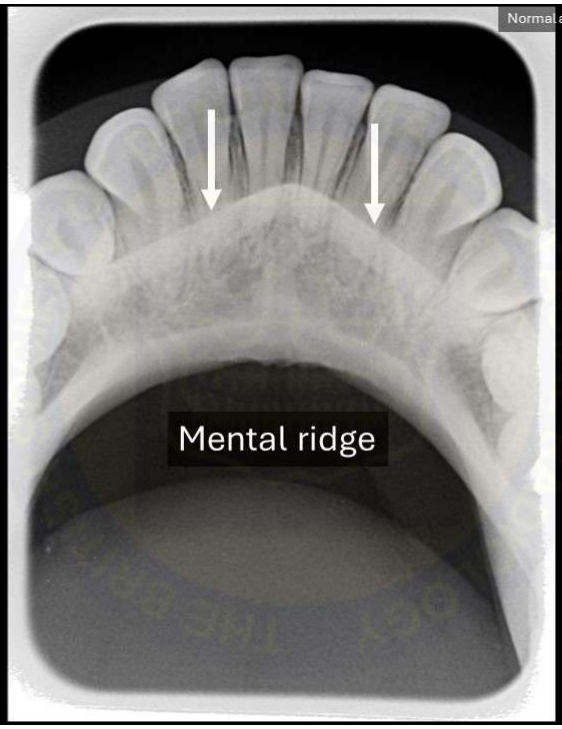
Normal anatomy on conventional radiographs – Brandon Owen
Mental ridge

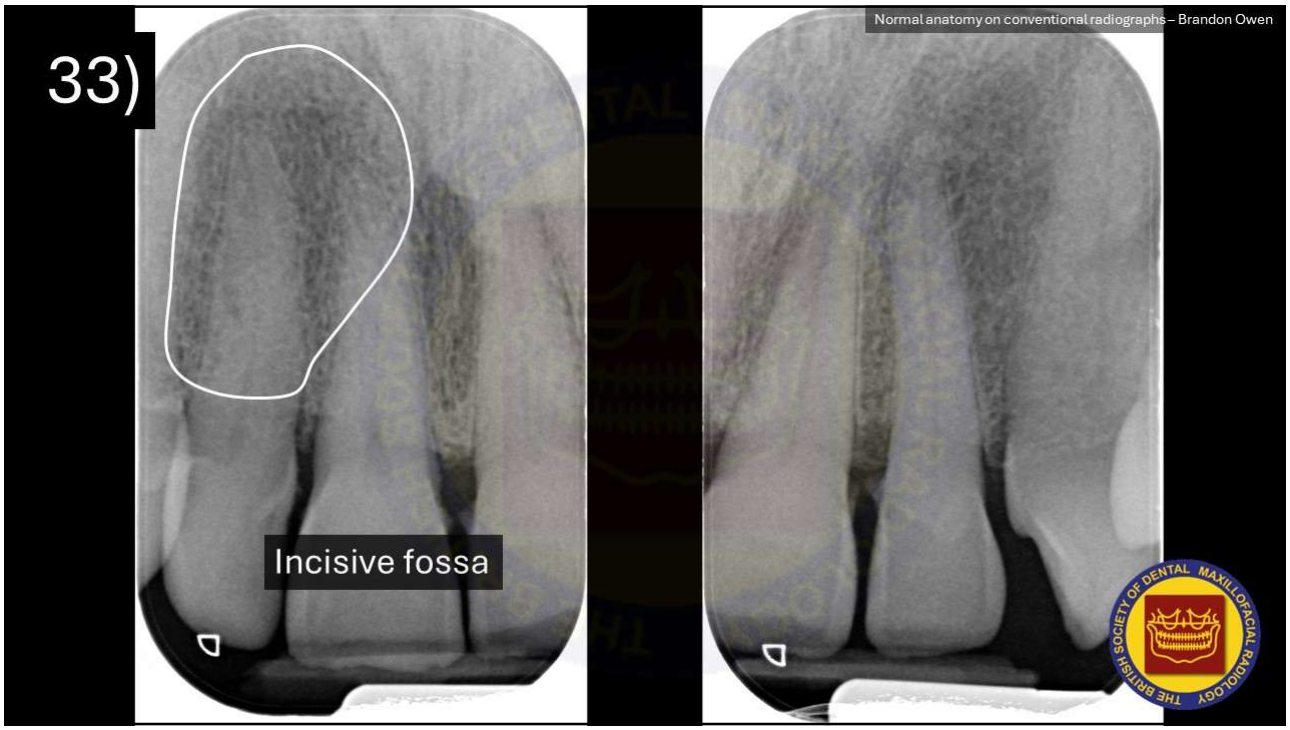
33)
Incisive fossa
Normal anatomy on conventional radiographs – Brandon Owen

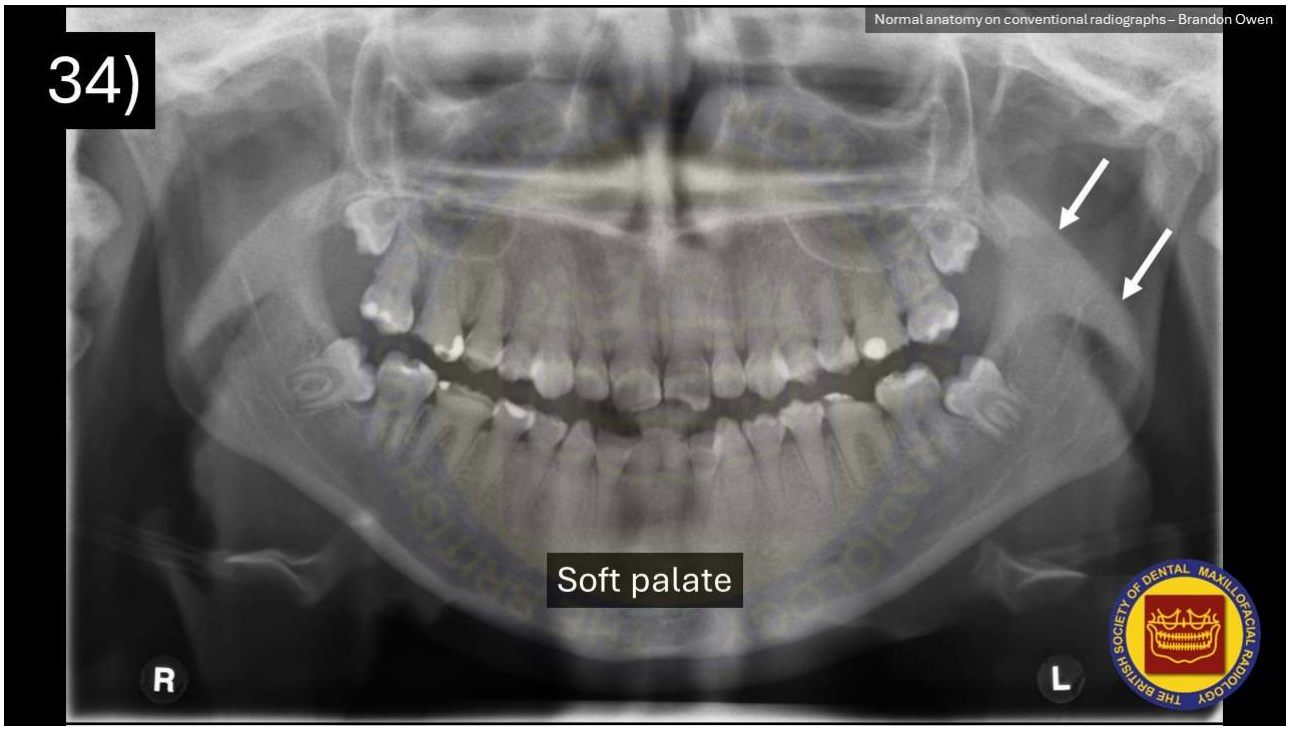
34)
Soft palate
R
L
Normal anatomy on conventional radiographs – Brandon Owen

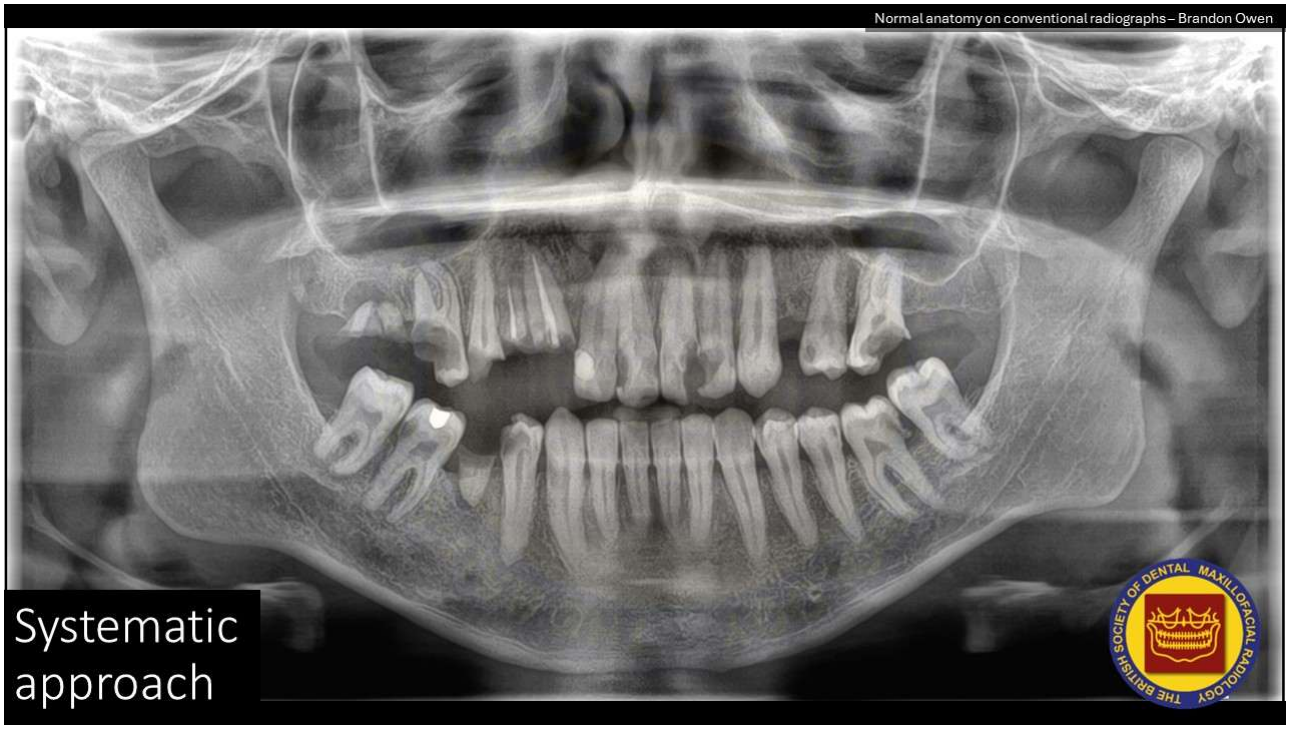

Systematic approach

Troubleshooting

- Talk to and examine your patient
- Review previous imaging
- Check other patients imaging
- Consider benefit of additional (or repeat) conventional imaging
- Seek a second opinion from colleagues or specialist reporting service

Summary

- Excellent understanding of plain radiographic anatomy is essential and will help to avoid unnecessary CBCT exposures
- Conventional radiographs and CBCT are complementary to one another, each with their own benefits and limitations