Radiolucencies

June 2026

1

Aims and Objectives

- Differentiate between normal anatomical variation / artefact and true pathological processes
- Develop methodical approach to description of radiological features
- Differentiate between radiological features of benign and potentially malignant pathology

2



3

Sigmoid notch lying outside focal trough

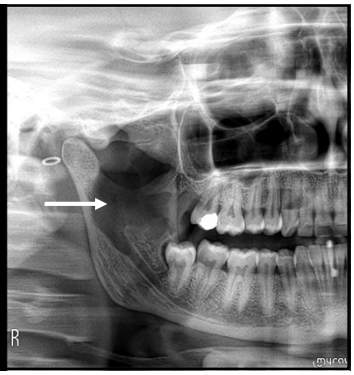

4

Superimposition of airway soft tissues



5



Sparse trabeculation

6

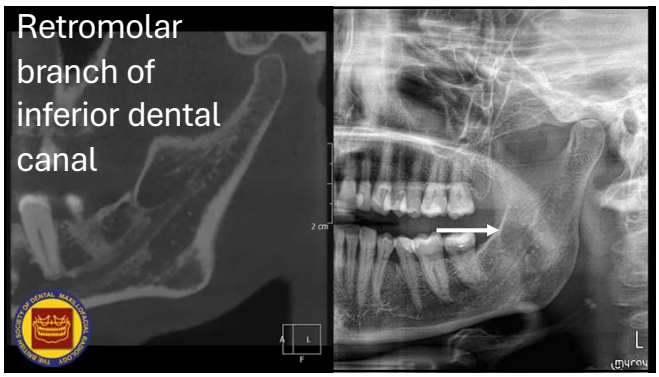
Retromolar branch of inferior dental canal

7



8

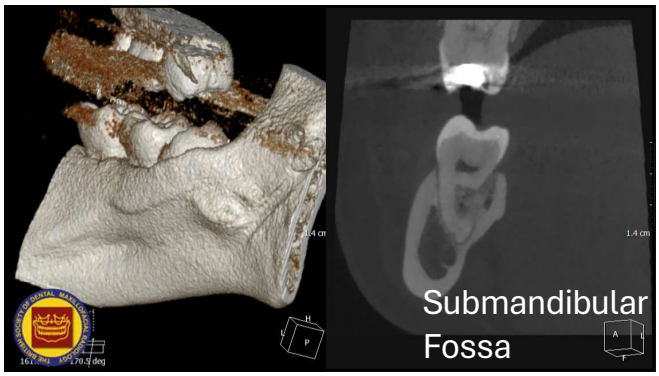
Submandibular Fossa

9

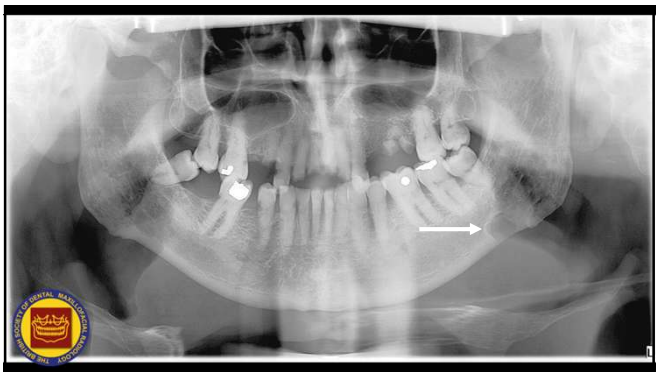

10


Stafne bone cavity

11

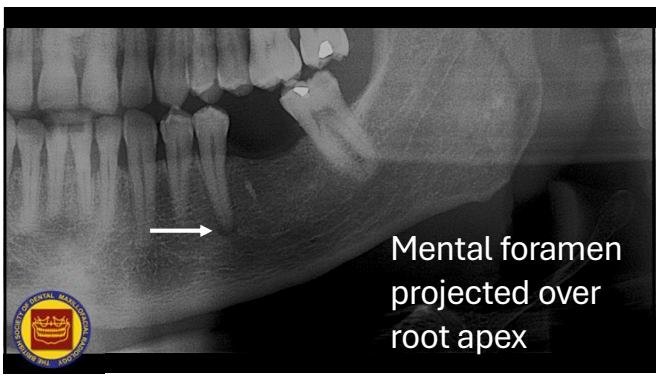
Mental foramen projected over root apex

12



13

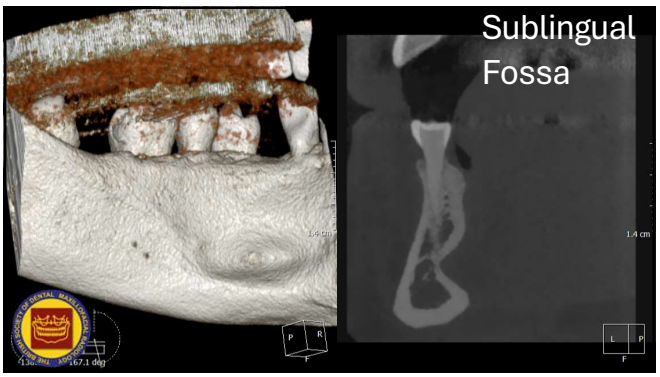

14

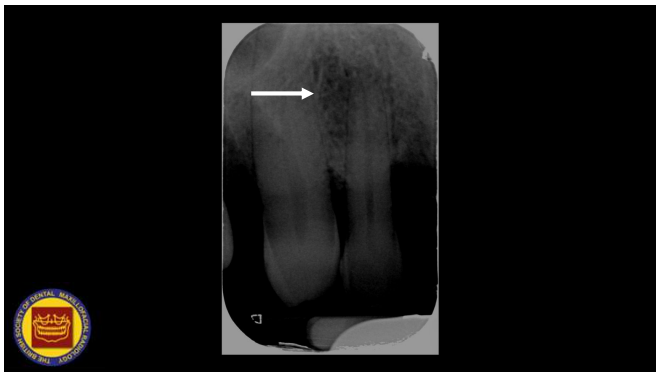

15

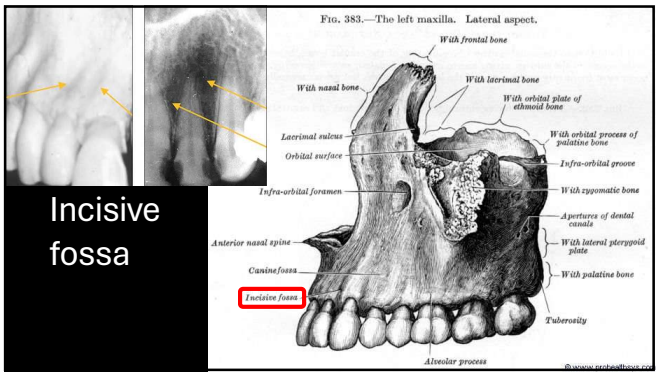

16



17

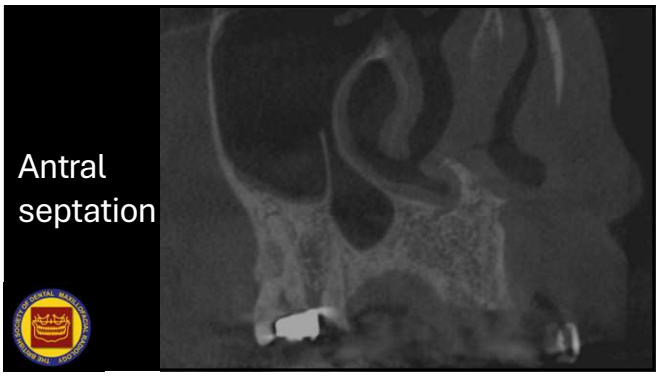

18

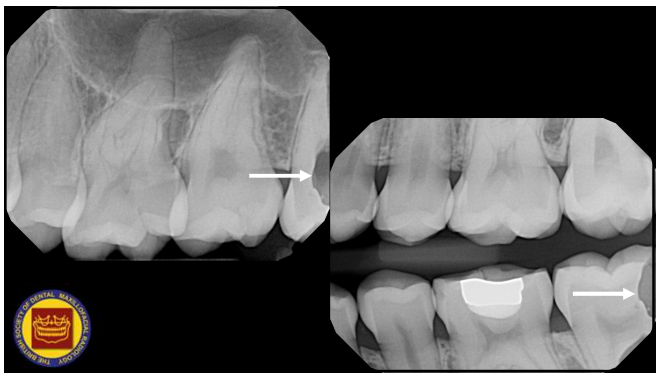

19



20

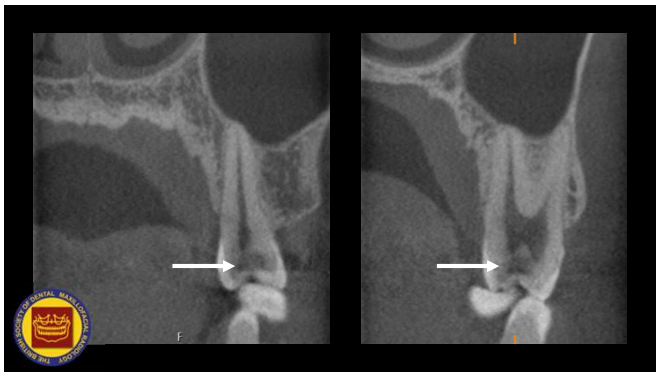

21

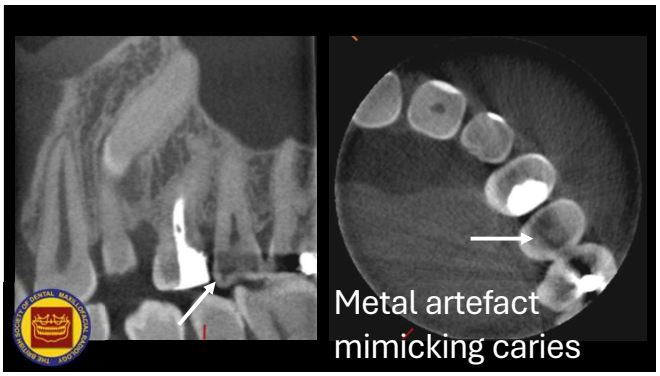

22

Description of Lesion

- Site
- Size
- Margin
- Internal structure
- Relative radiodensity
- Effect on adjacent structures

23

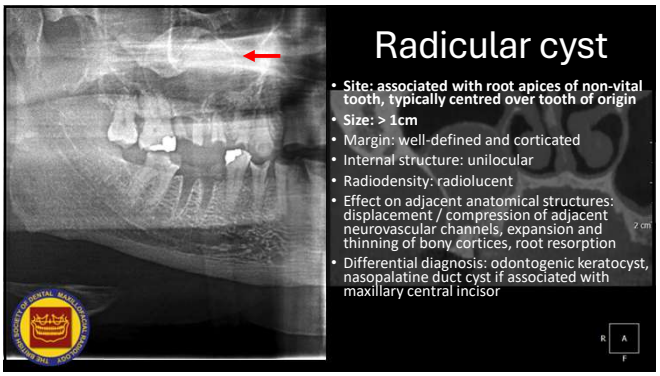

24



25

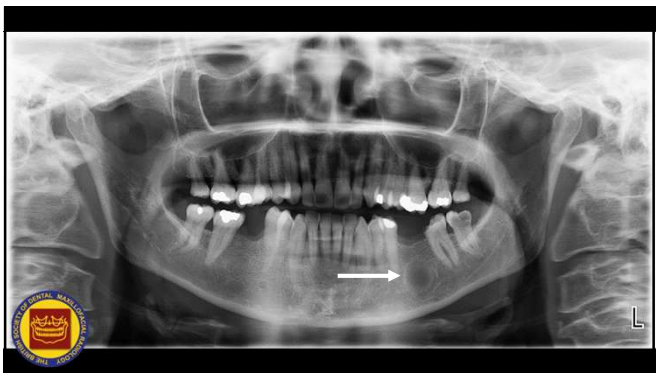

26

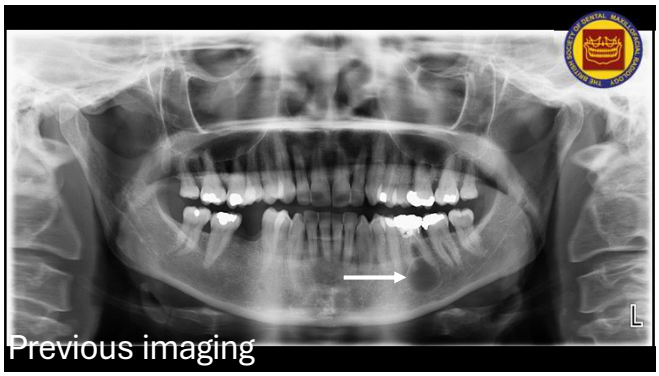

27

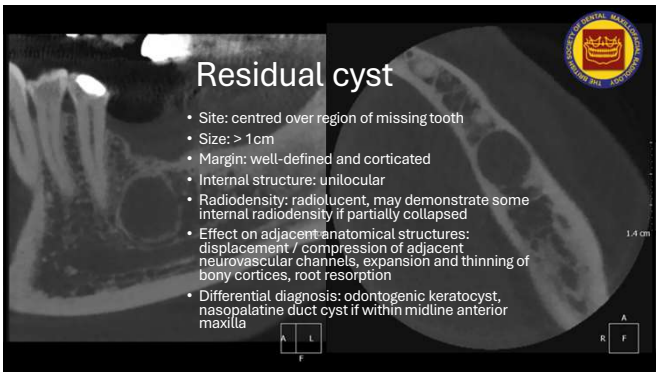

28

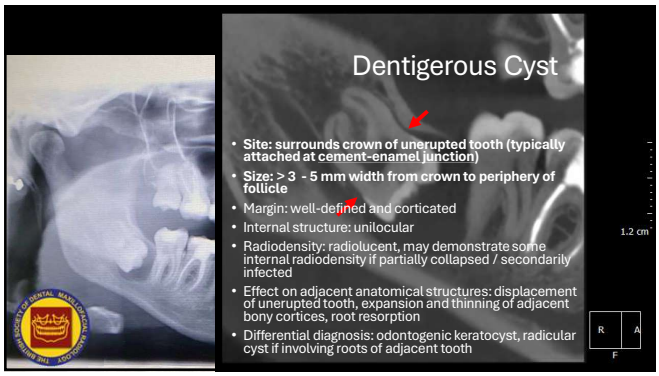

29

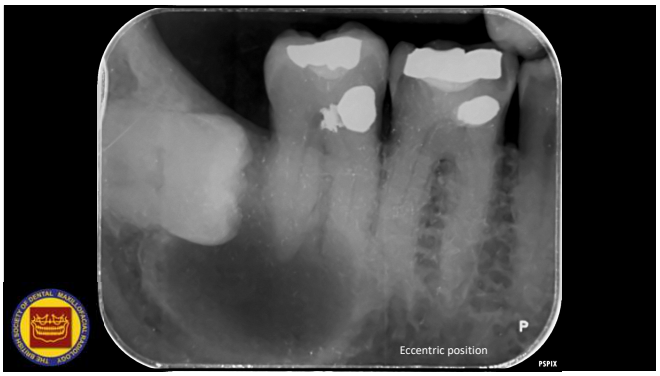

30

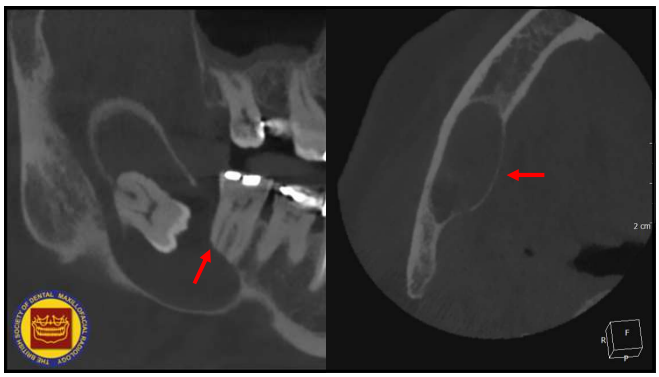

31

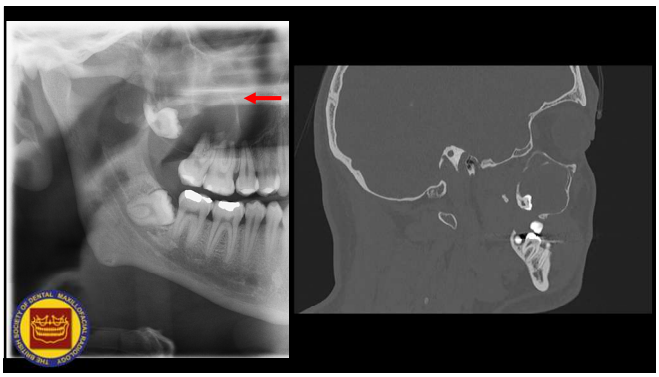

32

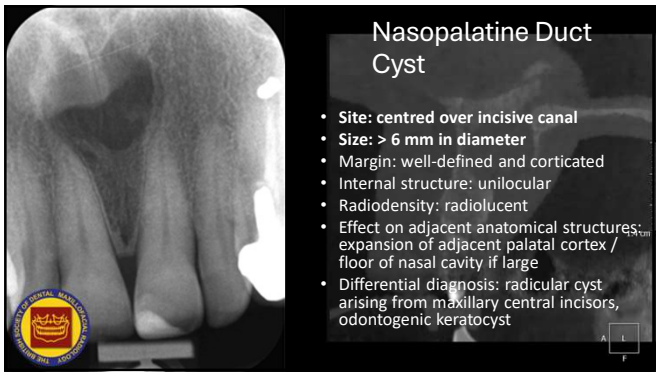

33

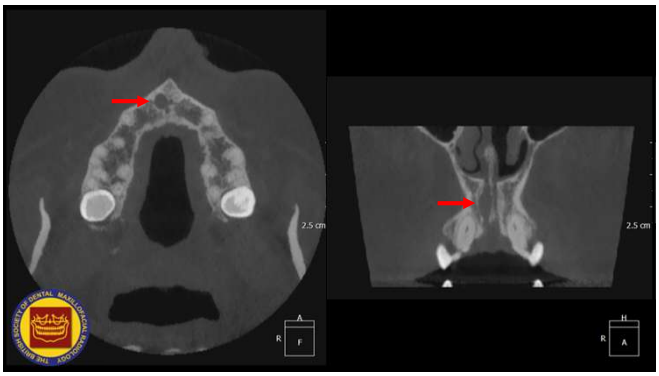

34

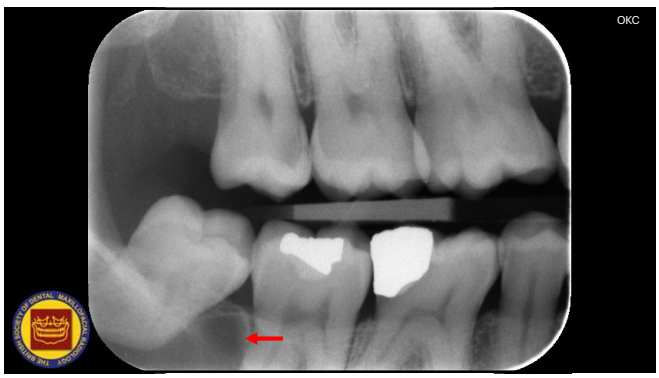

35

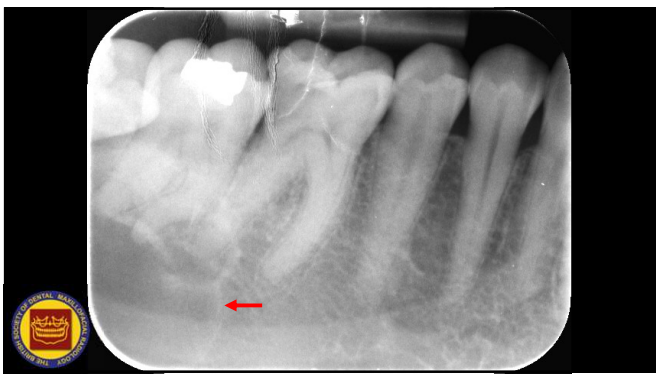

36

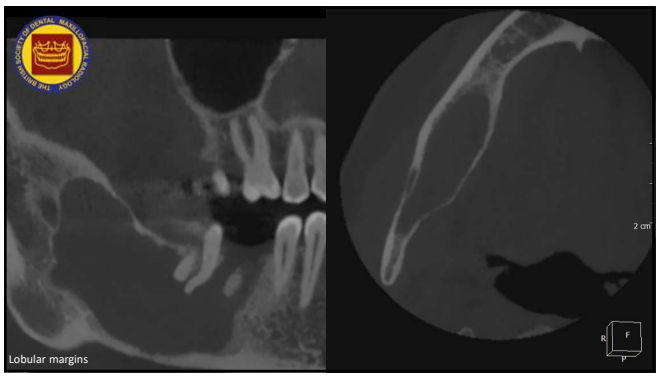

37



38

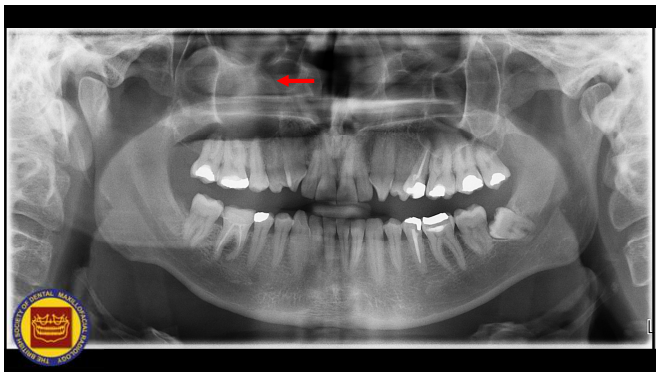

39

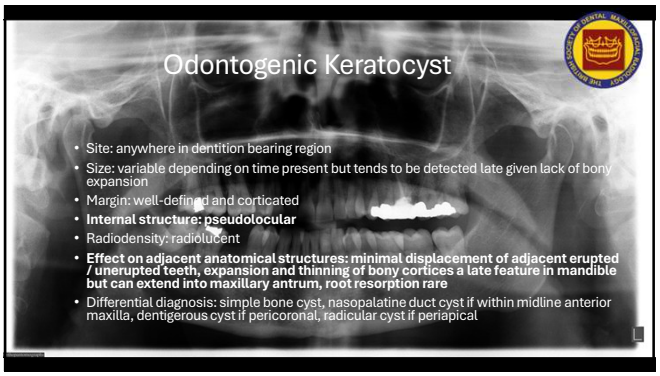

40

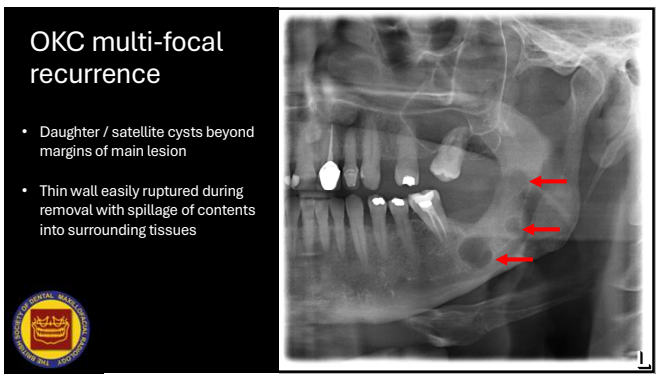

41

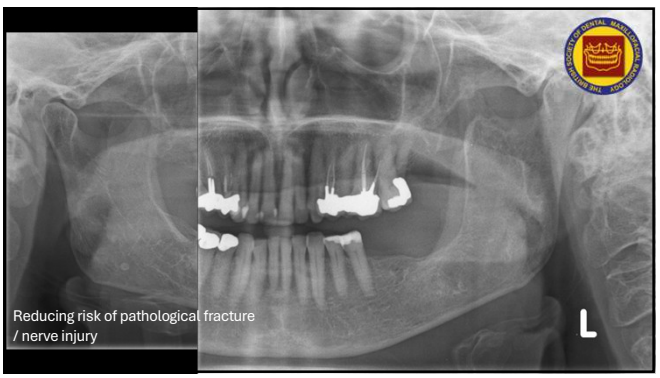

42

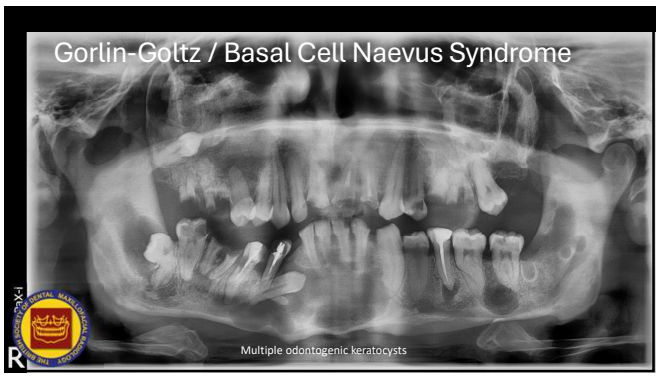

43



44



45

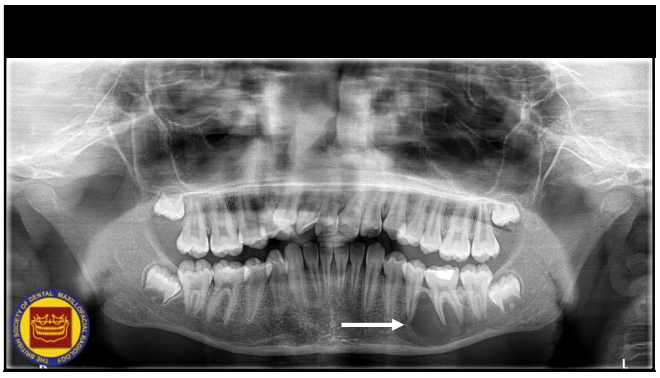

46



Simple Bone "Cyst"

- Site: typically mandible
- Size: variable but can be large if longstanding
- **Margin: well-defined and corticated, classic undulation between roots of teeth**
- Internal structure: uni- / pseudo-locular
- Radiodensity: radiolucent
- Effect on adjacent anatomical structures: mild expansion of adjacent cortices, no root resorption or displacement of adjacent anatomical structures
- Differential diagnosis: odontogenic keratocyst, central giant cell granuloma, radicular cyst

47

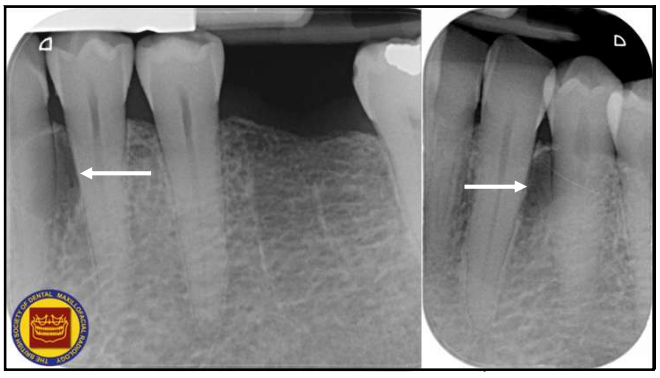

48

Lateral Periodontal Cyst

- **Site: classically between roots of premolar dentition**
- Size: variable but typically < 1 cm in diameter
- Margin: well-defined and corticated
- Internal structure: unilocular (except botryoid variant)
- Radiodensity: radiolucent
- Effect on adjacent anatomical structures: minimal displacement of adjacent erupted / unerupted teeth, expansion and thinning of adjacent bony cortices, root resorption rare
- Differential diagnosis: odontogenic keratocyst, simple bone cyst, radicular cyst arising from lateral canal



49



Lateral Periodontal Cyst (Botryoid Variant)

50

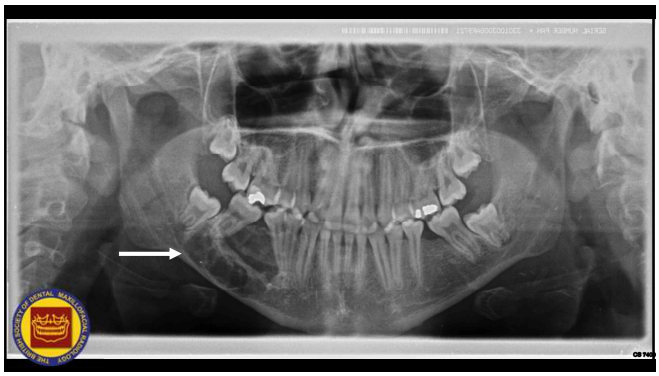

51

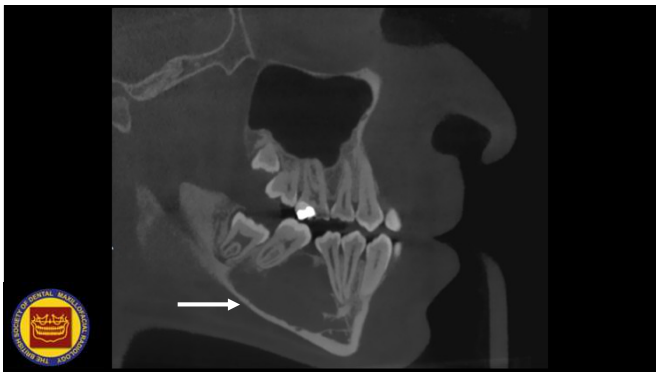

52

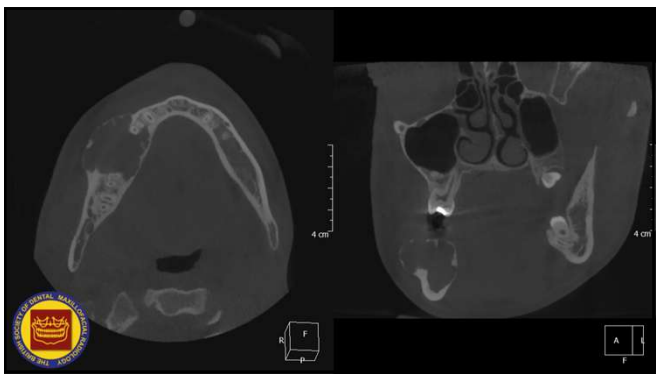

53



Central Giant Cell Granuloma

- Site: typically mandible, anterior to first permanent molar
- Size: variable but can be large if longstanding
- Margin: well-defined and corticated, classic superior extension / undulation between roots of teeth
- **Internal structure: multilocular with thin / wispy internal septations (like cigarette smoke)**
- Radiodensity: radiolucent
- **Effect on adjacent anatomical structures: expansion of adjacent bony cortices, displacement of adjacent teeth common, root resorption less likely**
- Differential diagnosis: simple bone cyst, ameloblastoma, odontogenic keratocyst

54

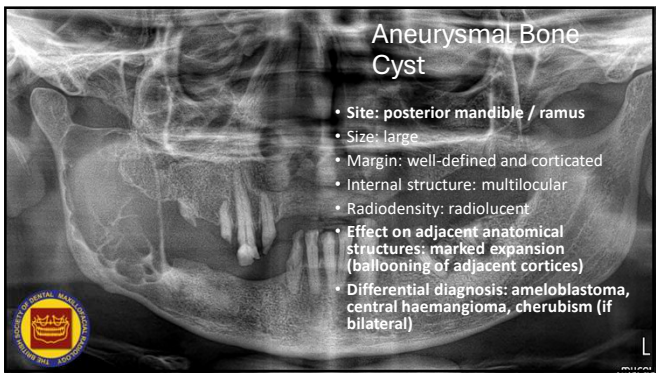

55

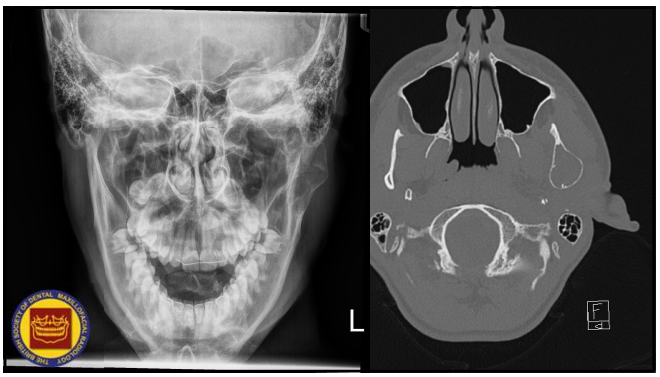

56



57

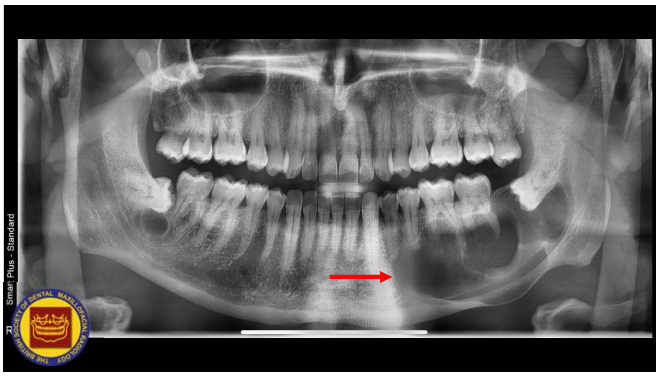

58

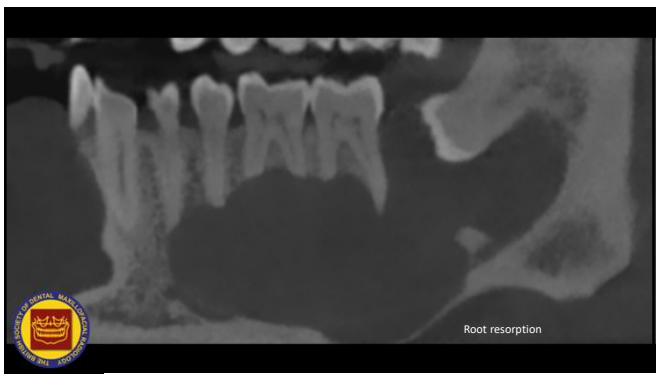

59

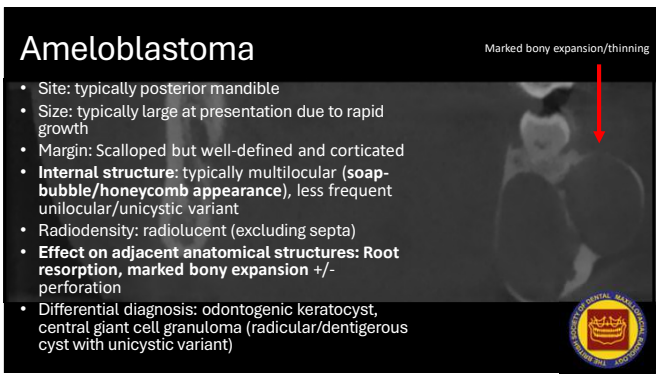

60

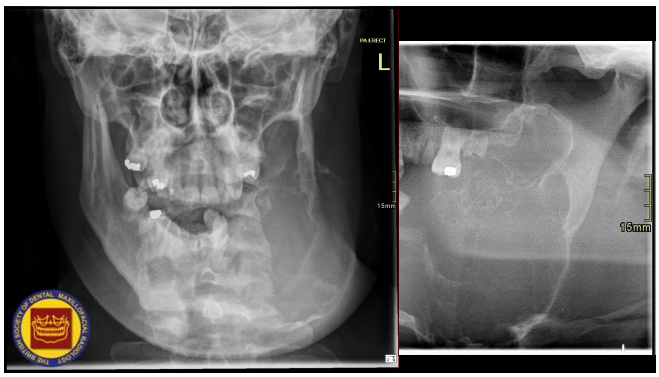

61



62

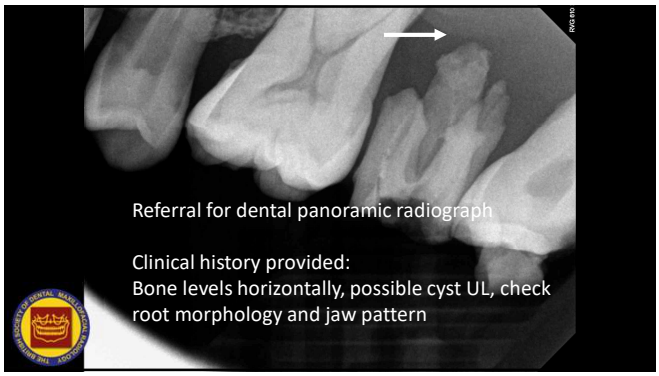

63

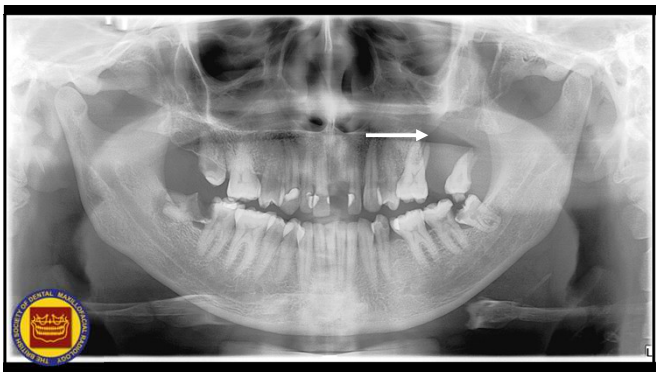

64

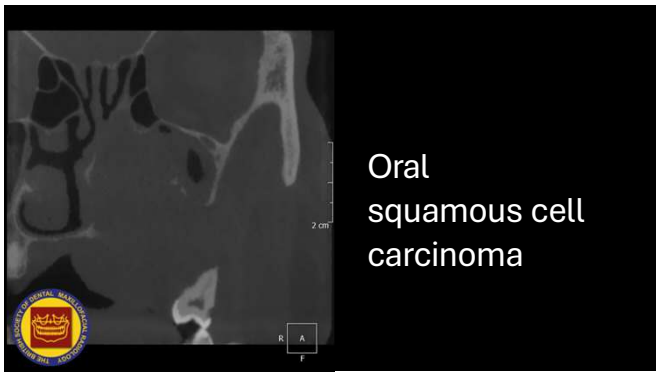

65

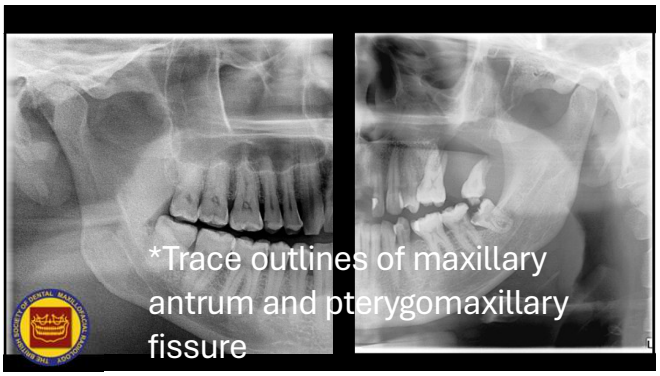

66

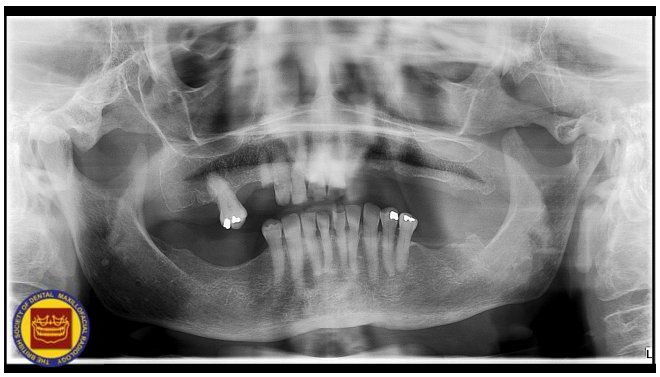

67

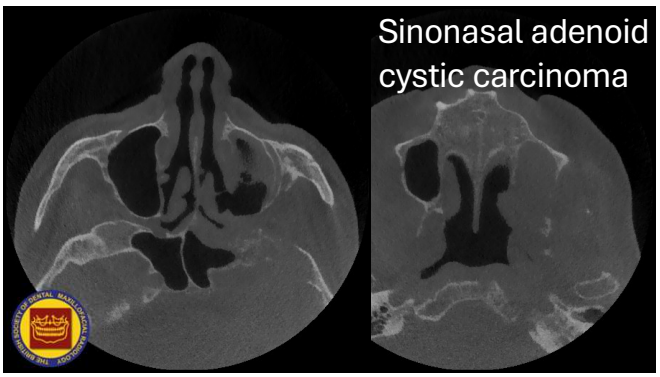

68

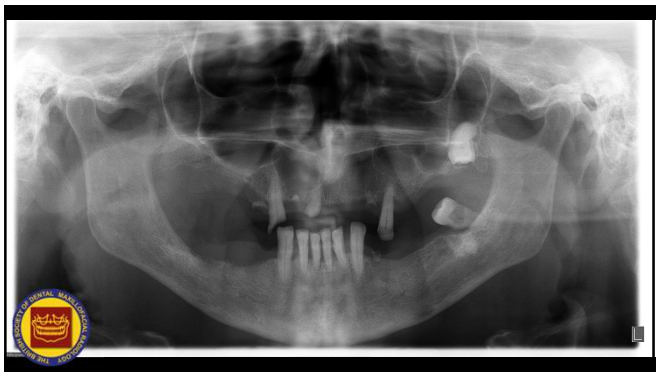

69

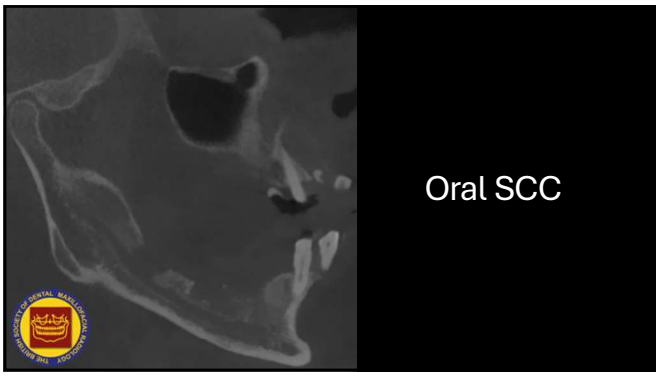

70

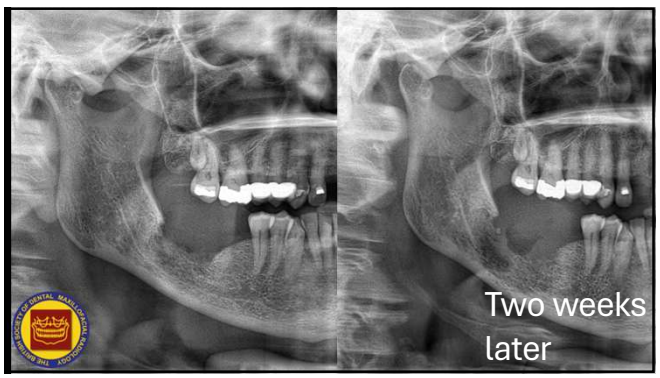

71

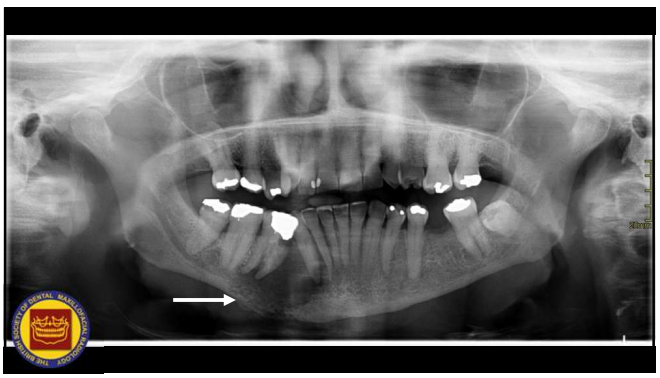

72

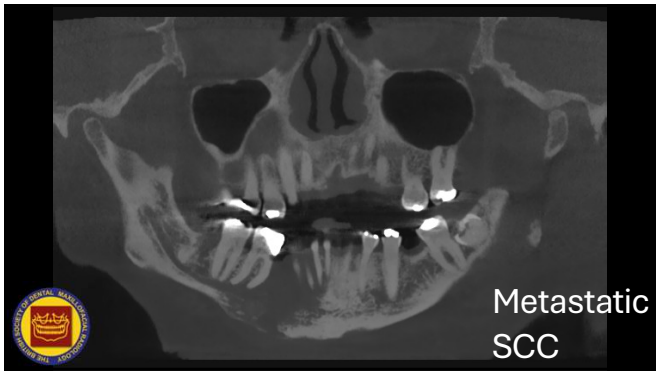

73

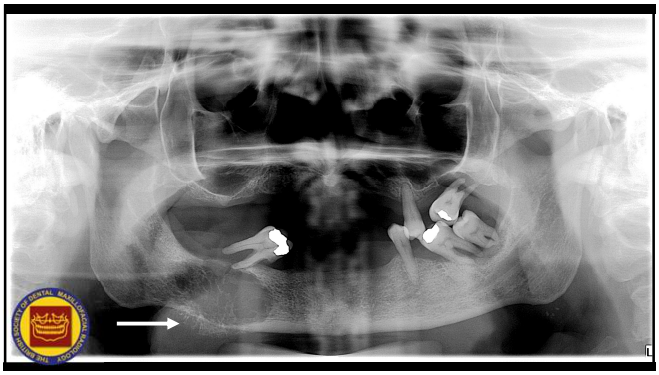

74

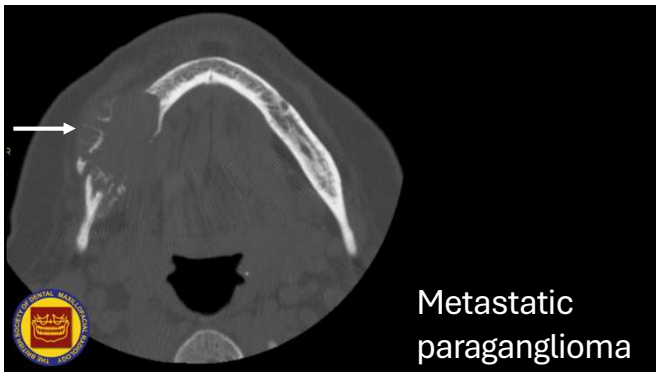

75

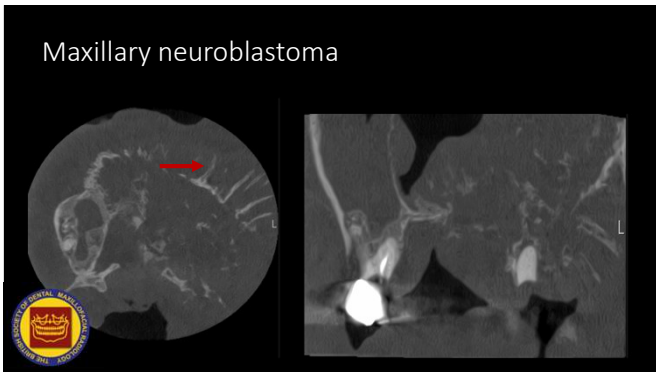

76

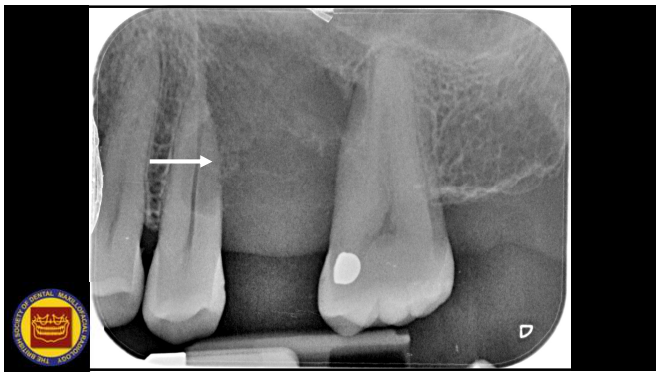

77

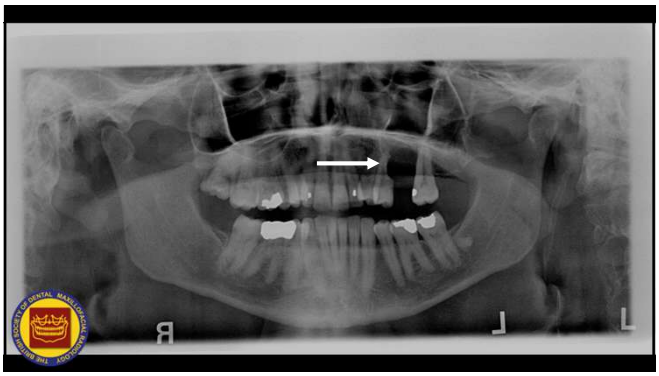

78



79



80

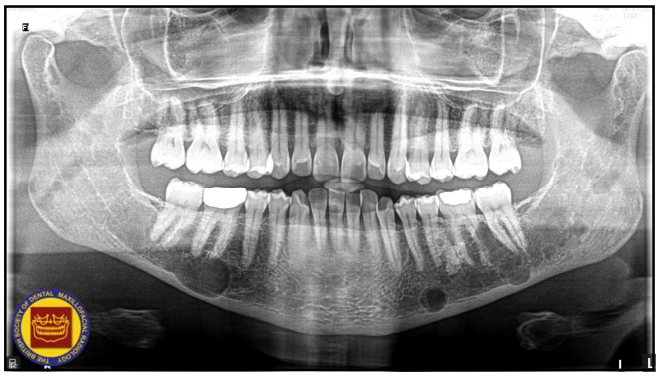

81

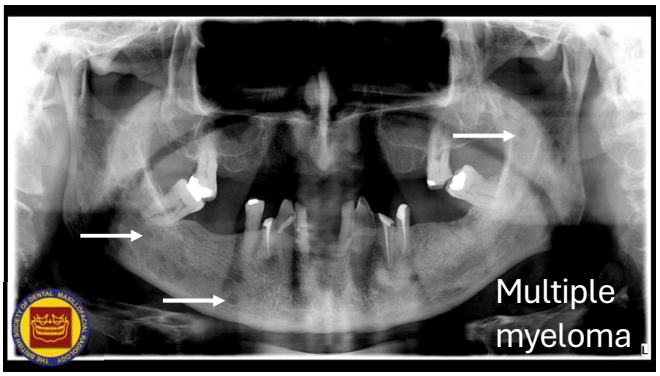

82



83

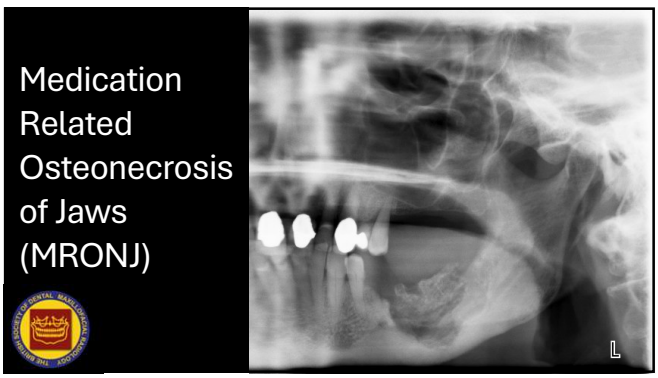

84

Summary

- If unsure (even if suspect normal anatomical variation), consider referral for second/radiological opinion
- If obvious lesion with benign features (e.g. well-defined, corticated) then appropriate referral pathway to OS/OMFS for management
- If concerning features (e.g. ill-defined, floating teeth, sunray spiculation), then urgent referral
- Consider the radiological findings in context of clinical history e.g. longstanding, paraesthesia
- Review previous radiographs where available – can provide idea of rate of progression or stability

85

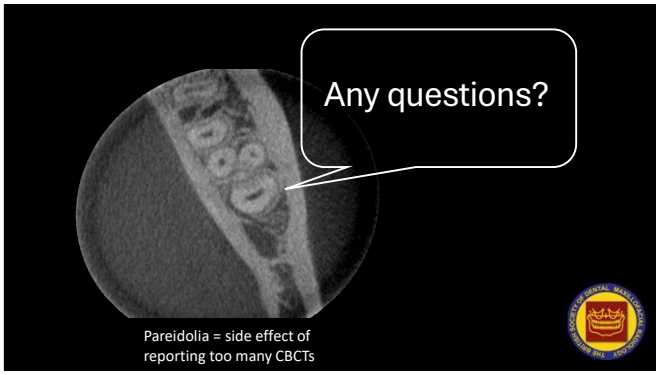

86