# Radiopacities within the Dentoalveolar Region

Brandon Owen
Consultant Dental & Maxillofacial Radiologist
Manchester NHS Foundation Trust



## Aims & Objective

- To recognise common radiopacities arising within the dental and maxillofacial region and their differing appearances on conventional and cross-sectional imaging.

# Site – 2D vs 3D

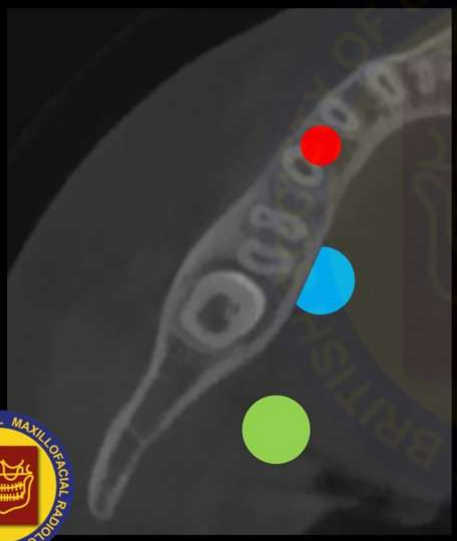

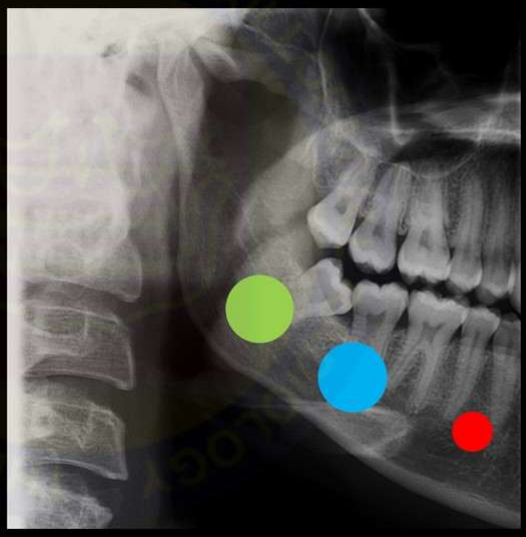



# Dense Bone Island (DBI) / Enostosis




Radiopacities within the dentoalveolar region – Brandon Owen

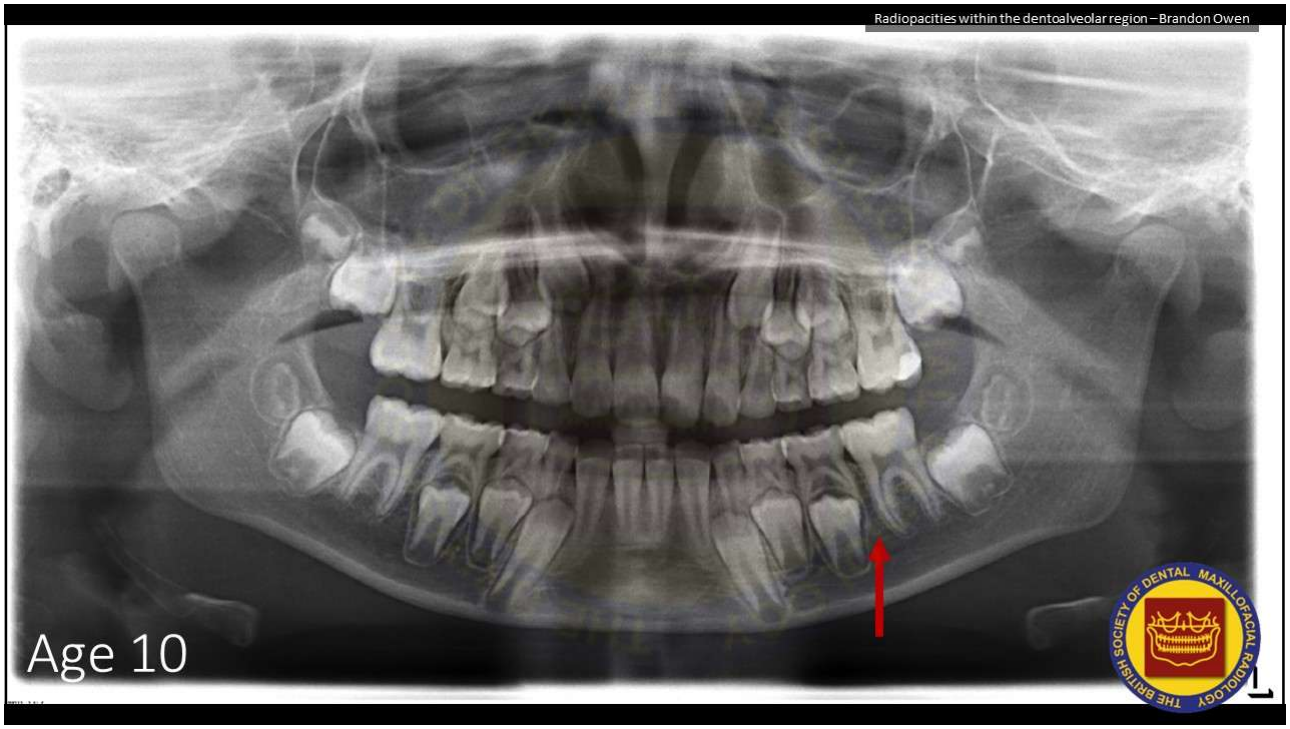
Radiopacities within the dentoalveolar region – Brandon Owen
Age 10

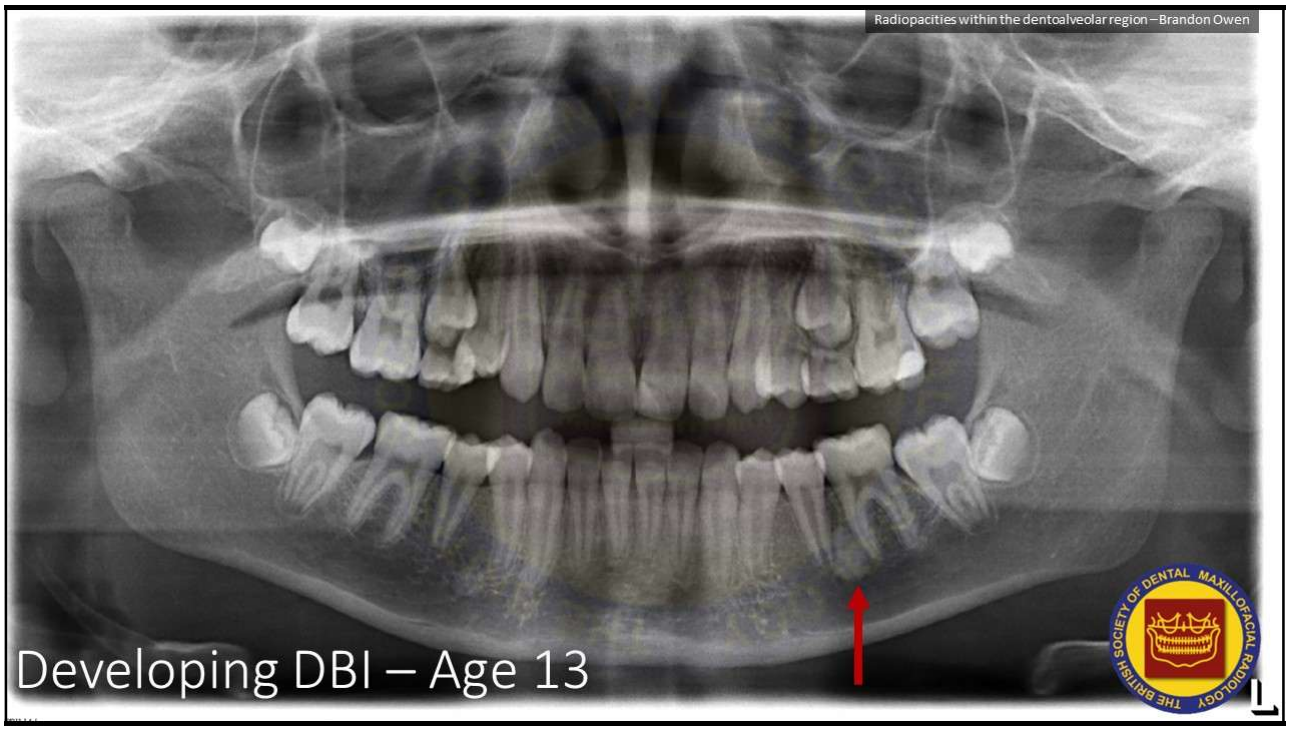
Radiopacities within the dentoalveolar region – Brandon Owen
Developing DBI – Age 13

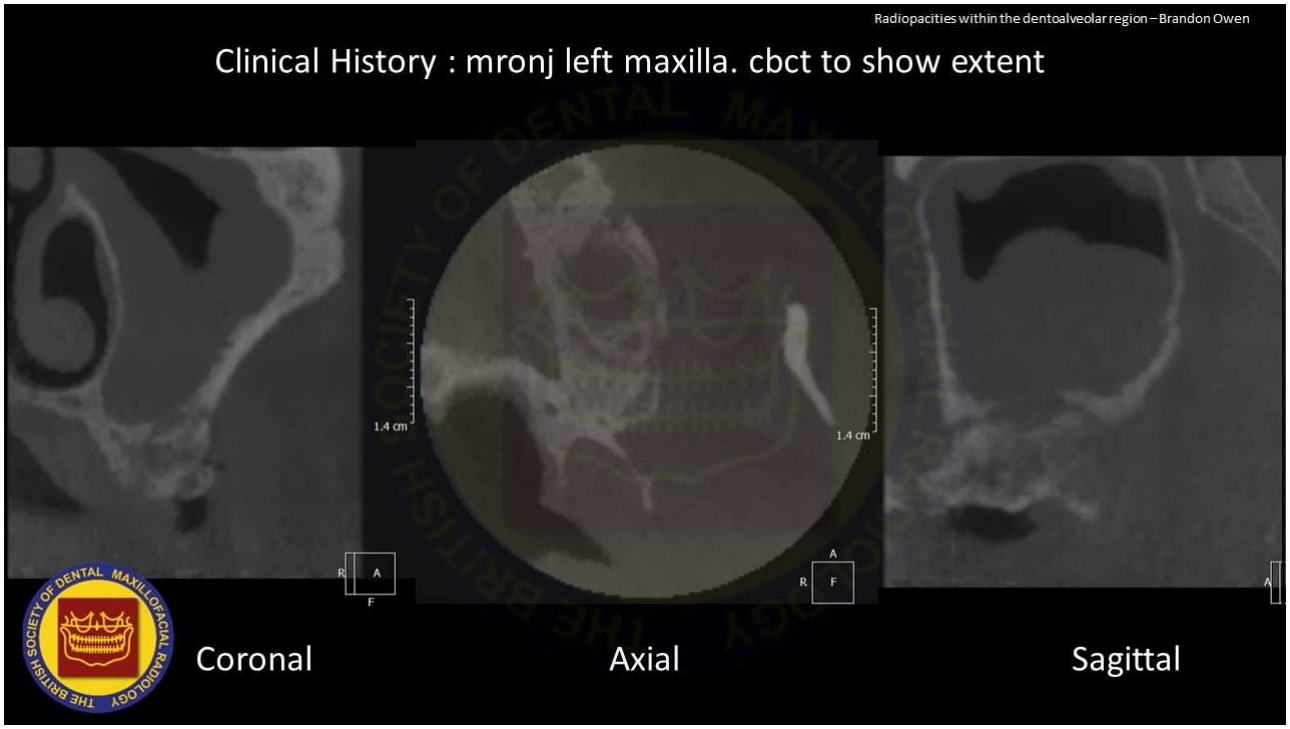
Radiopacities within the dentoalveolar region – Brandon Owen
Clinical History : mronj left maxilla. cbct to show extent
1.4 cm
1.4 cm
Coronal
Axial
Sagittal

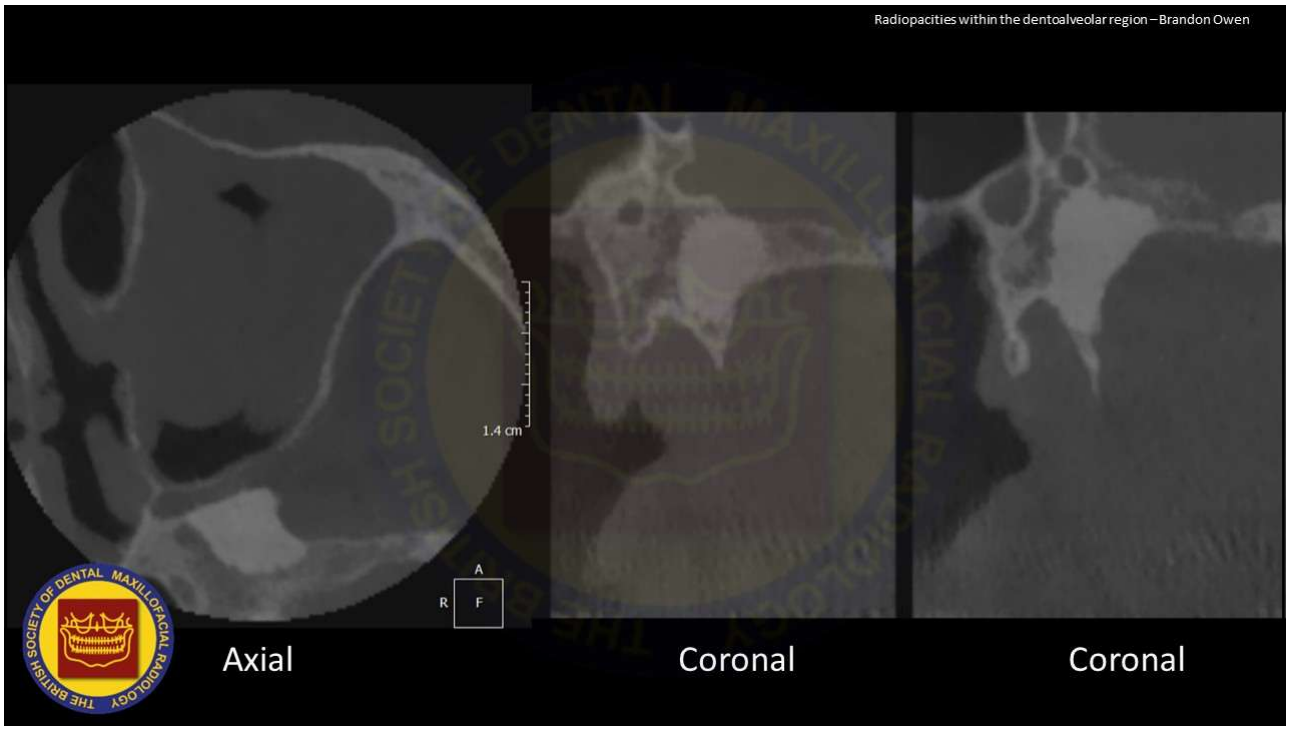
Radiopacities within the dentoalveolar region – Brandon Owen
1.4 cm
A
R
F
Axial
Coronal
Coronal

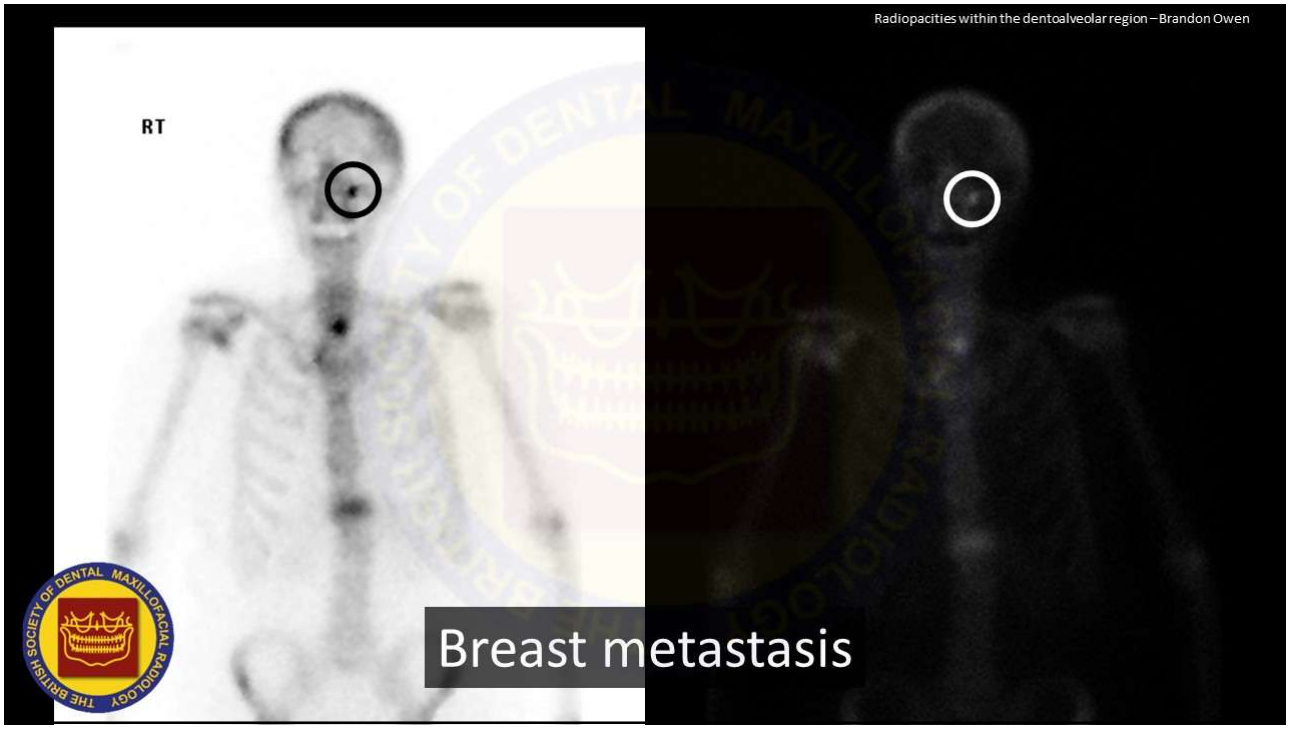
Radiopacities within the dentoalveolar region – Brandon Owen
RT
Breast metastasis

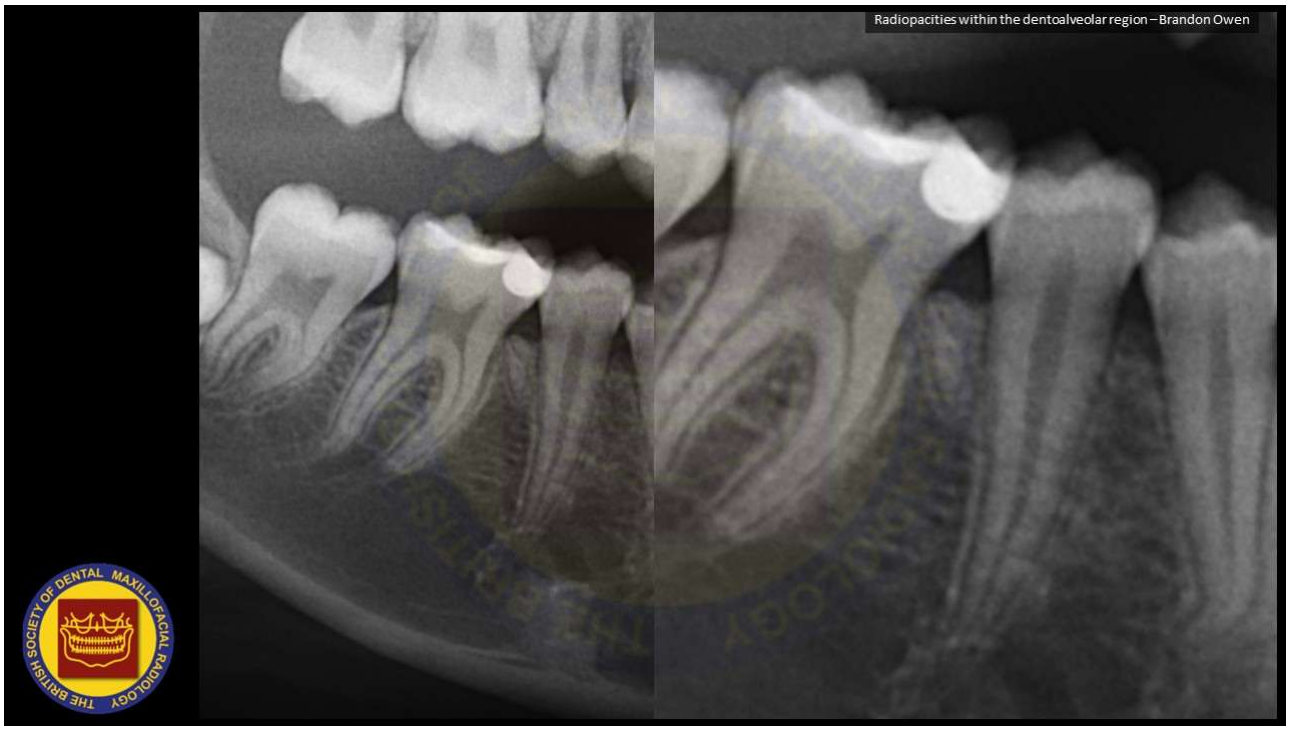
Radiopacities within the dentoalveolar region – Brandon Owen

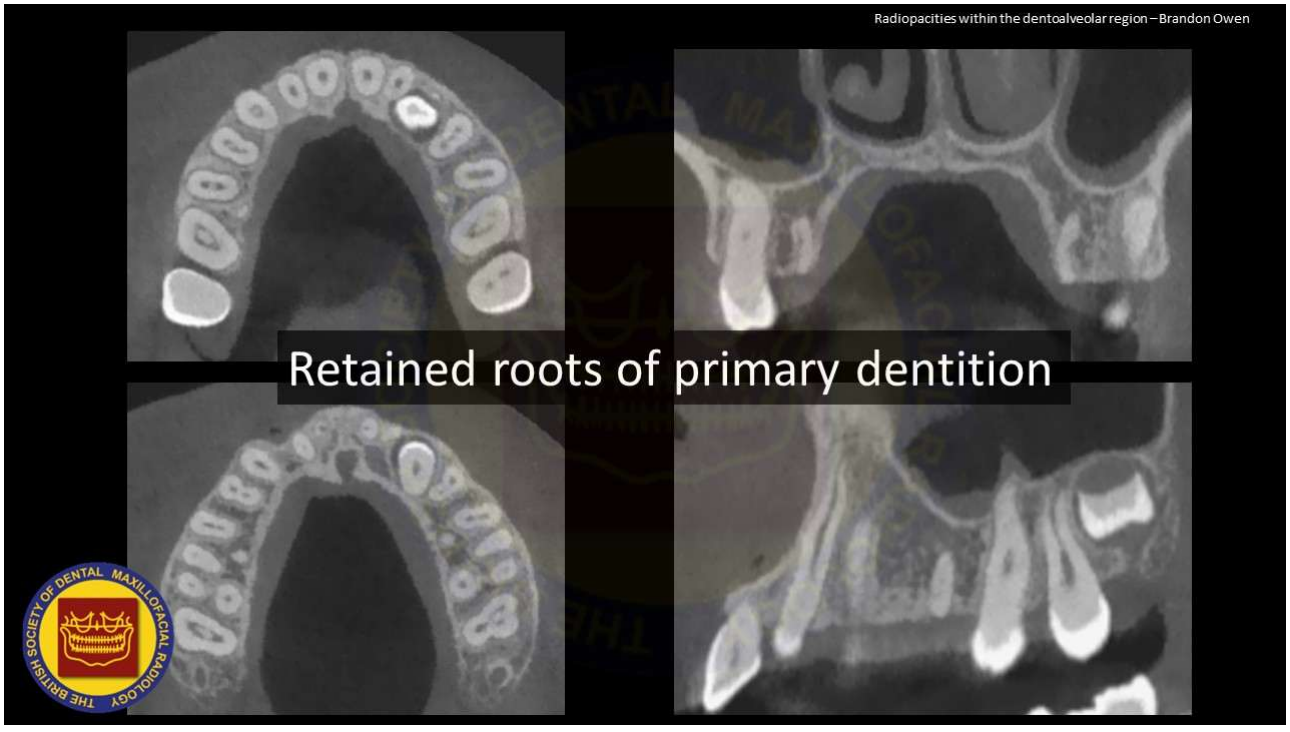
Radiopacities within the dentoalveolar region – Brandon Owen
Retained roots of primary dentition

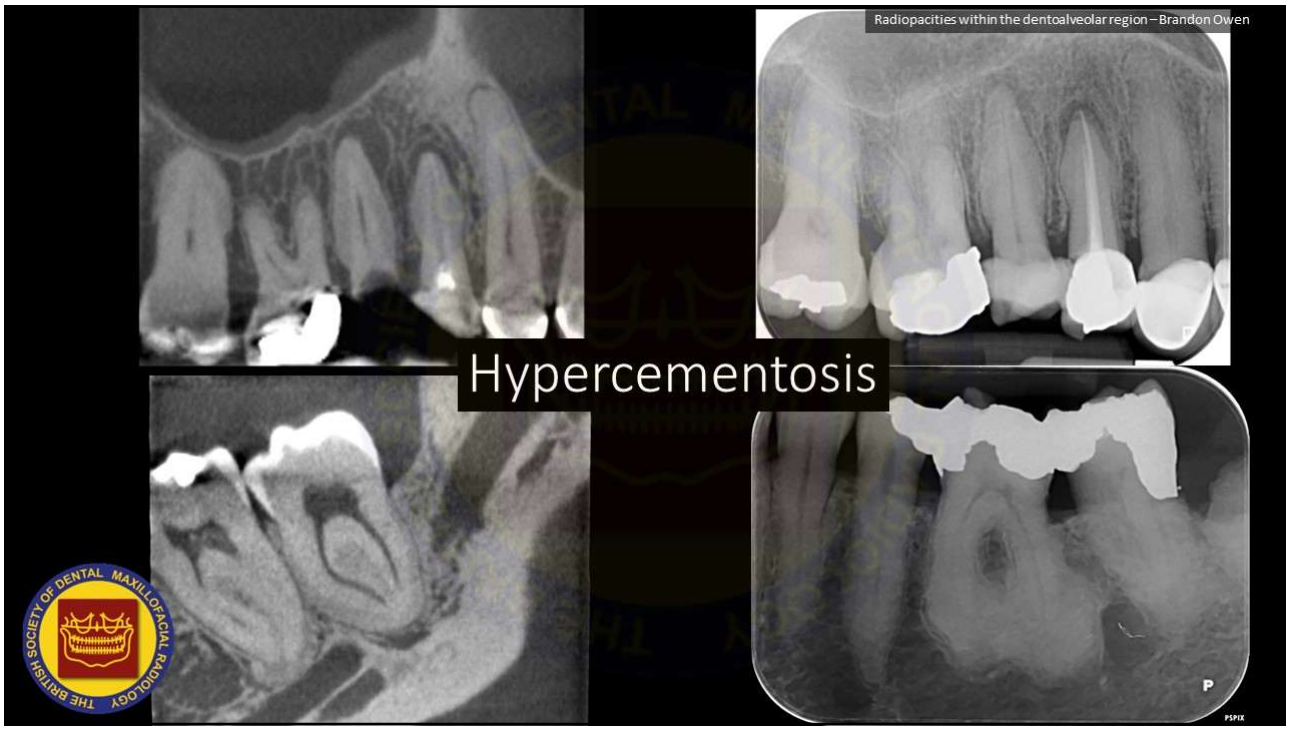
Radiopacities within the dentoalveolar region – Brandon Owen
Hypercementosis
THE BRITISH SOCIETY OF DENTAL MAXILLOFACIAL RADIOLOGY
P
PSPIX

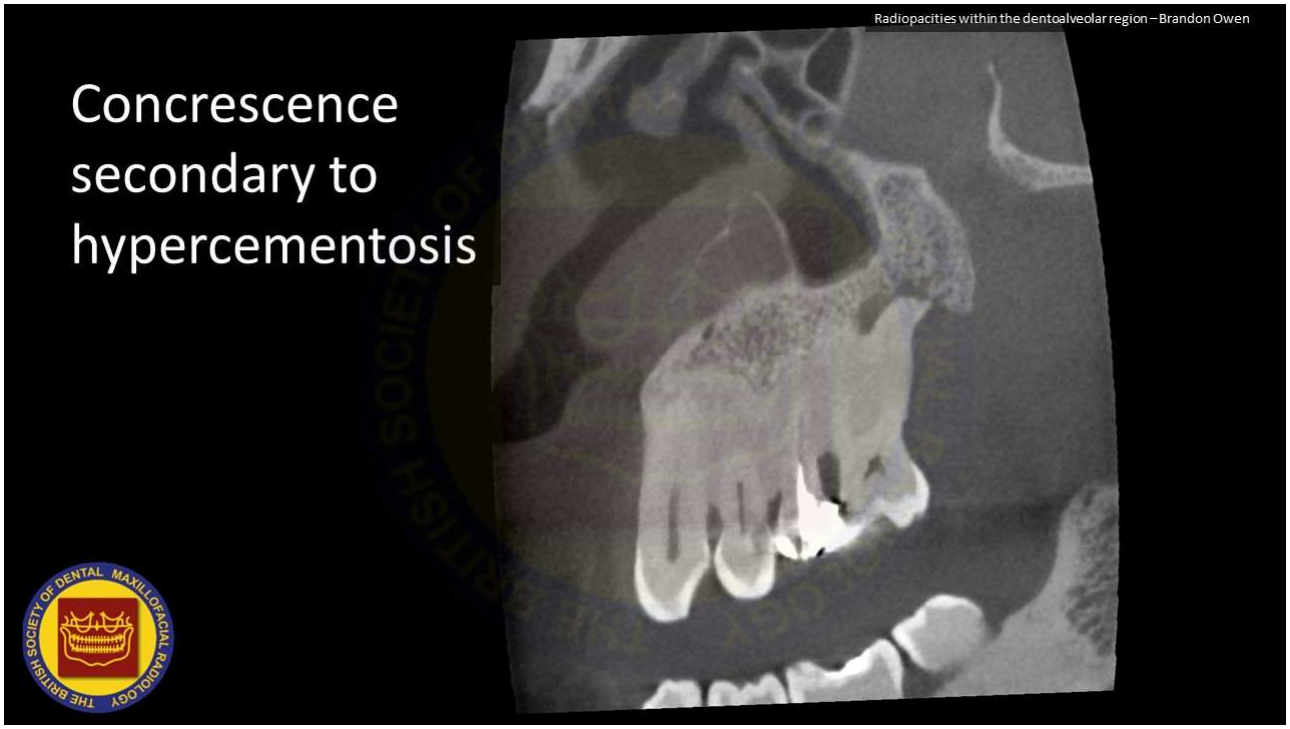
Radiopacities within the dentoalveolar region – Brandon Owen
Concrescence secondary to hypercementosis
THE BRITISH SOCIETY OF DENTAL MAXILLOFACIAL RADIOLOGY

# Cementoblastoma

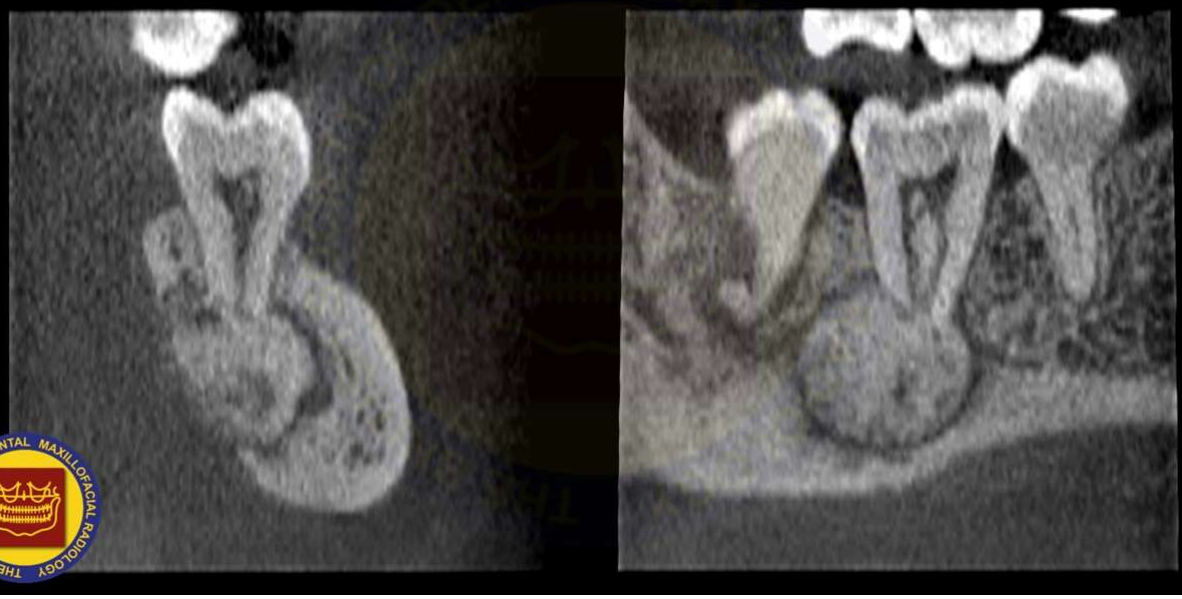



# Osteoma

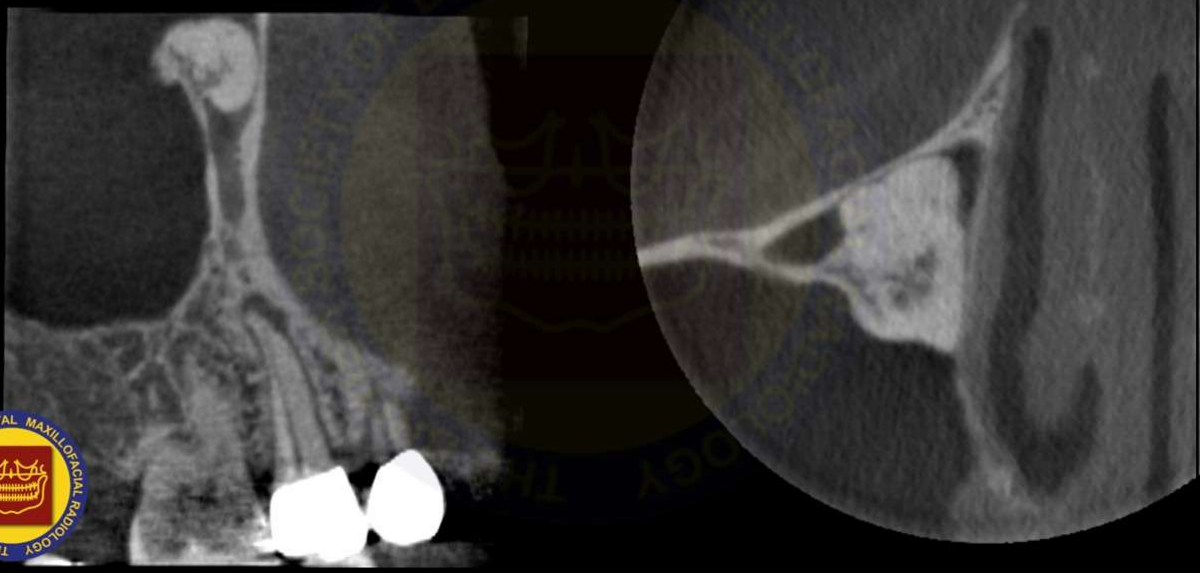


Radiopacities within the dentoalveolar region – Brandon Owen
THE BRITISH SOCIETY OF DENTAL MAXILLOFACIAL RADIOLOGY

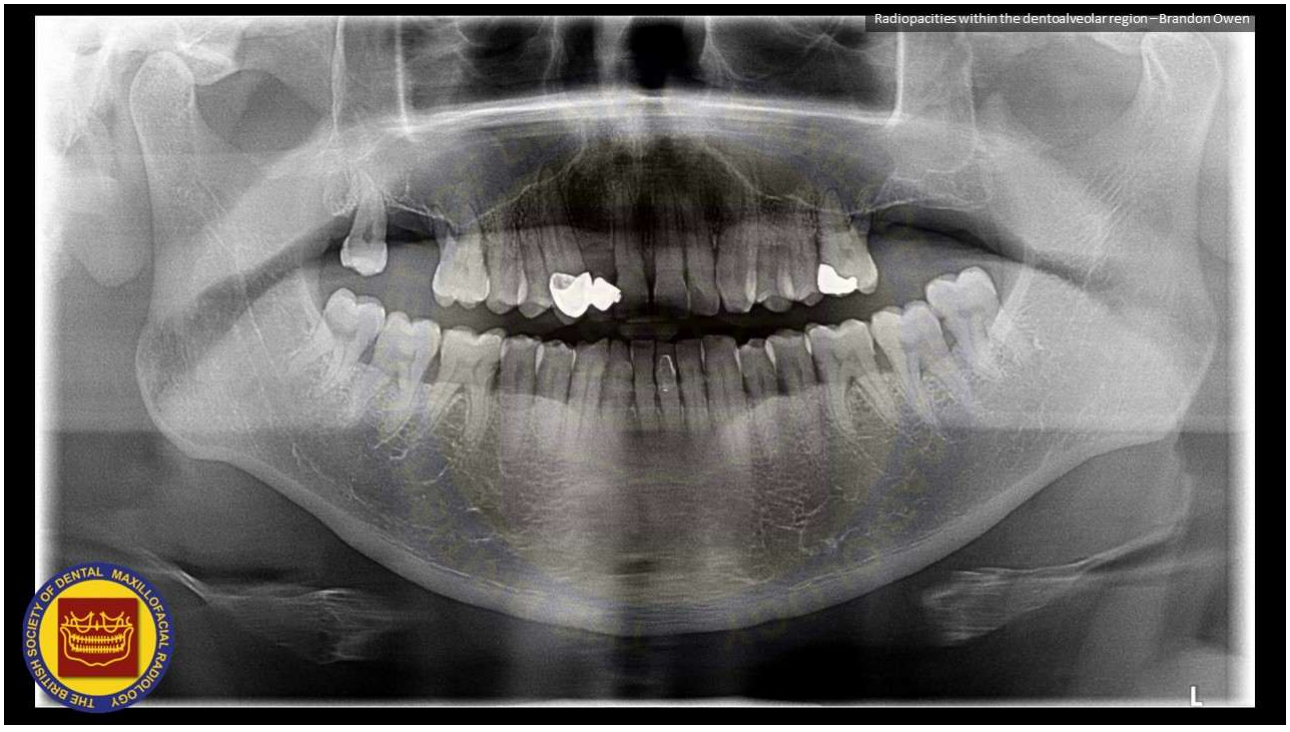
Radiopacities within the dentoalveolar region – Brandon Owen
THE BRITISH SOCIETY OF DENTAL MAXILLOFACIAL RADIOLOGY
L

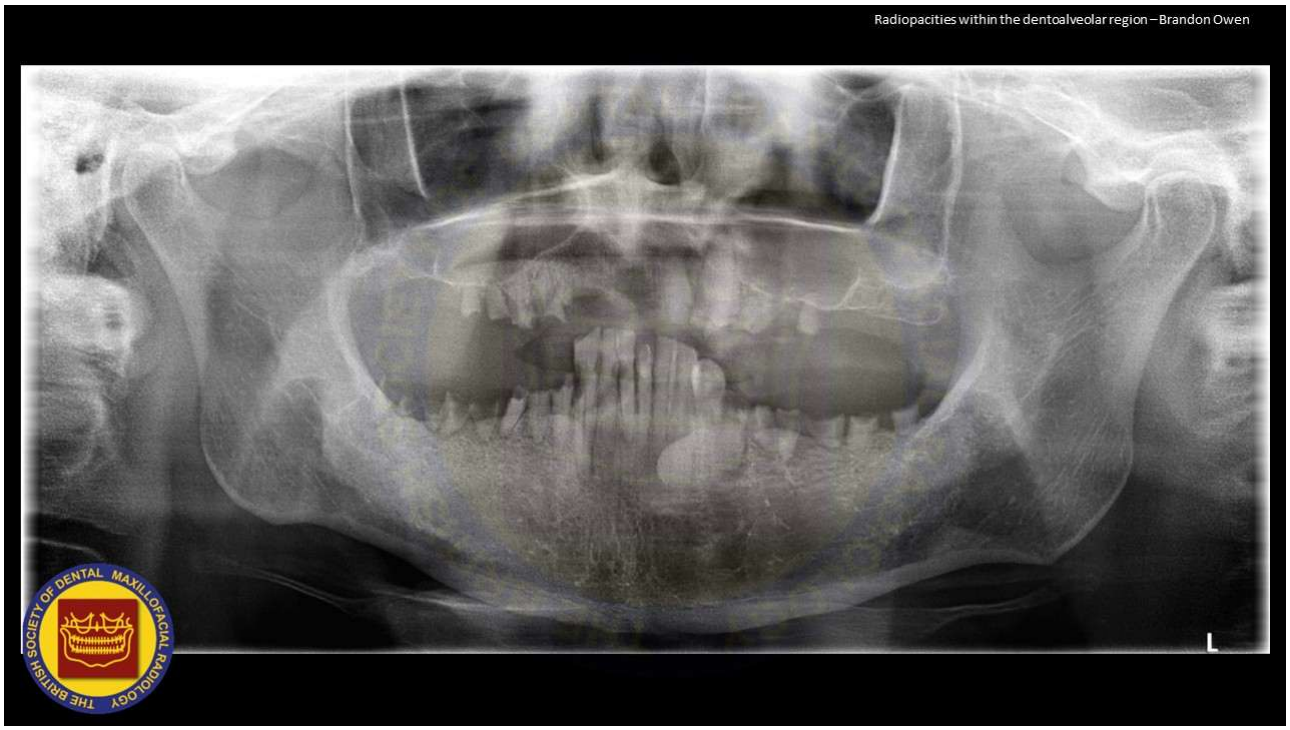
Radiopacities within the dentoalveolar region – Brandon Owen
L

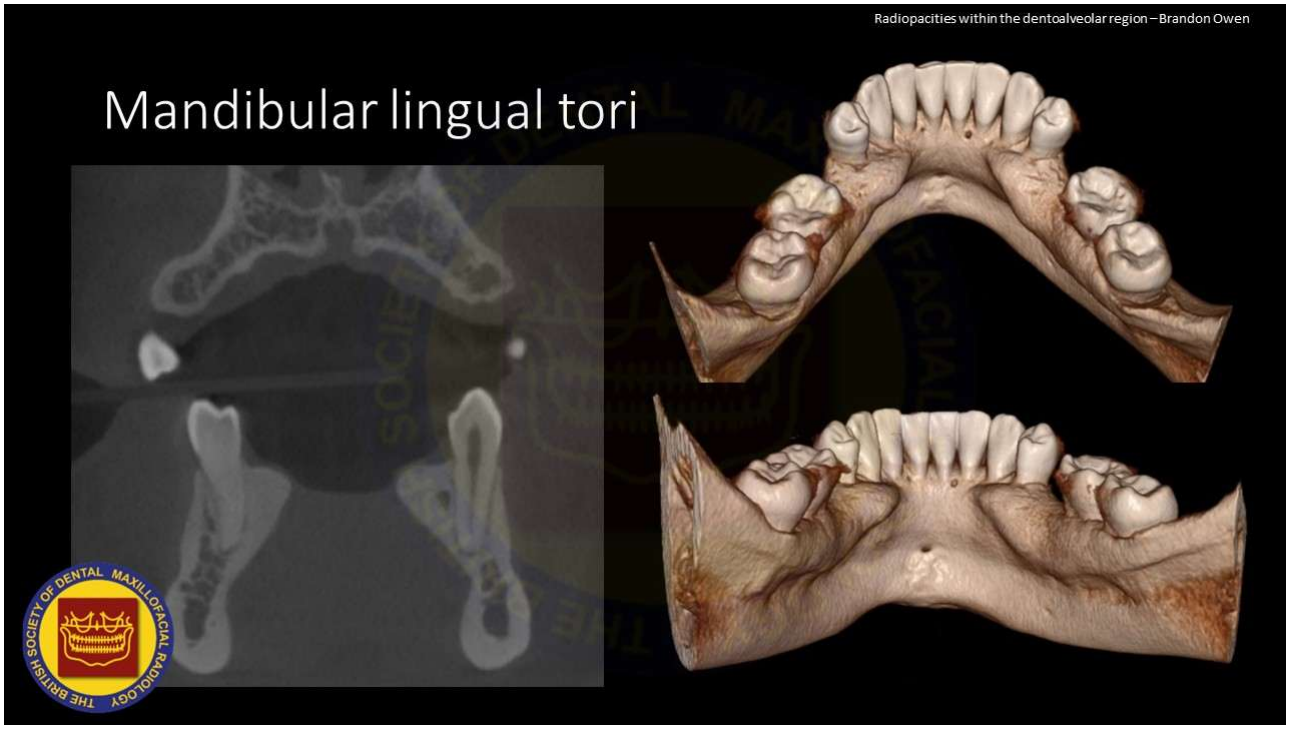
Radiopacities within the dentoalveolar region – Brandon Owen
Mandibular lingual tori


Radiopacities within the dentoalveolar region – Brandon Owen

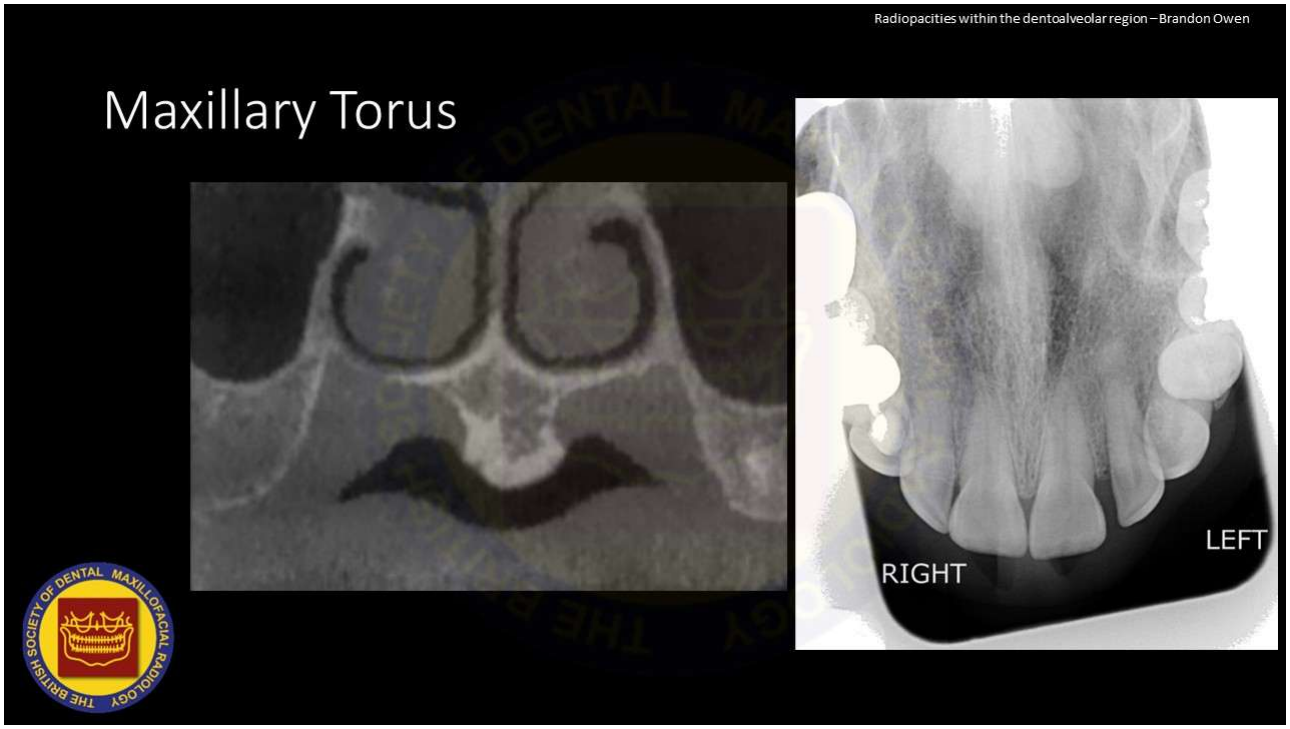
Radiopacities within the dentoalveolar region – Brandon Owen
Maxillary Torus
RIGHT
LEFT

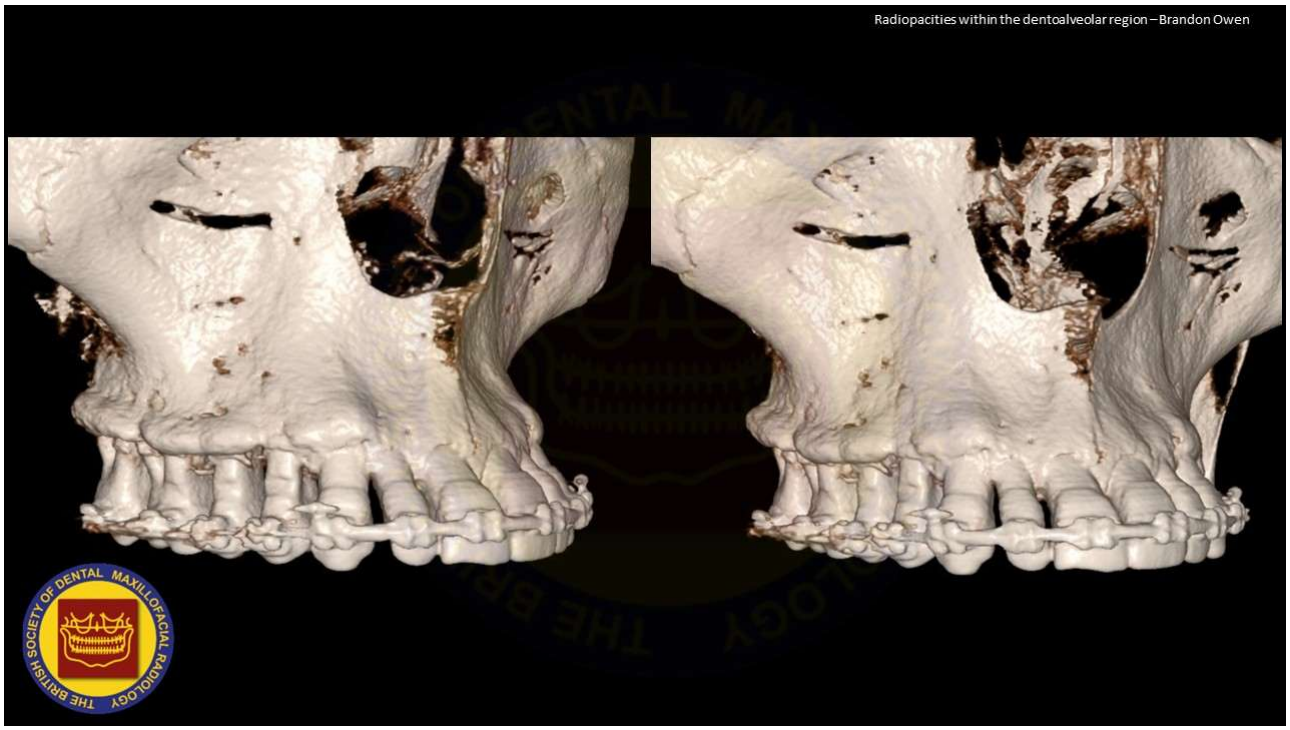
Radiopacities within the dentoalveolar region – Brandon Owen

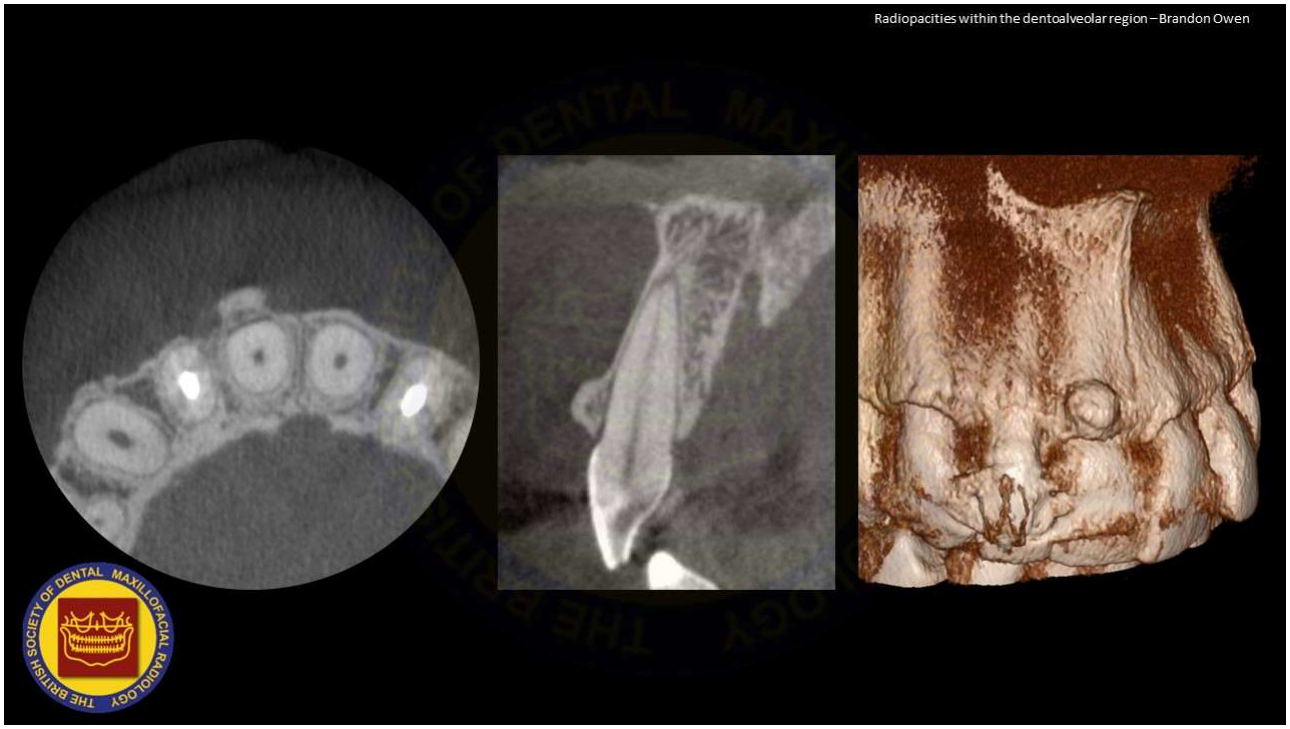
Radiopacities within the dentoalveolar region – Brandon Owen

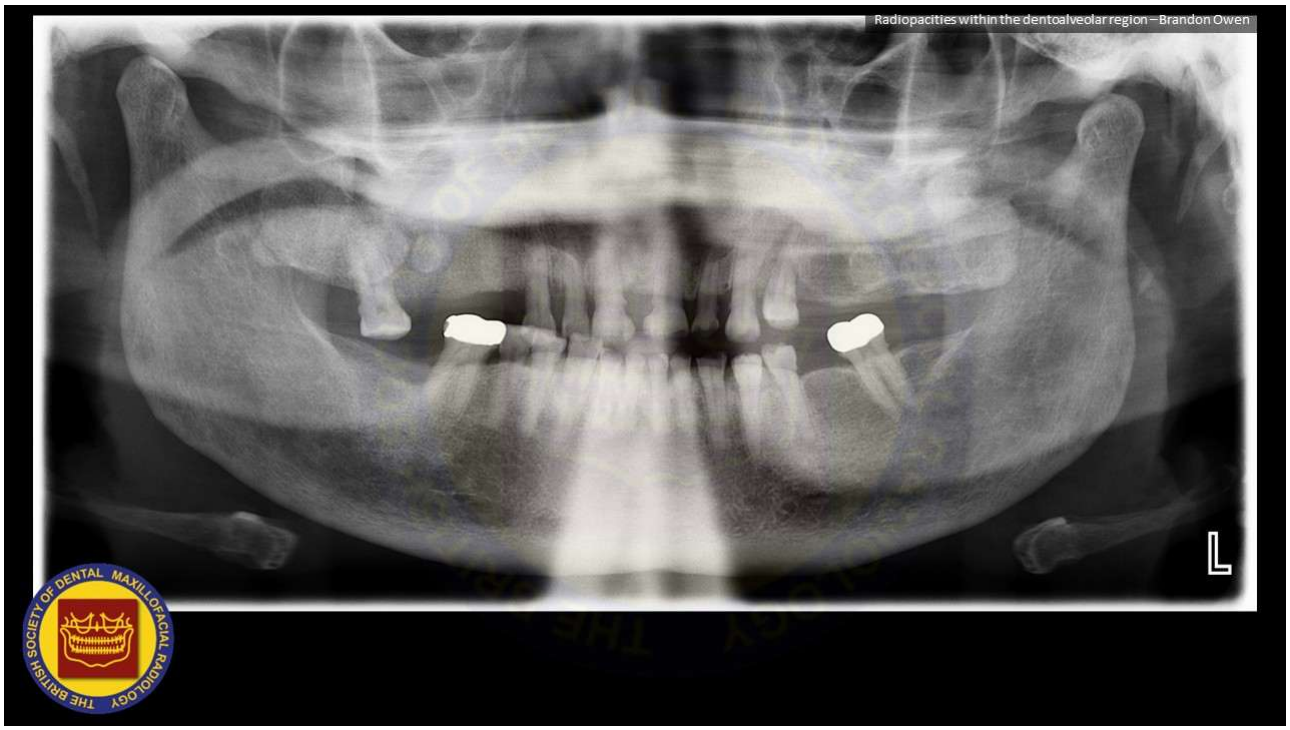
Radiopacities within the dentoalveolar region – Brandon Owen
L

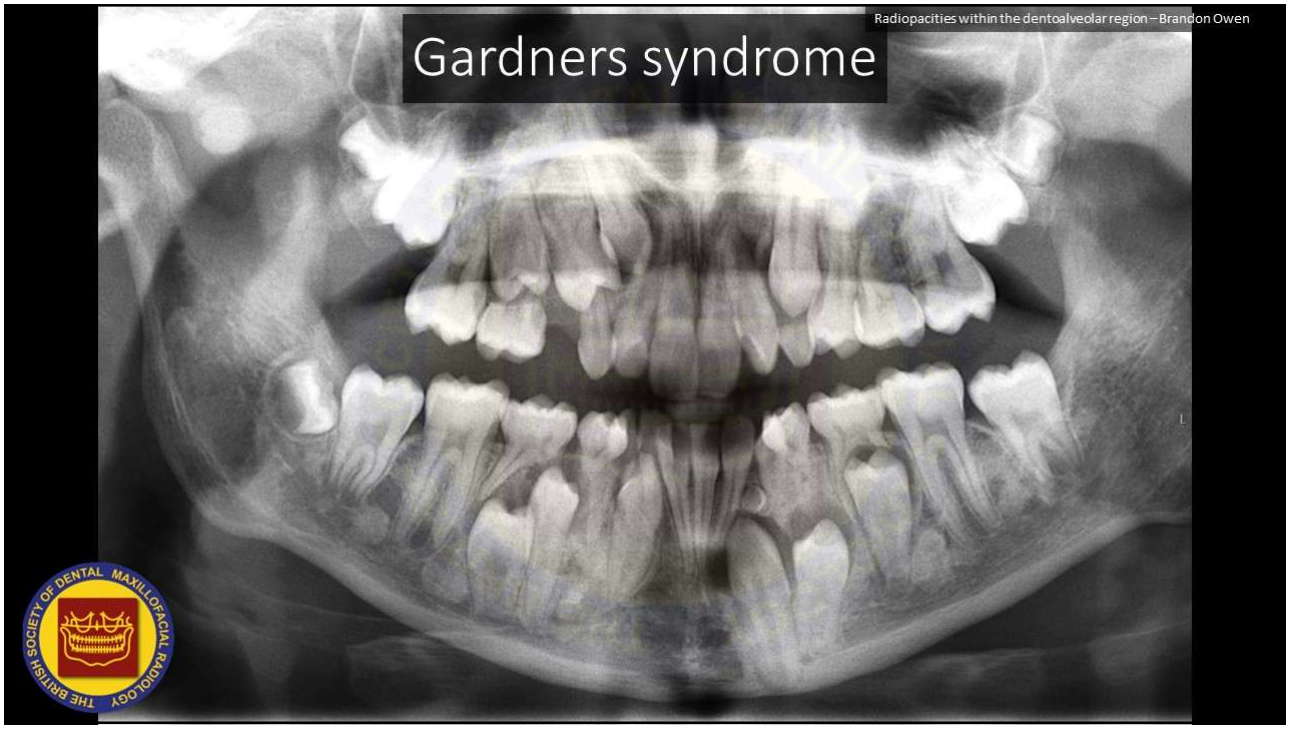
Radiopacities within the dentoalveolar region – Brandon Owen
Gardners syndrome

# Tonsilloliths

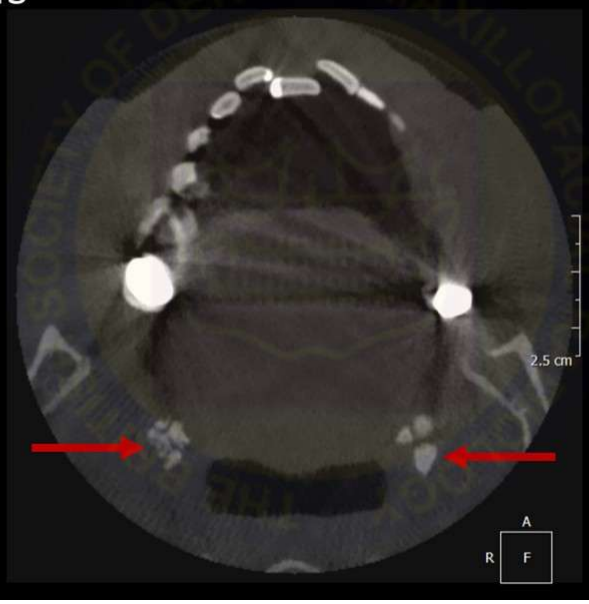


Radiopacities within the dentoalveolar region – Brandon Owen

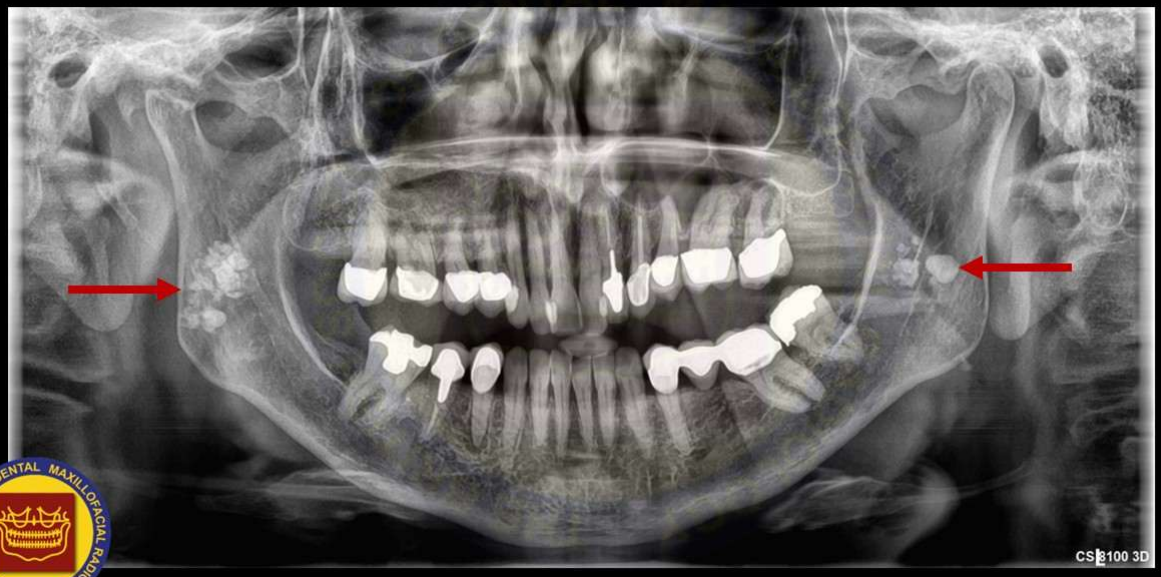

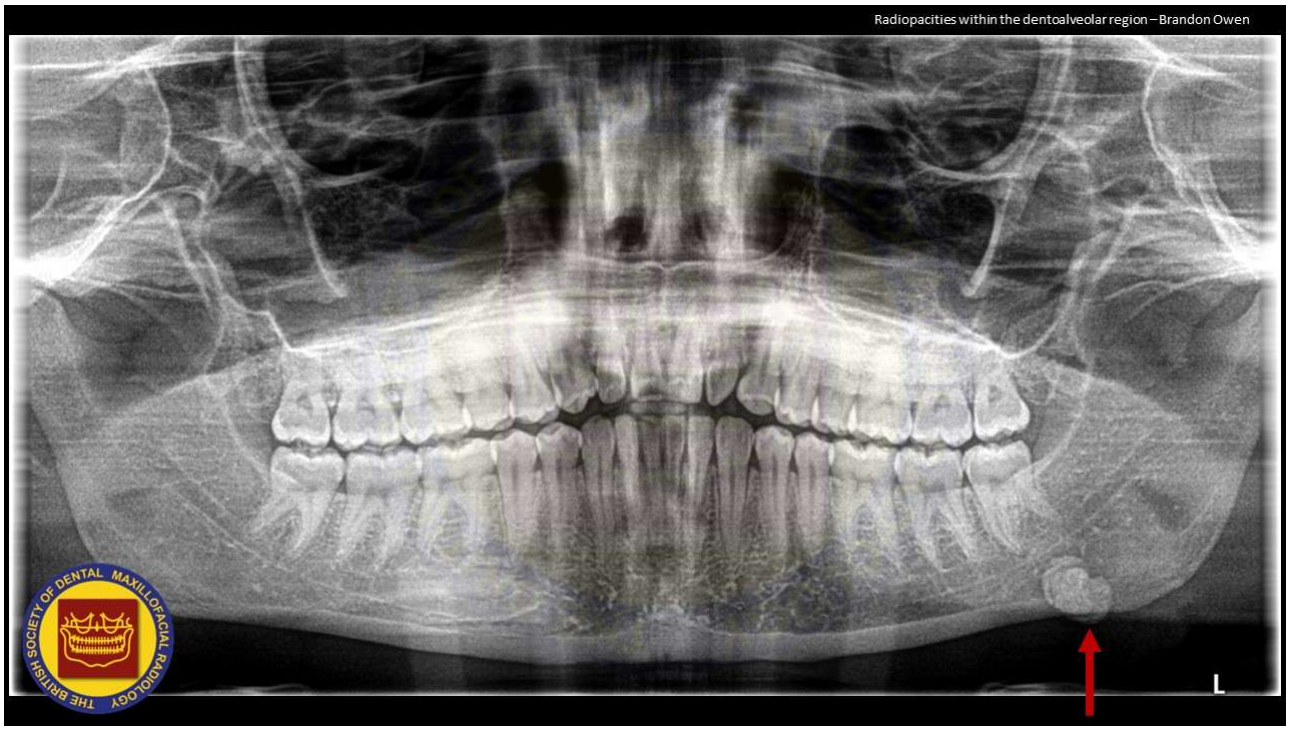
Radiopacities within the dentoalveolar region – Brandon Owen
L

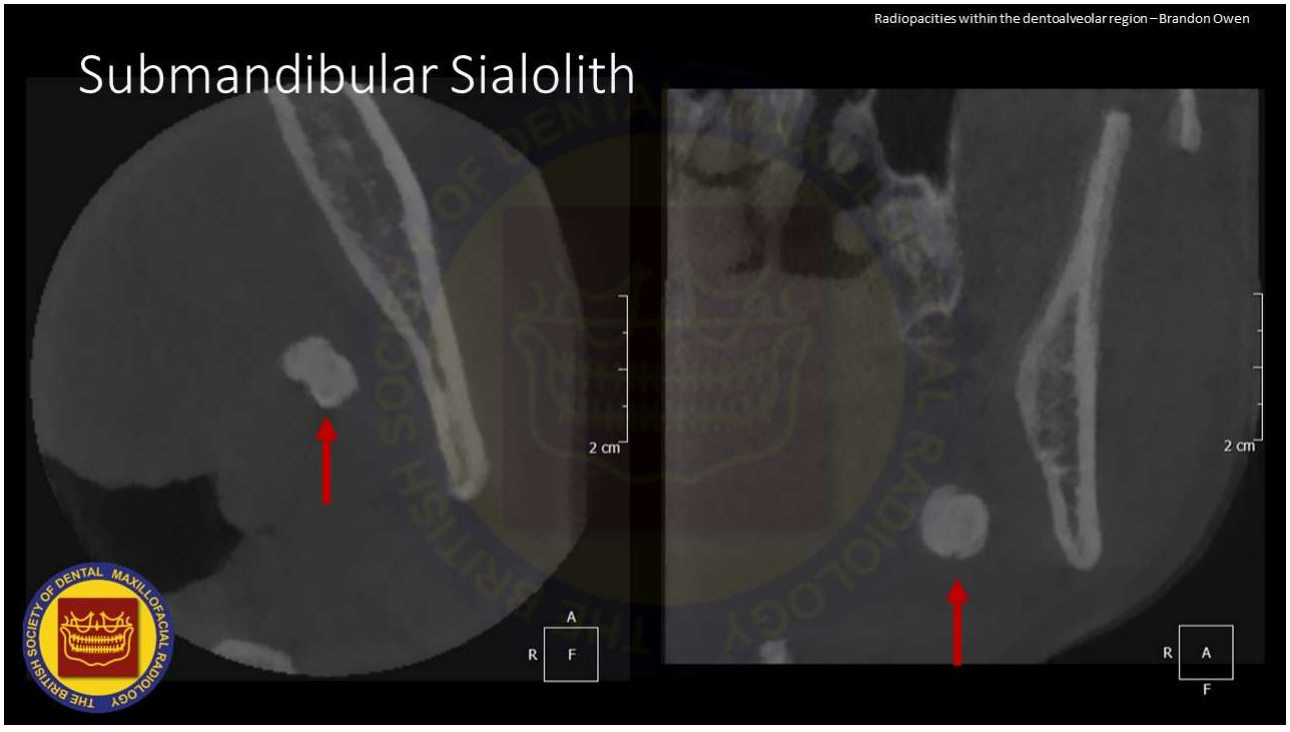
Radiopacities within the dentoalveolar region – Brandon Owen
Submandibular Sialolith
2 cm
2 cm
A
R F
R A
F

# Carotid calcification



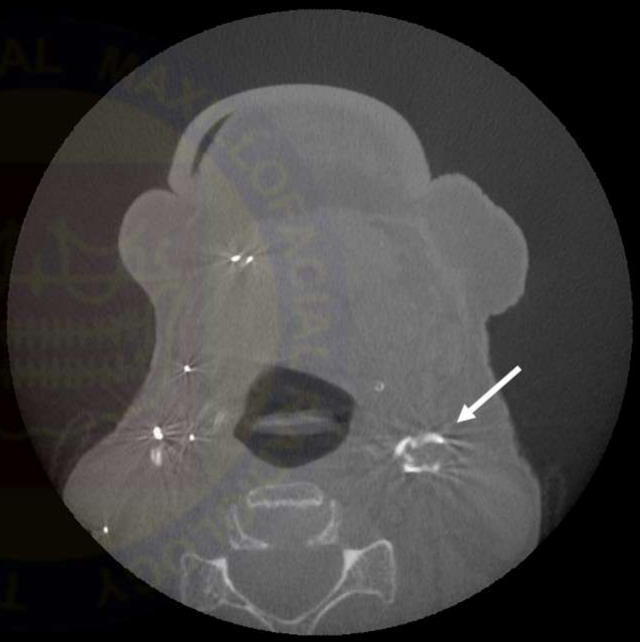

Radiopacities within the dentoalveolar region – Brandon Owen

# Carotid Calcification

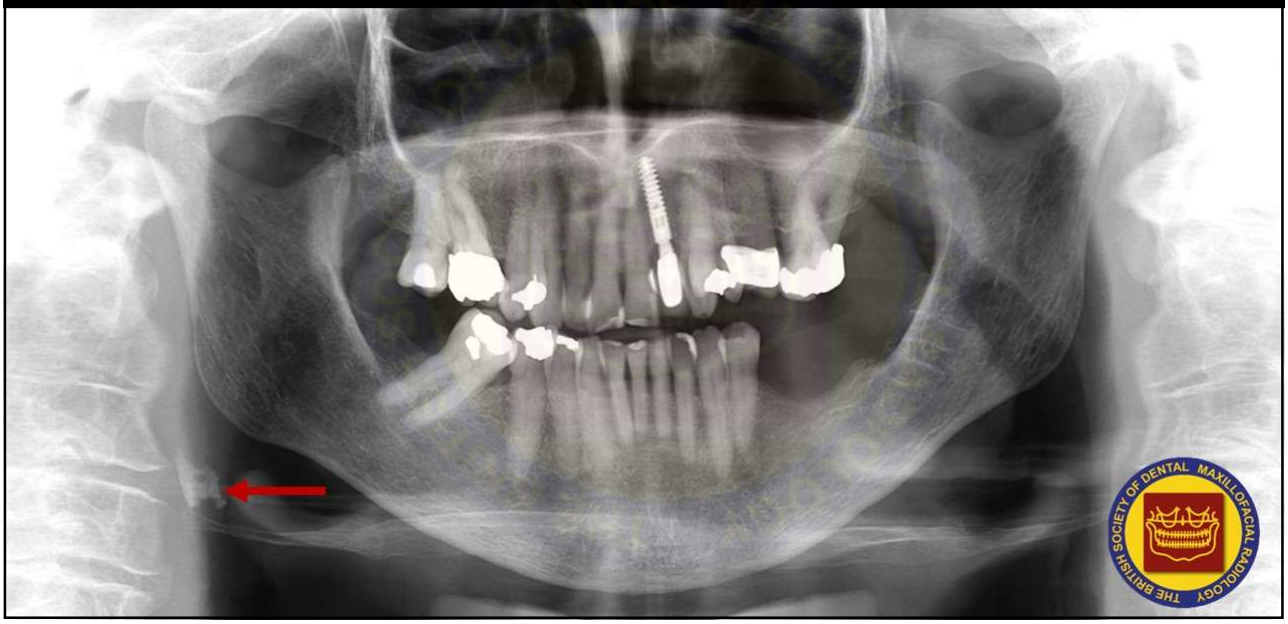

# Facial artery calcification

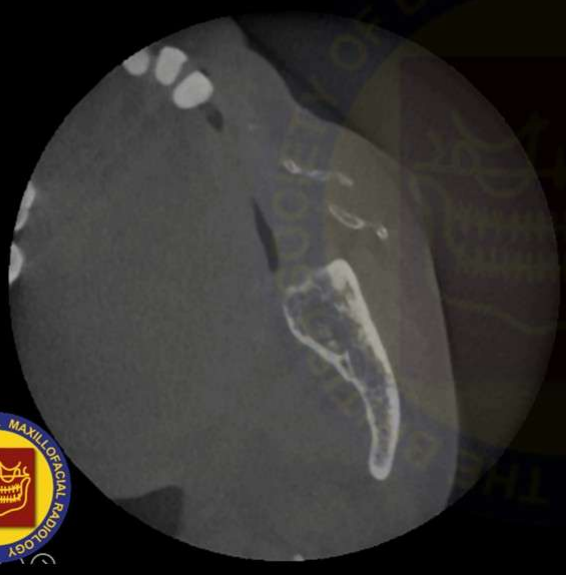



Radiopacities within the dentoalveolar region – Brandon Owen





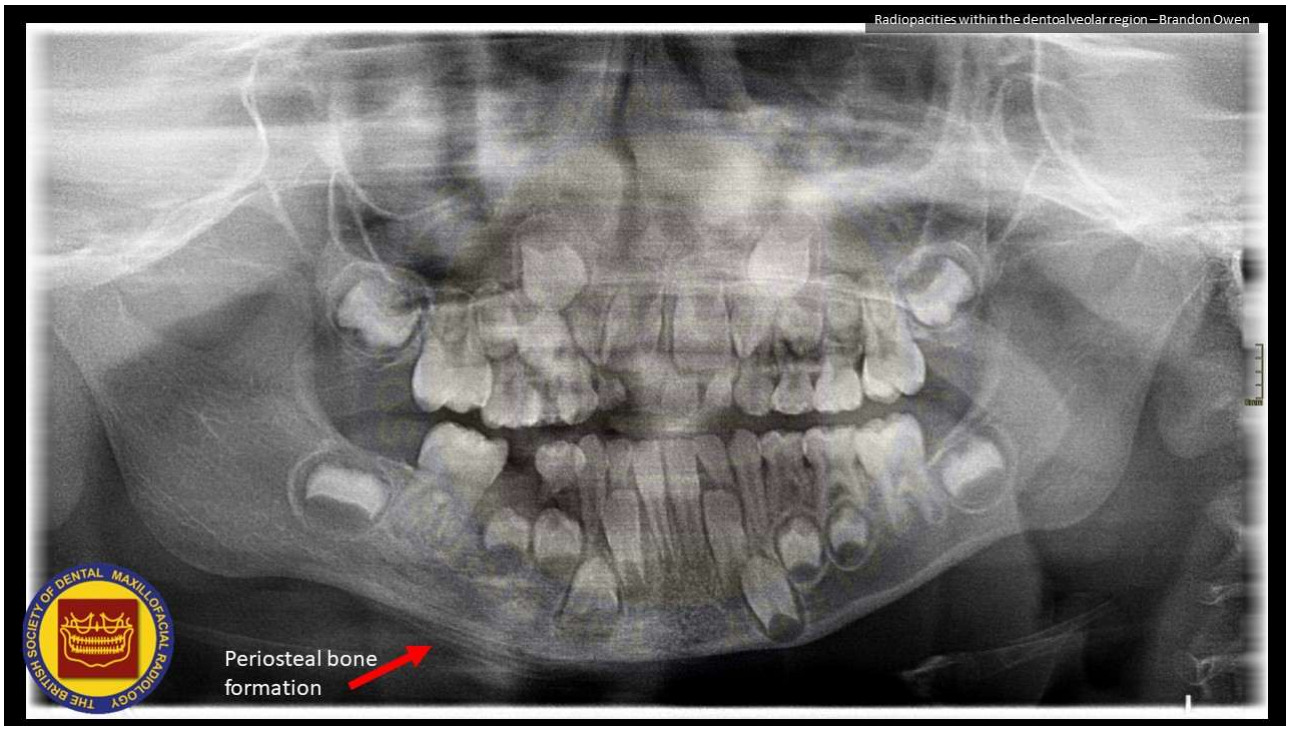
Radiopacities within the dentoalveolar region – Brandon Owen
Periosteal bone formation

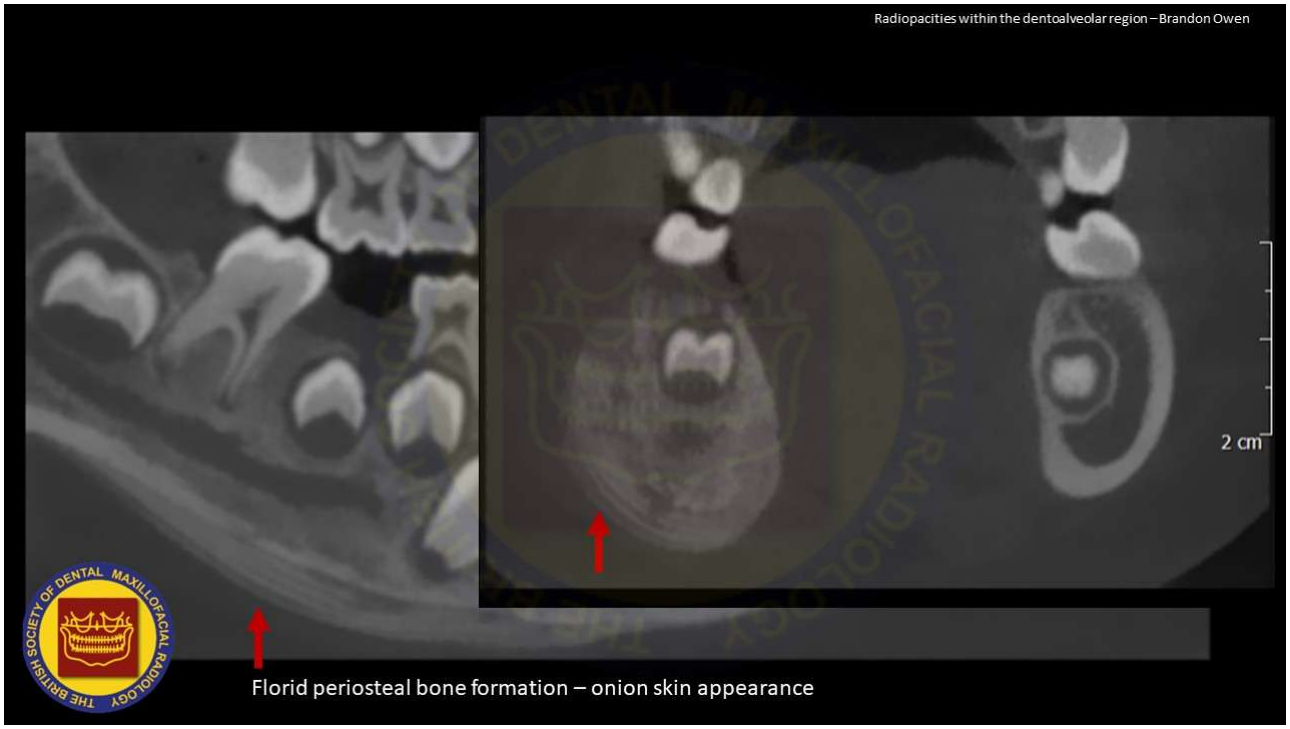
Radiopacities within the dentoalveolar region – Brandon Owen
2 cm
Florid periosteal bone formation – onion skin appearance

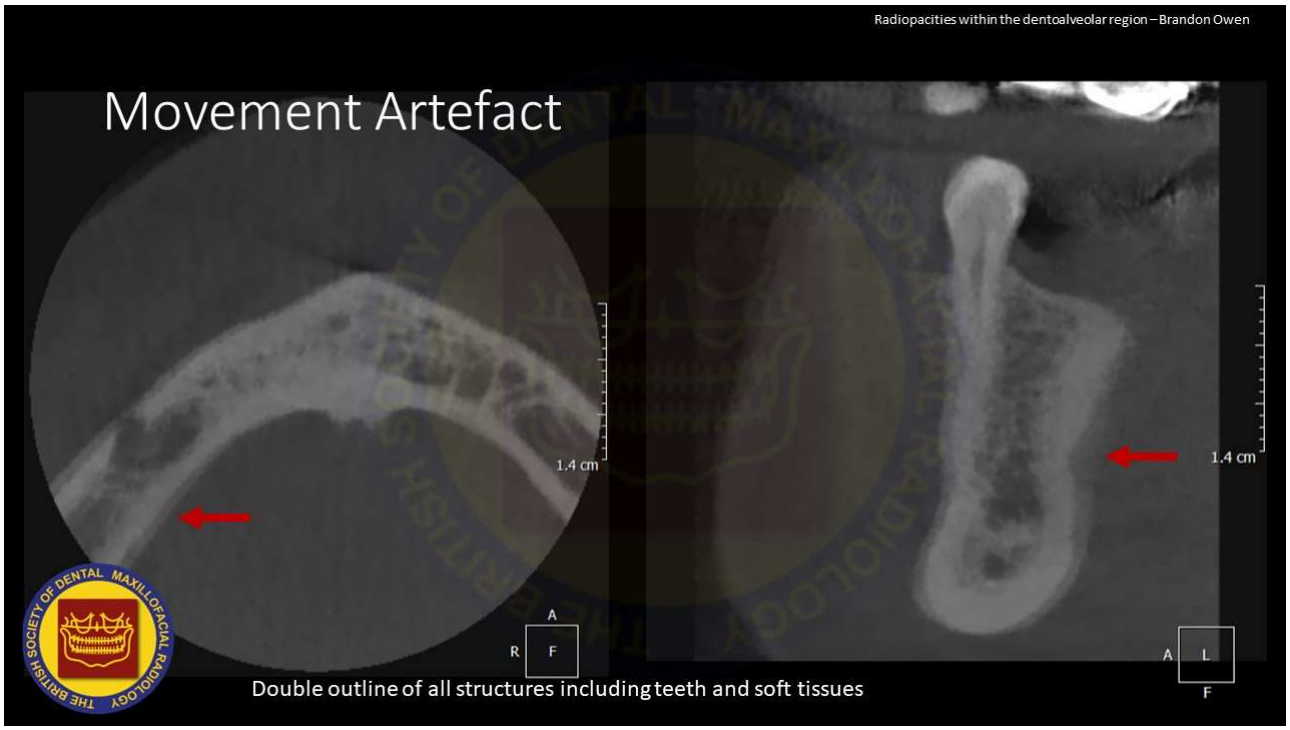
Radiopacities within the dentoalveolar region – Brandon Owen
Movement Artefact
1.4 cm
1.4 cm
A
R F
A L
F
Double outline of all structures including teeth and soft tissues

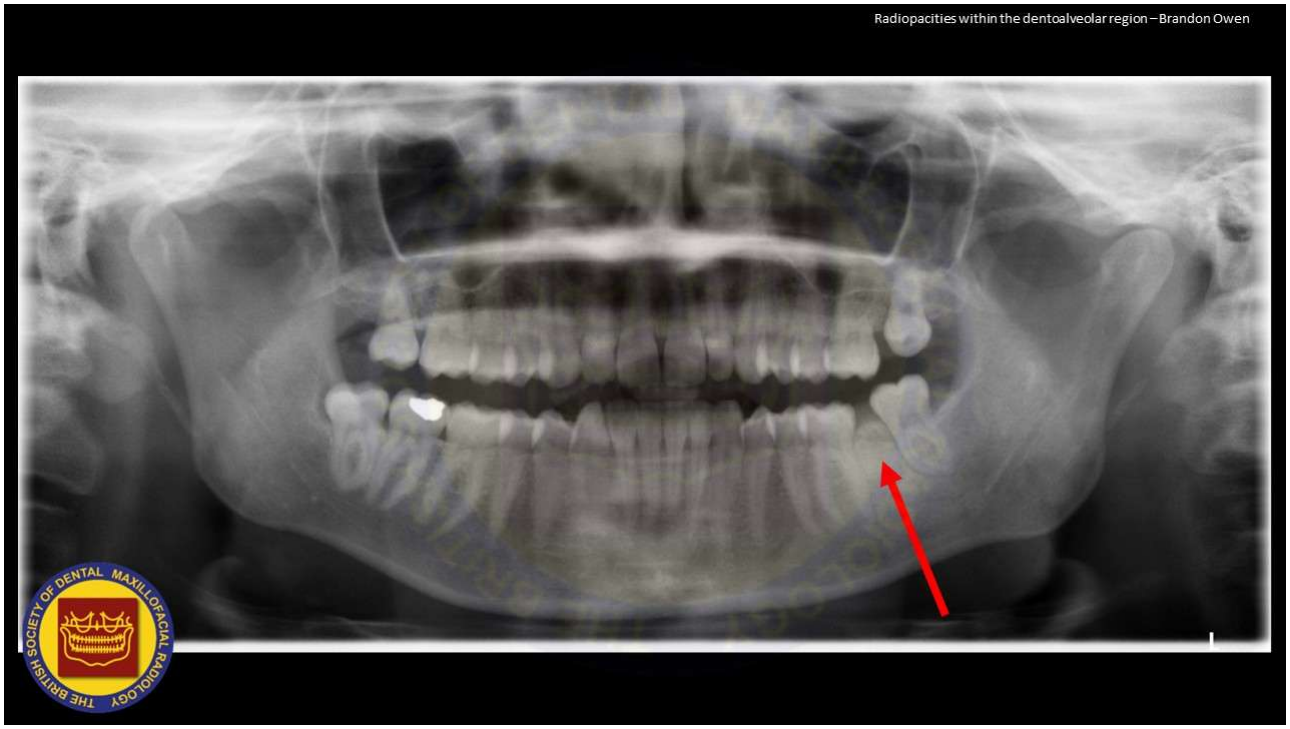
Radiopacities within the dentoalveolar region – Brandon Owen

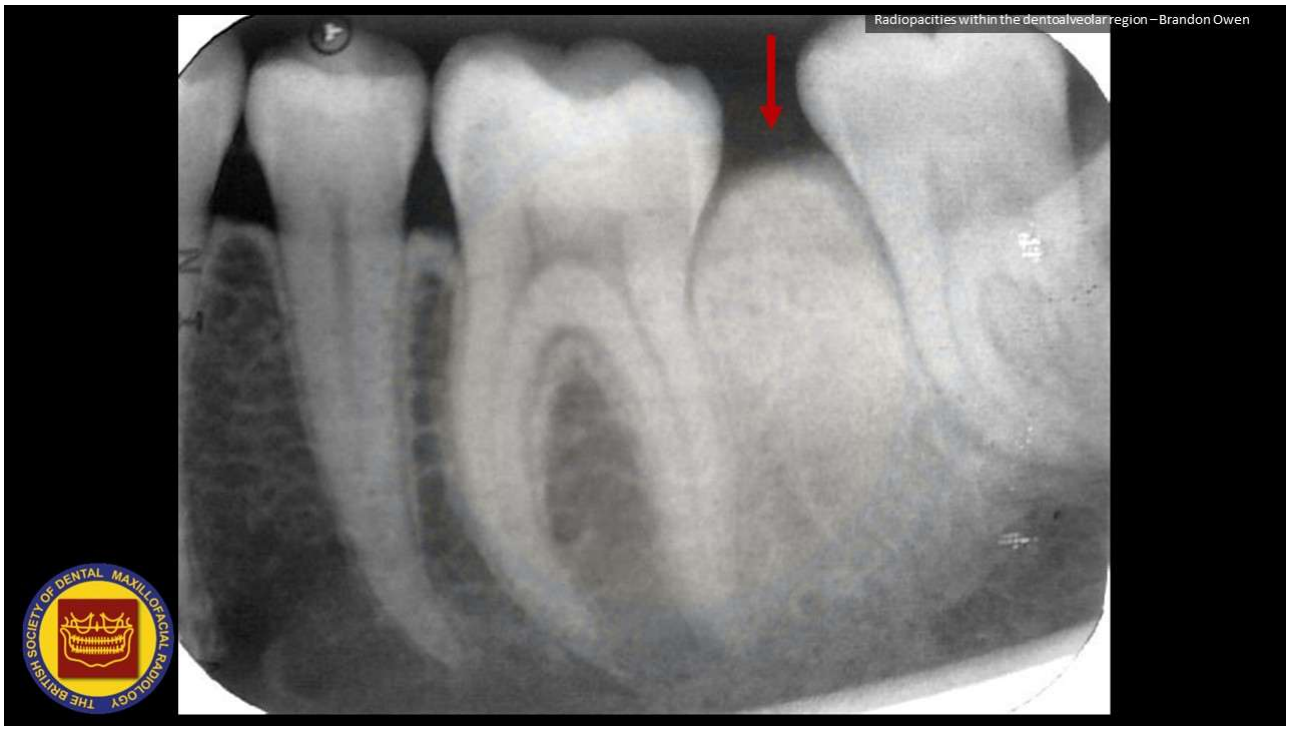
Radiopacities within the dentoalveolar region – Brandon Owen


Radiopacities within the dentoalveolar region – Brandon Owen
Osteosarcoma
1.4 cm
1.4 cm
A
R
F
R
A
F
Sunray spiculation – bone not laid down parallel to cortical surface like with periosteal reaction but instead at perpendicular to cortical surface

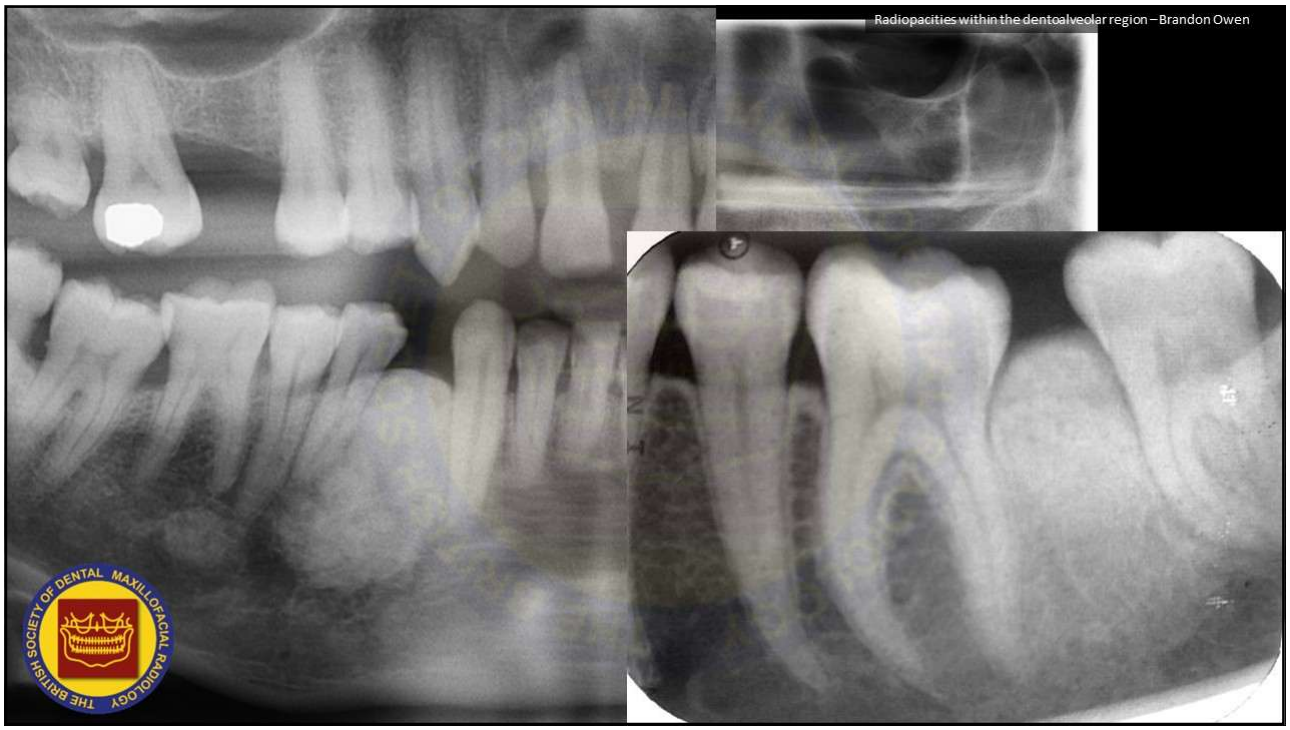
Radiopacities within the dentoalveolar region – Brandon Owen

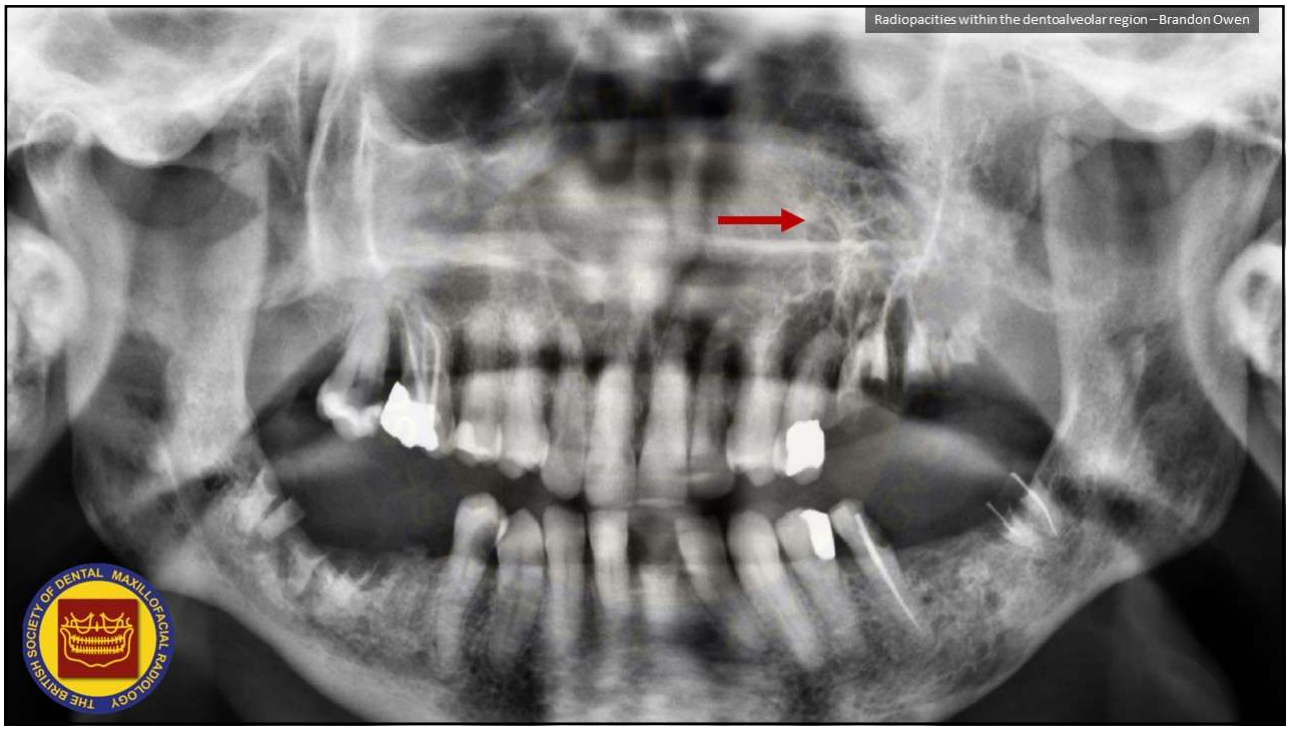
Radiopacities within the dentoalveolar region – Brandon Owen

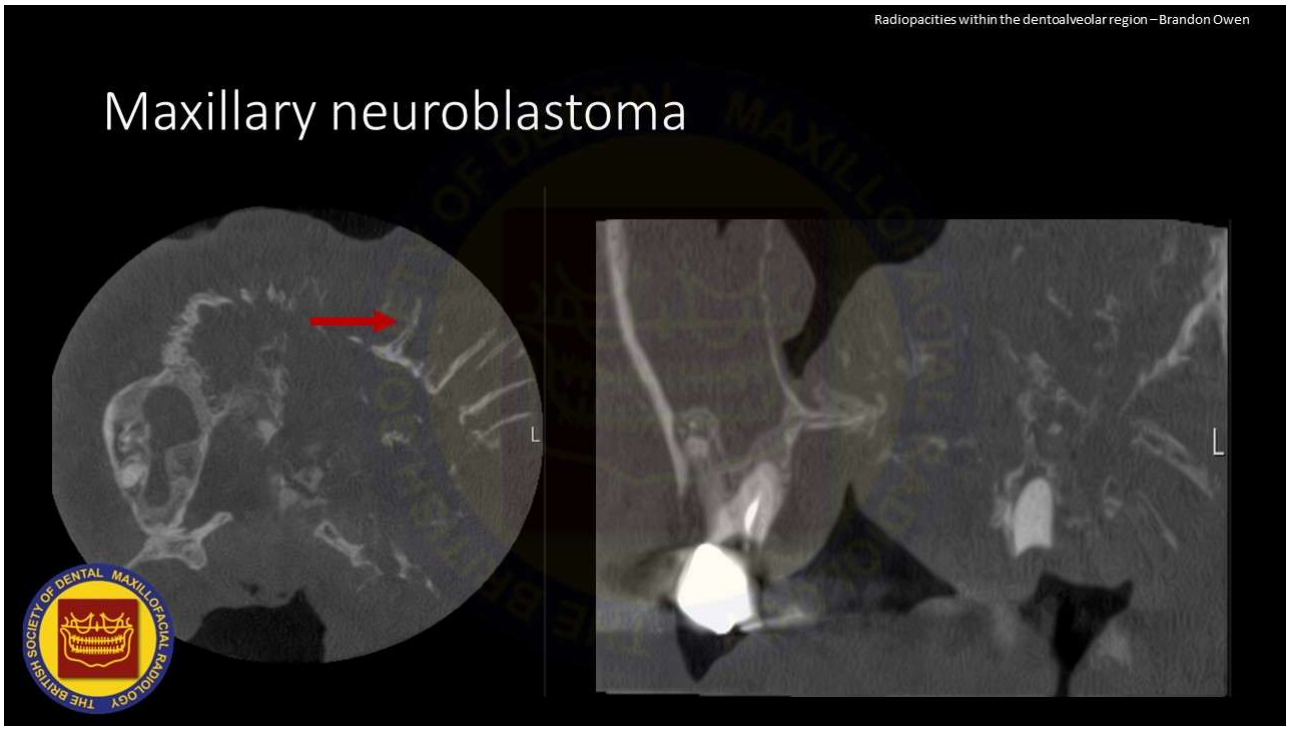
Radiopacities within the dentoalveolar region – Brandon Owen
Maxillary neuroblastoma
L
L
THE BRITISH SOCIETY OF DENTAL MAXILLOFACIAL RADIOLOGY


Radiopacities within the dentoalveolar region – Brandon Owen
L
L
myray
THE BRITISH SOCIETY OF DENTAL MAXILLOFACIAL RADIOLOGY

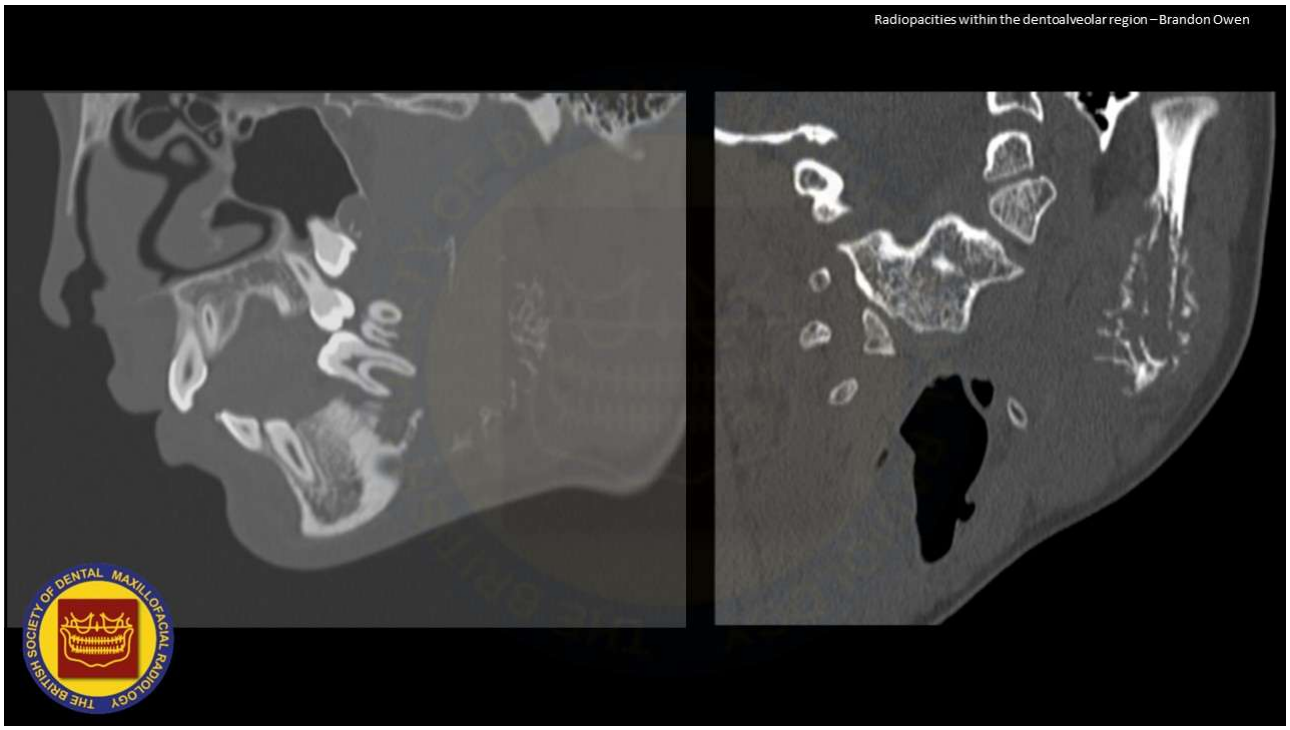
Radiopacities within the dentoalveolar region – Brandon Owen

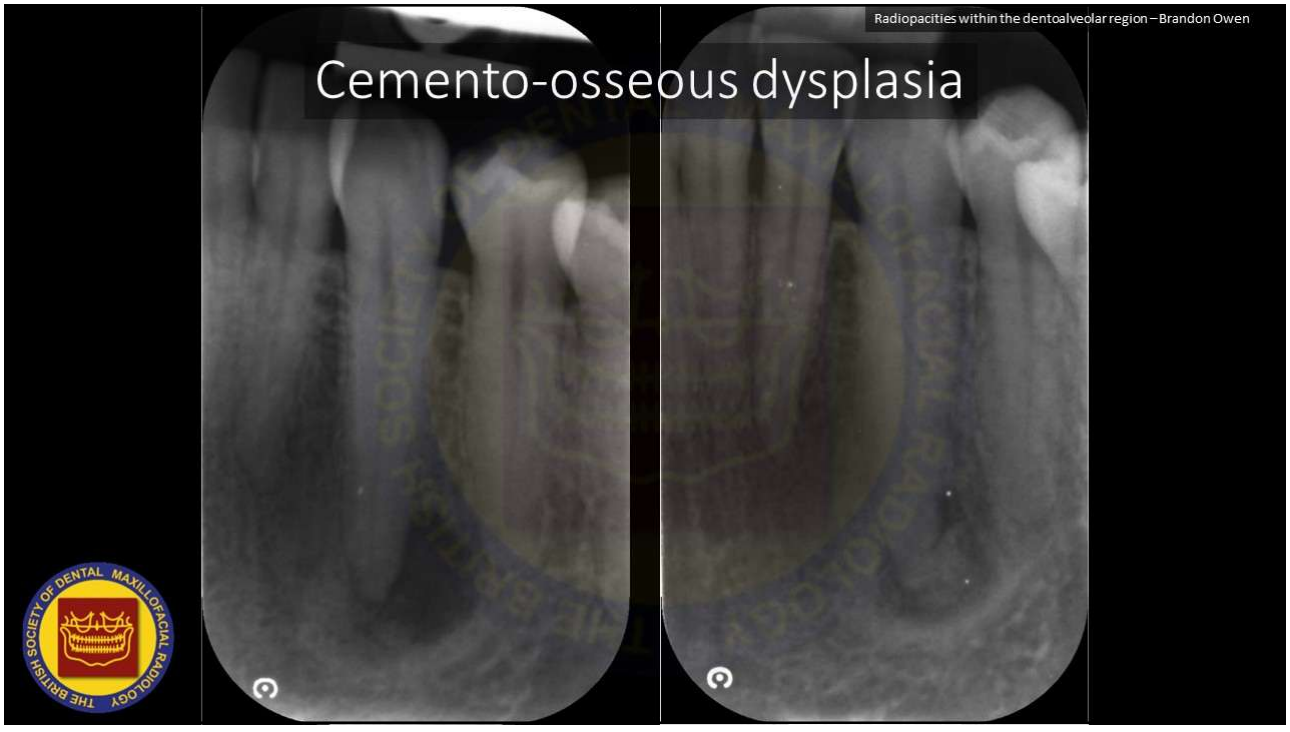
Radiopacities within the dentoalveolar region – Brandon Owen
Cemento-osseous dysplasia

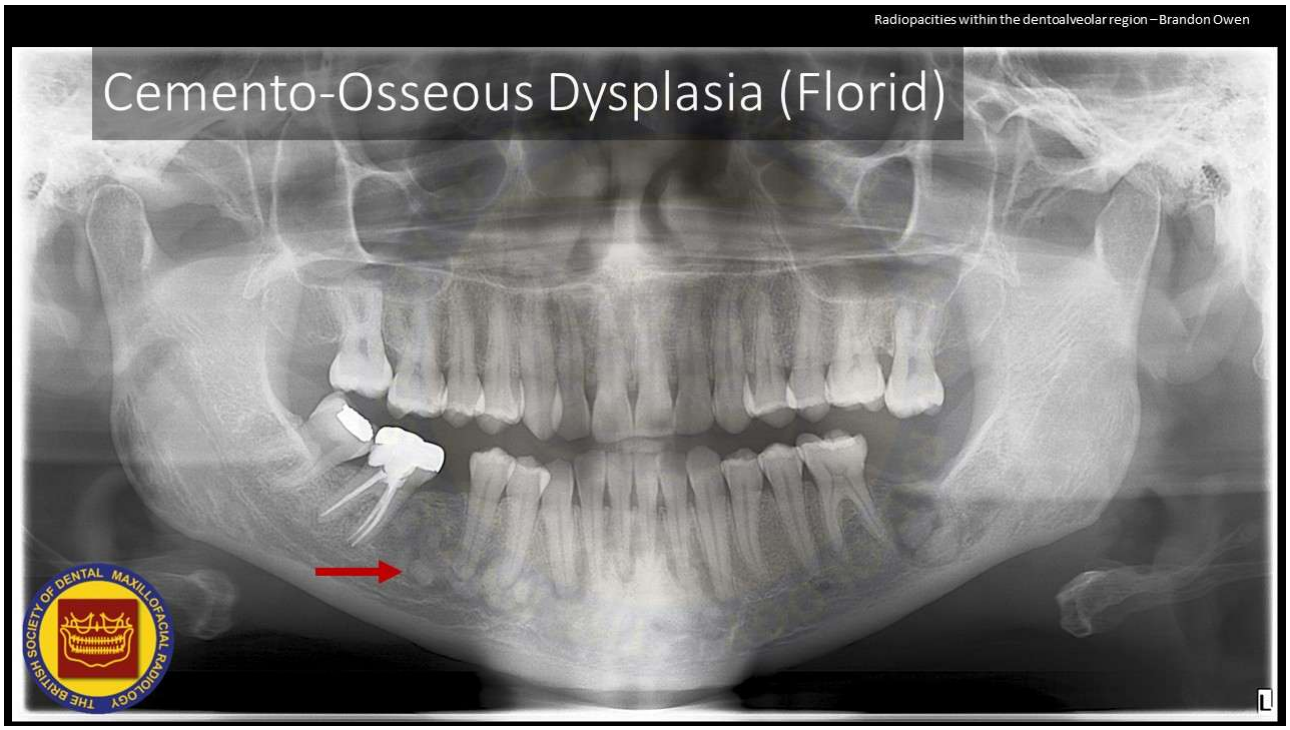
Radiopacities within the dentoalveolar region – Brandon Owen
Cemento-Osseous Dysplasia (Florid)
THE BRITISH SOCIETY OF DENTAL MAXILLOFACIAL RADIOLOGY
L

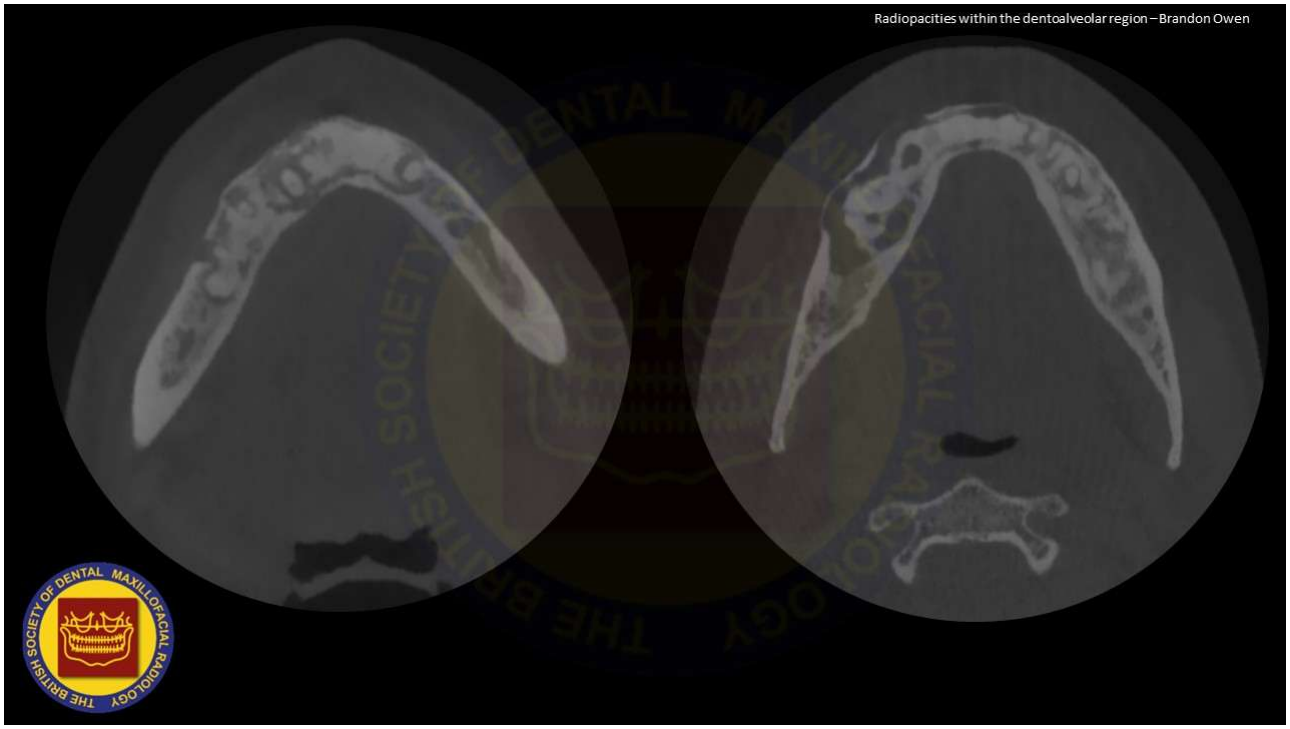
Radiopacities within the dentoalveolar region – Brandon Owen
THE BRITISH SOCIETY OF DENTAL MAXILLOFACIAL RADIOLOGY

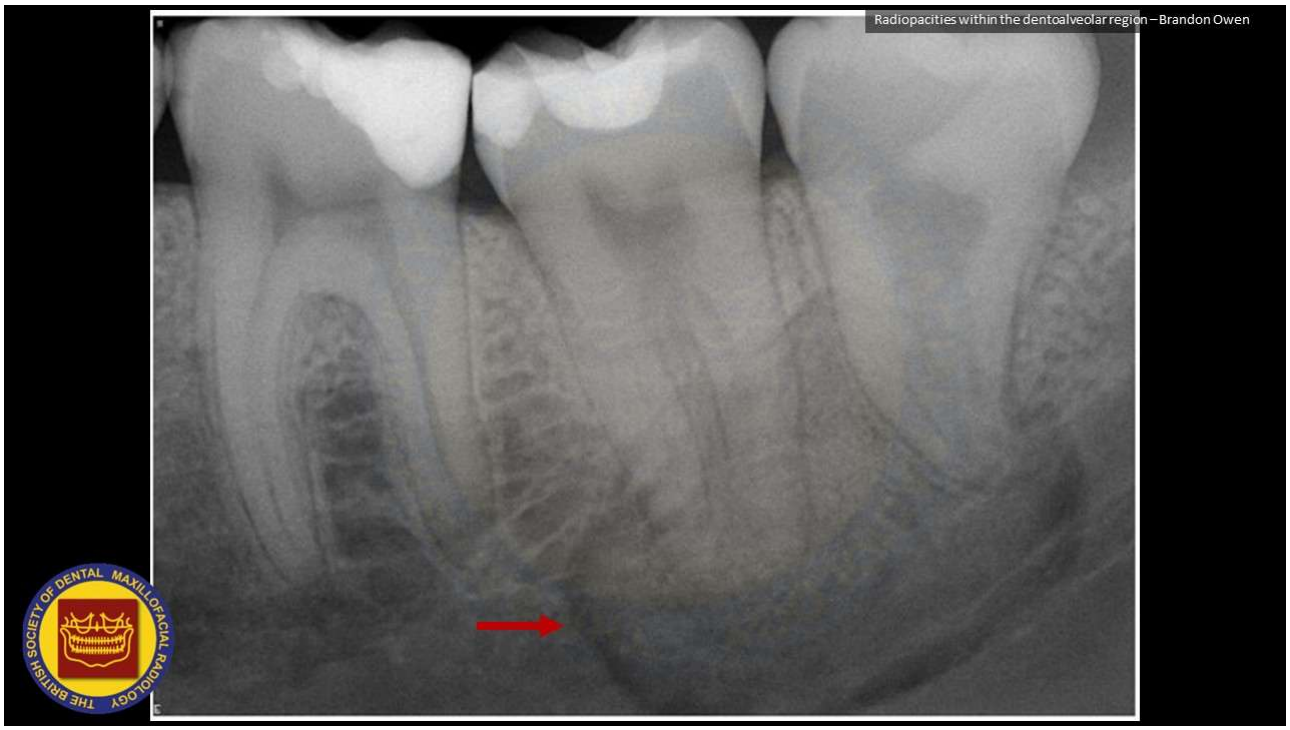
Radiopacities within the dentoalveolar region – Brandon Owen

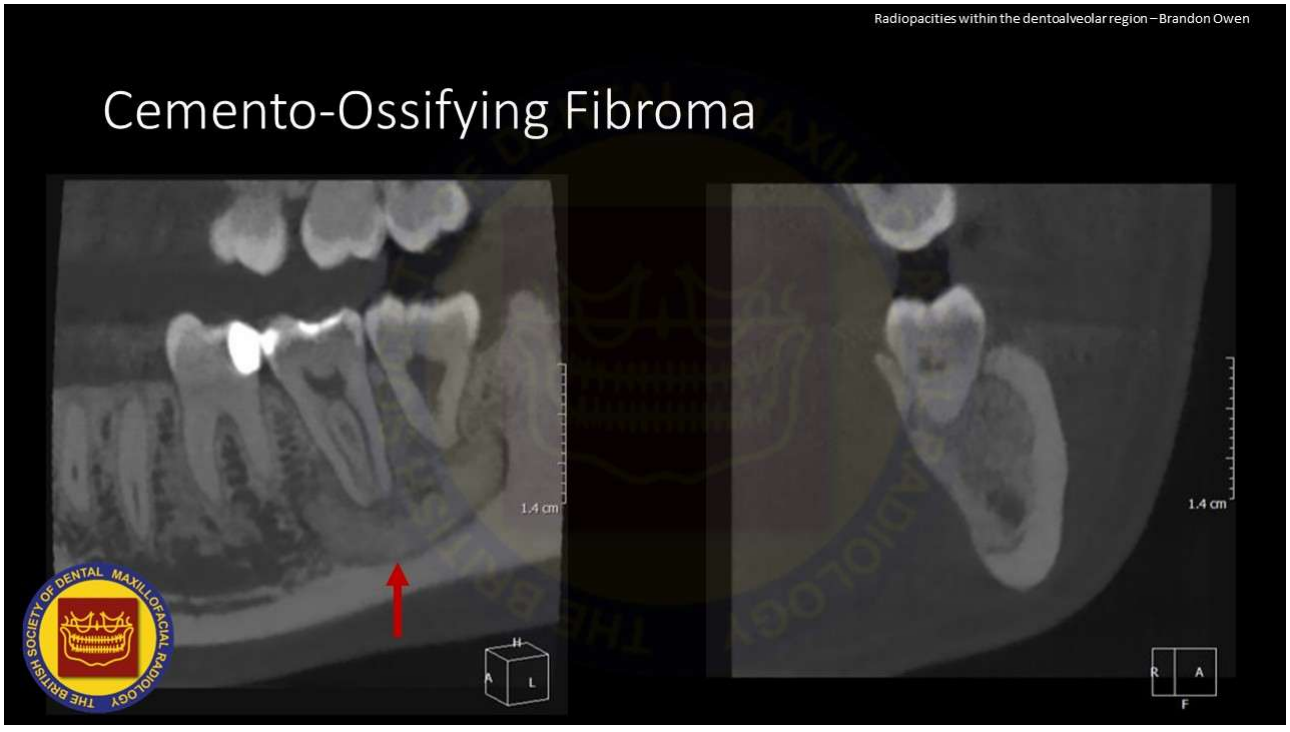
Radiopacities within the dentoalveolar region – Brandon Owen
Cemento-Ossifying Fibroma
1.4 cm
1.4 cm


Radiopacities within the dentoalveolar region – Brandon Owen
THE BRITISH SOCIETY OF DENTAL MAXILLOFACIAL RADIOLOGY
L
myray

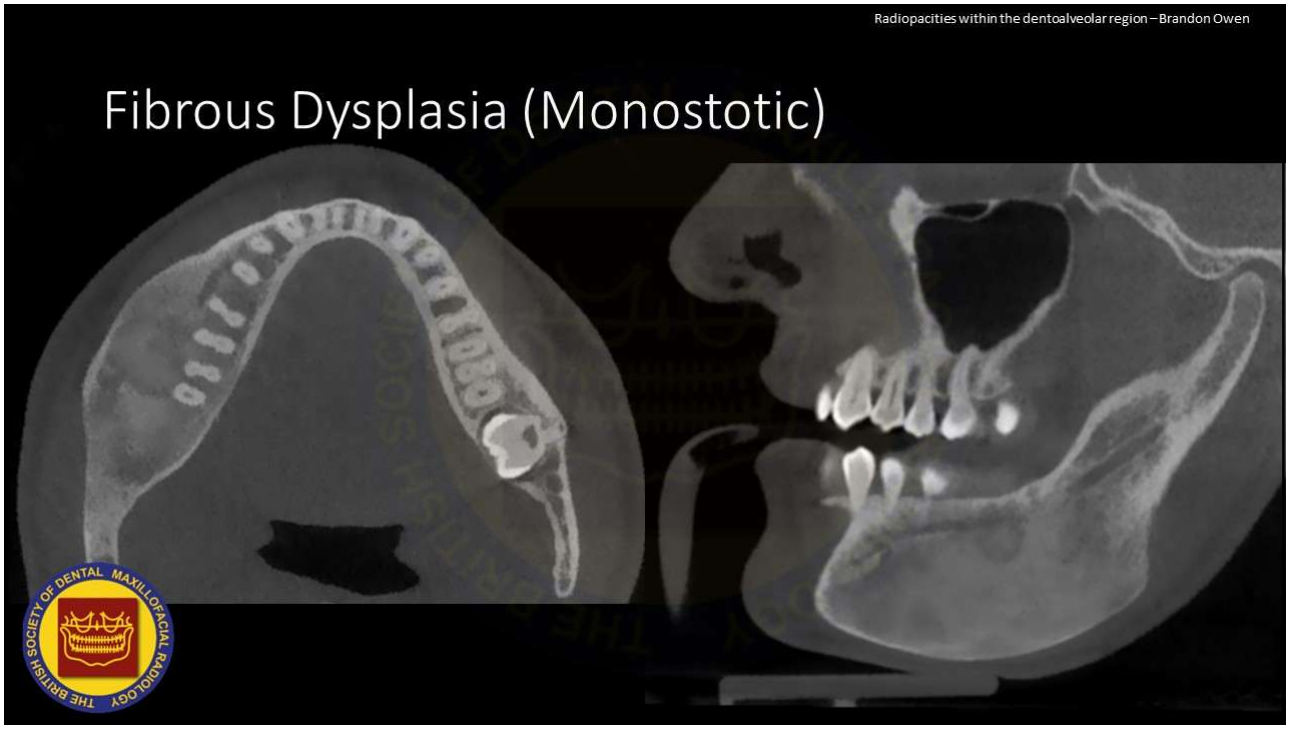
Radiopacities within the dentoalveolar region – Brandon Owen
Fibrous Dysplasia (Monostotic)
THE BRITISH SOCIETY OF DENTAL MAXILLOFACIAL RADIOLOGY

# Fibrous Dysplasia (Craniofacial)

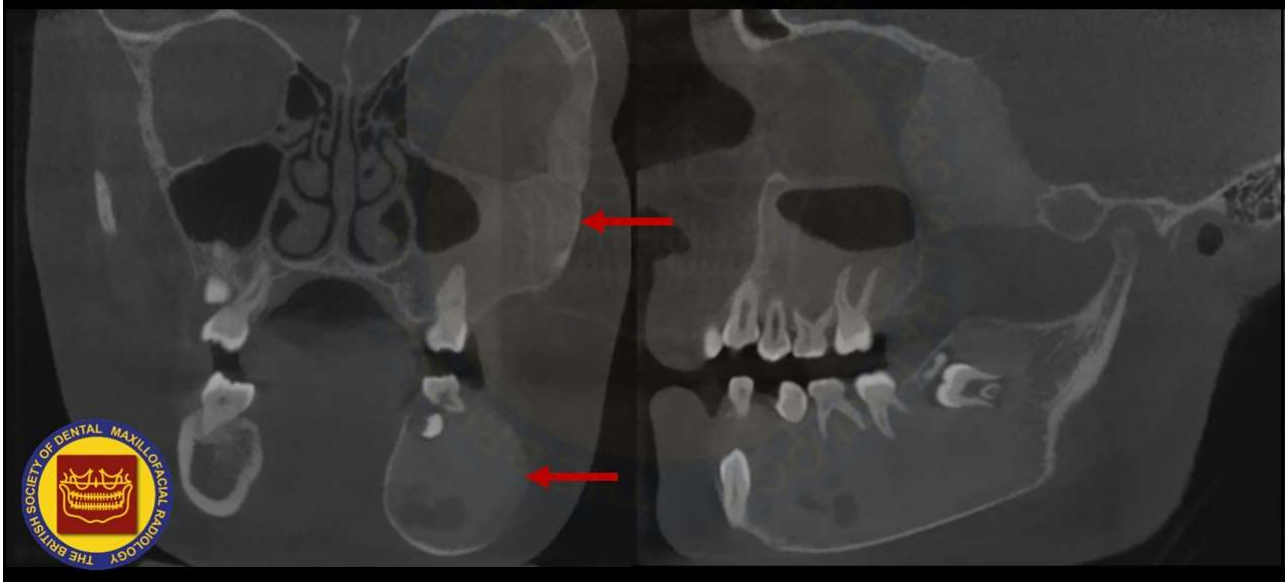



# Graft material

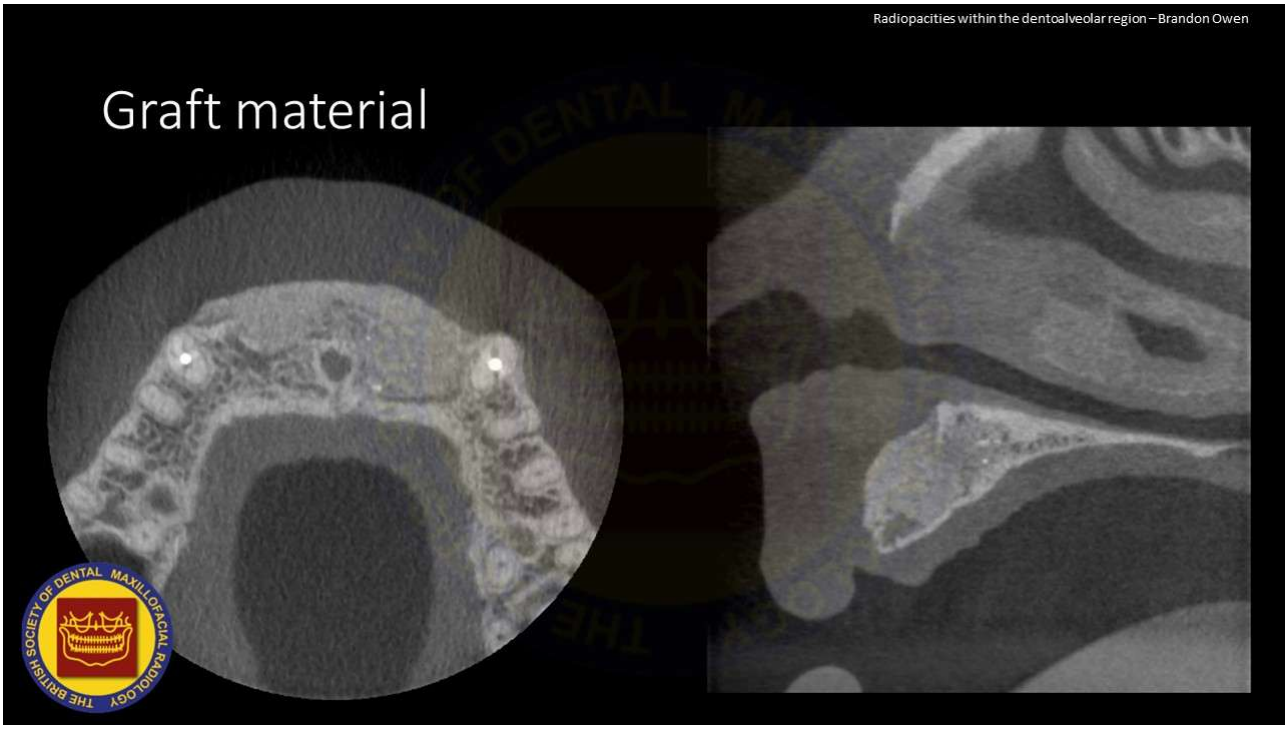

# Impacted canine extraction site

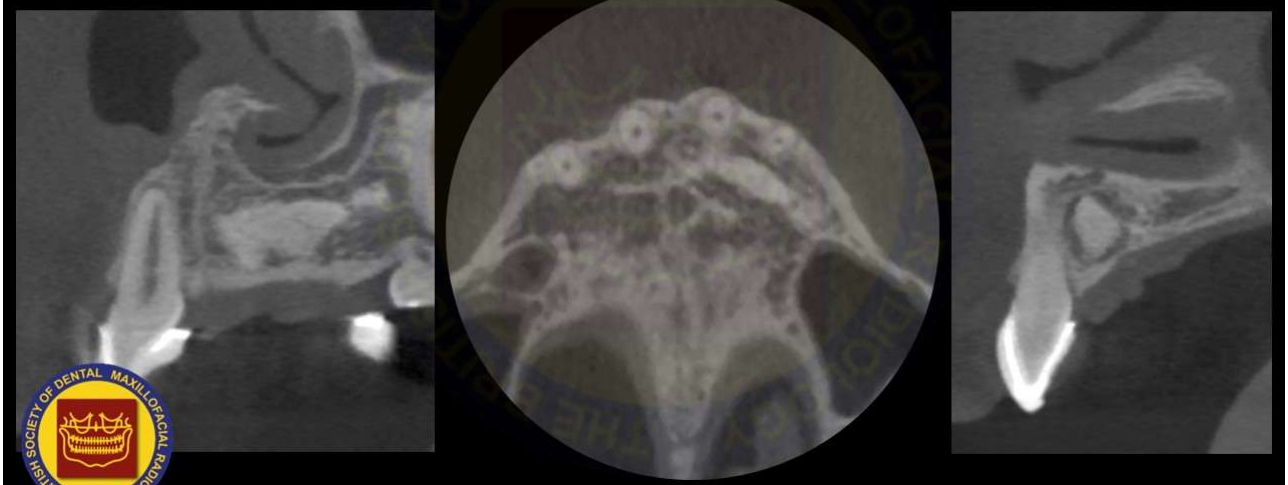





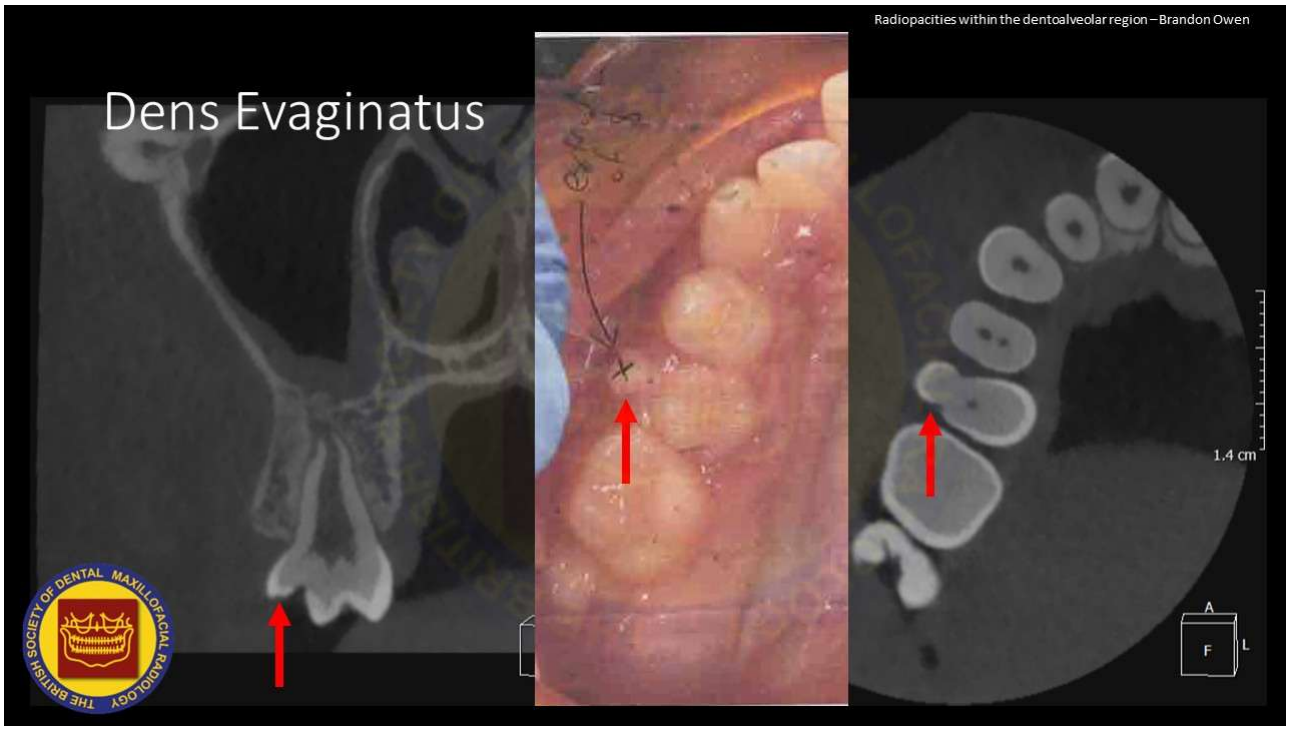
Radiopacities within the dentoalveolar region – Brandon Owen
Dens Evaginatus
1.4 cm
A
F
L

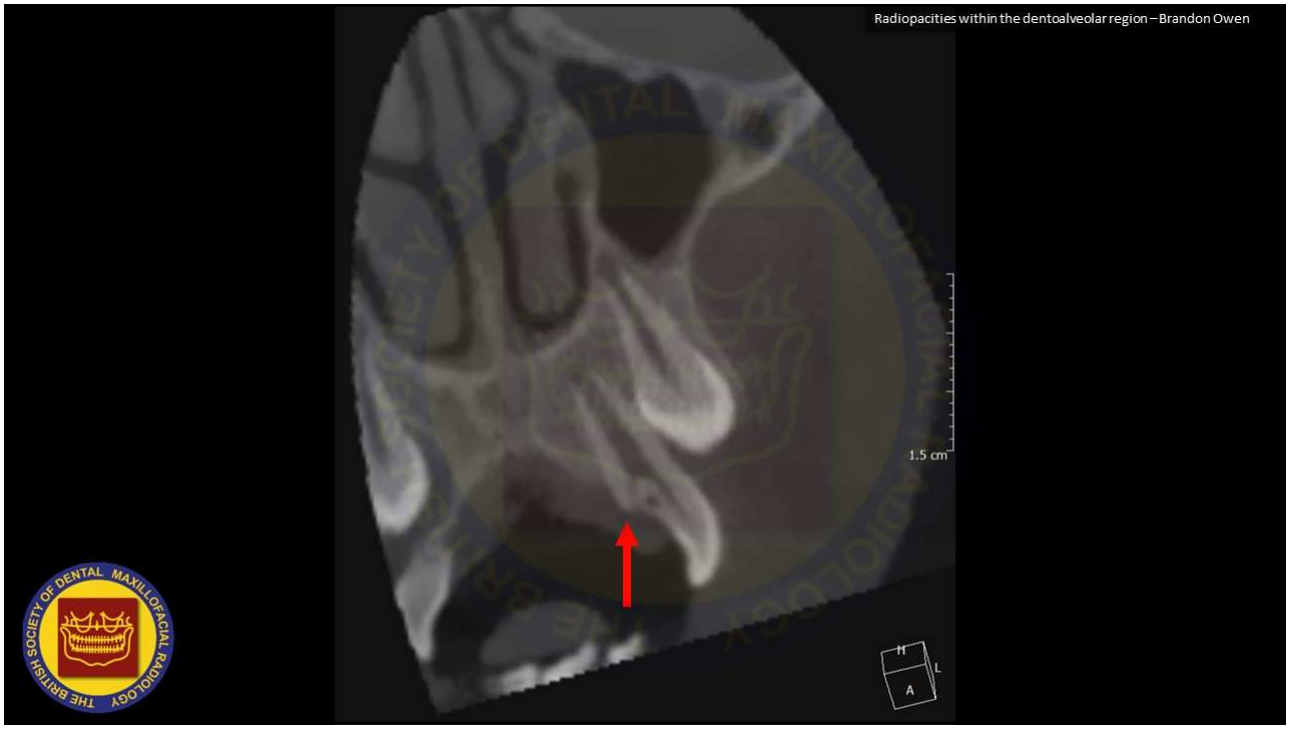
Radiopacities within the dentoalveolar region – Brandon Owen
1.5 cm
H
A
L

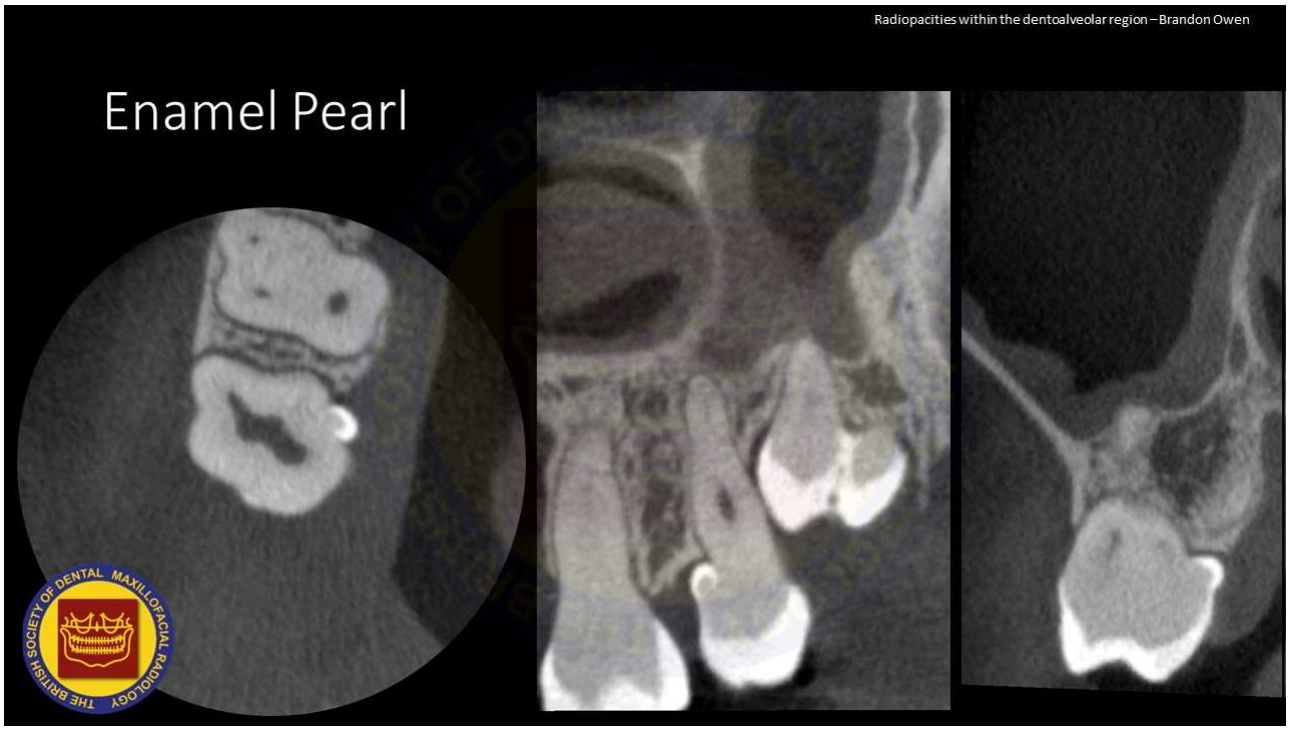
Radiopacities within the dentoalveolar region – Brandon Owen
Enamel Pearl


Radiopacities within the dentoalveolar region – Brandon Owen

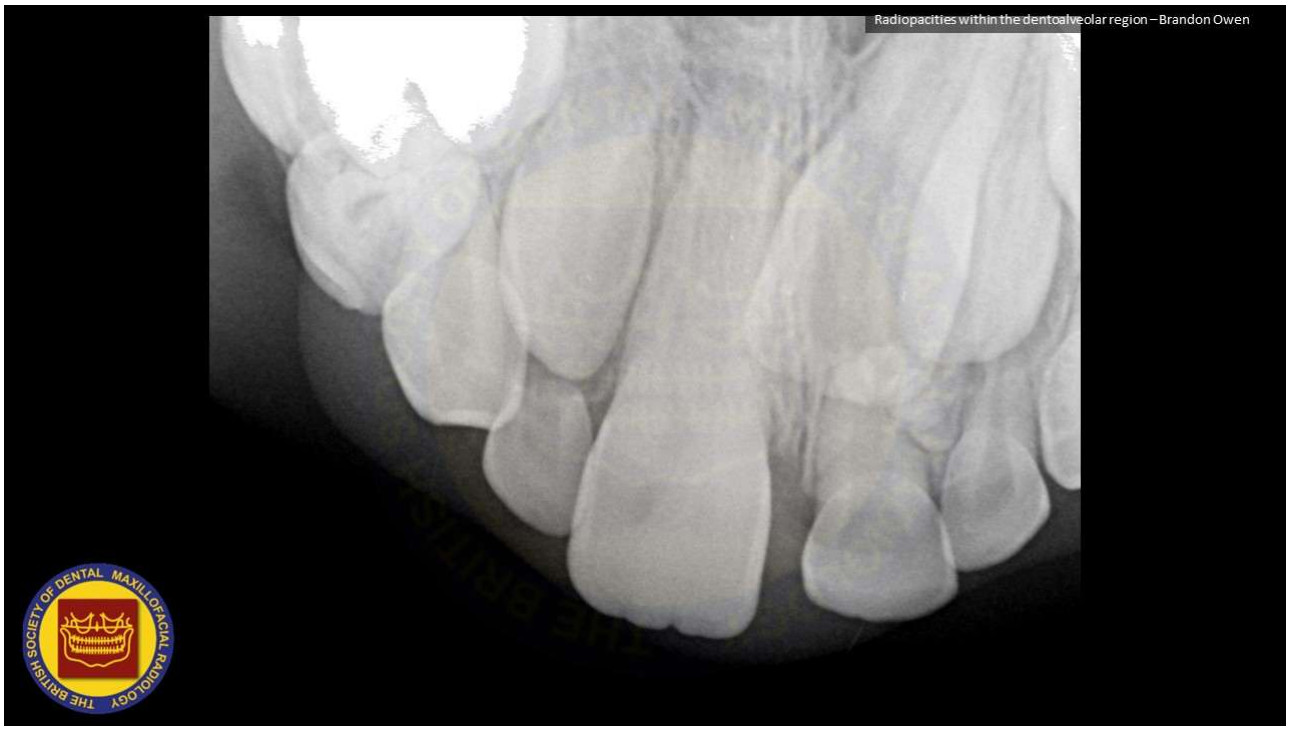
Radiopacities within the dentoalveolar region – Brandon Owen

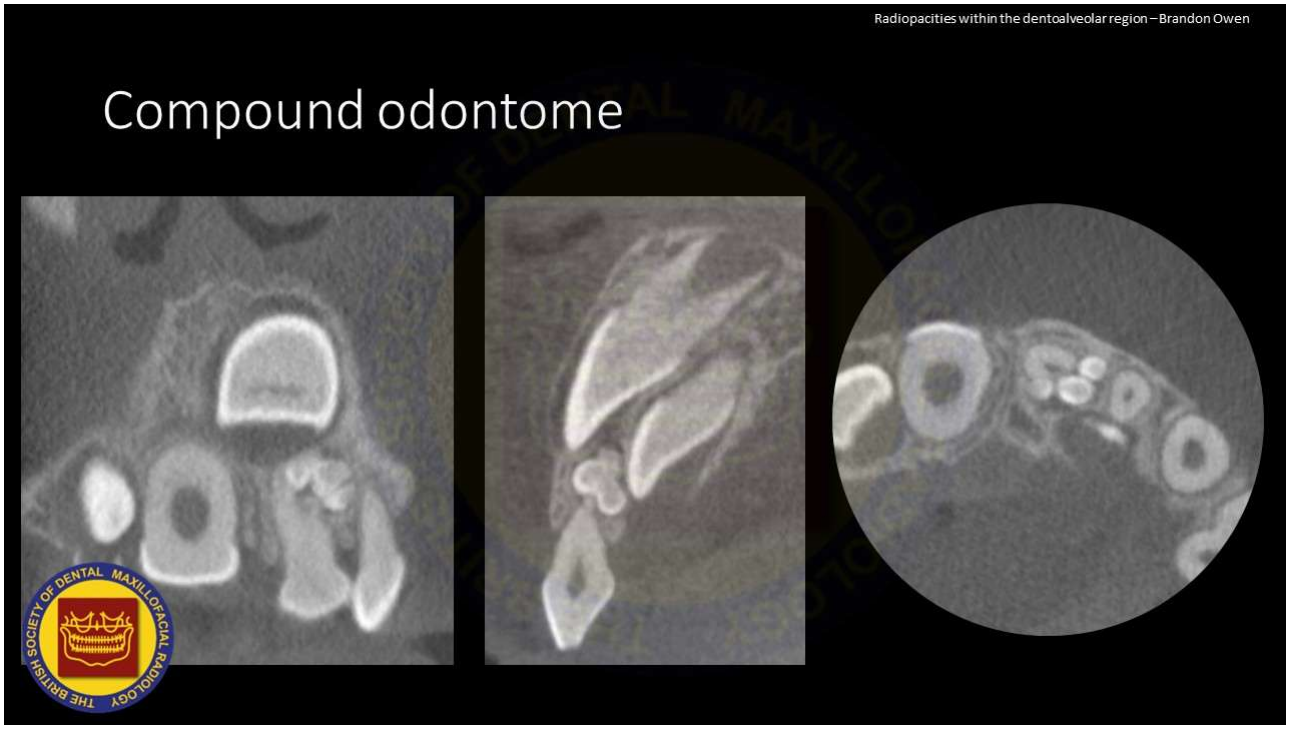
Radiopacities within the dentoalveolar region – Brandon Owen
Compound odontome

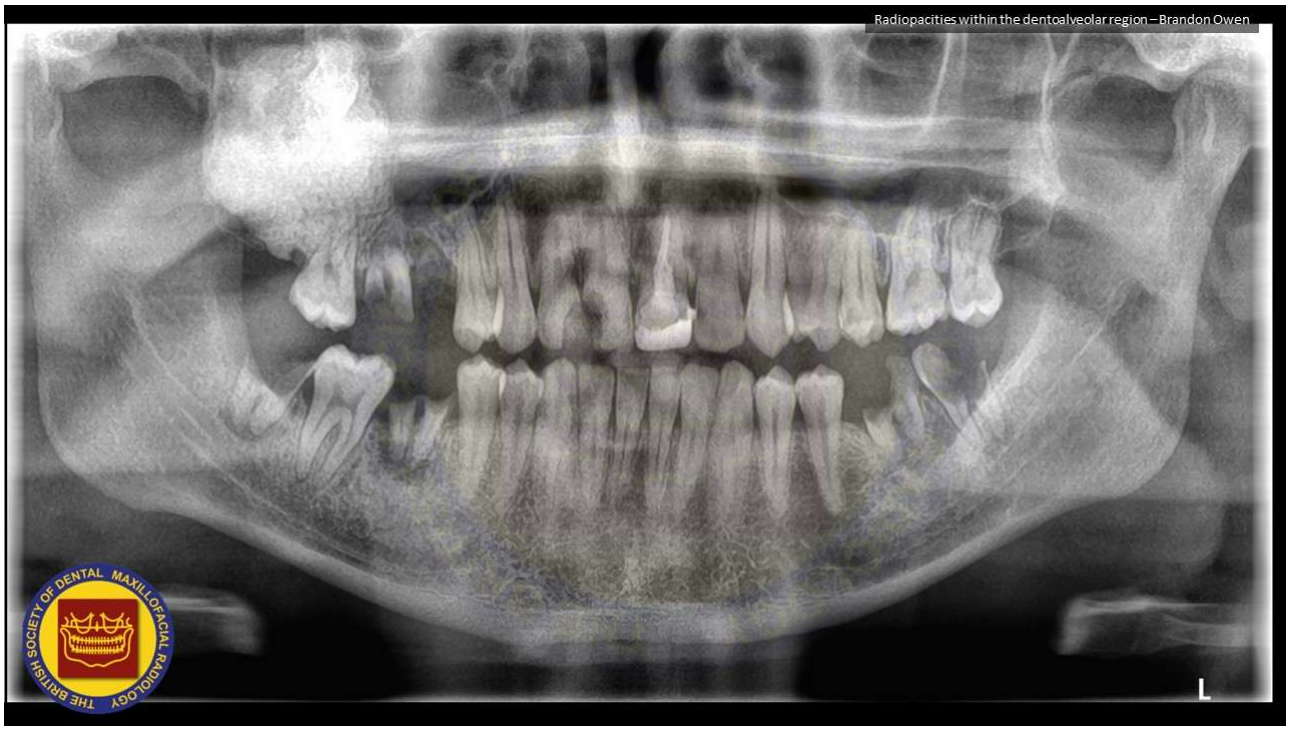
Radiopacities within the dentoalveolar region – Brandon Owen
L

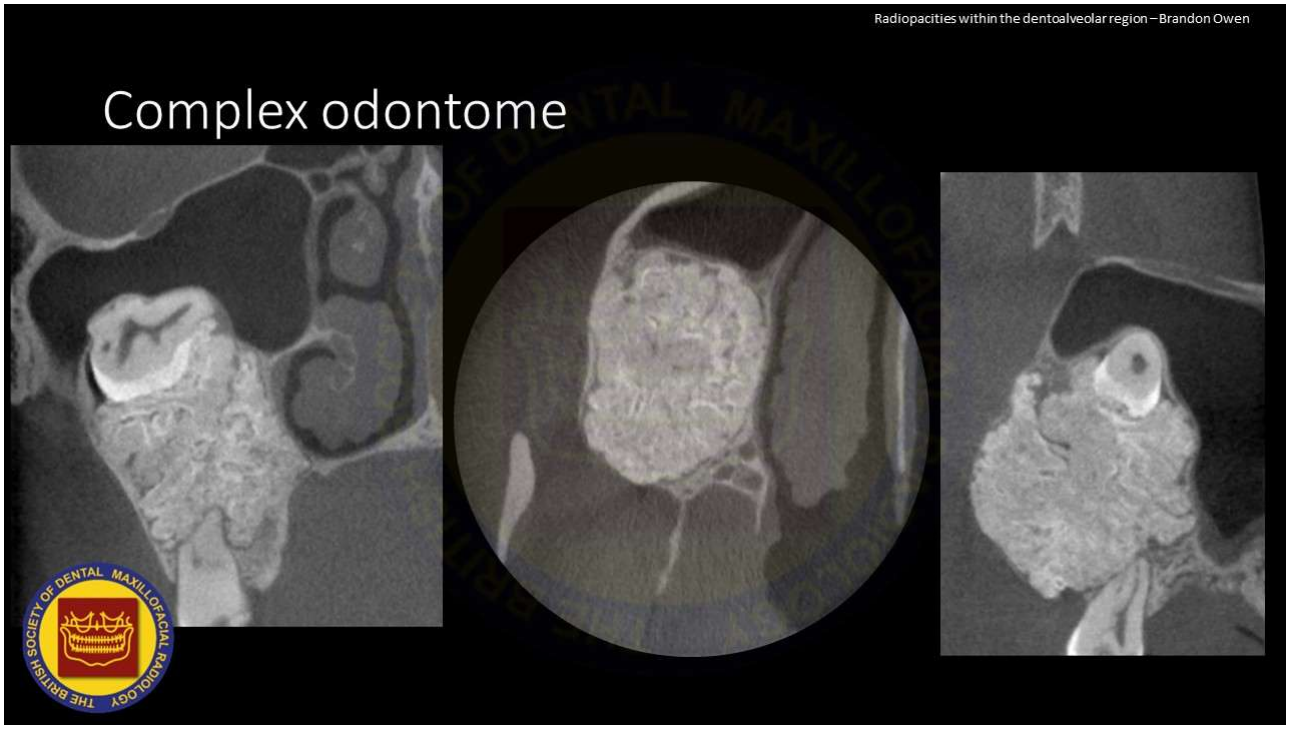
Radiopacities within the dentoalveolar region – Brandon Owen
Complex odontome

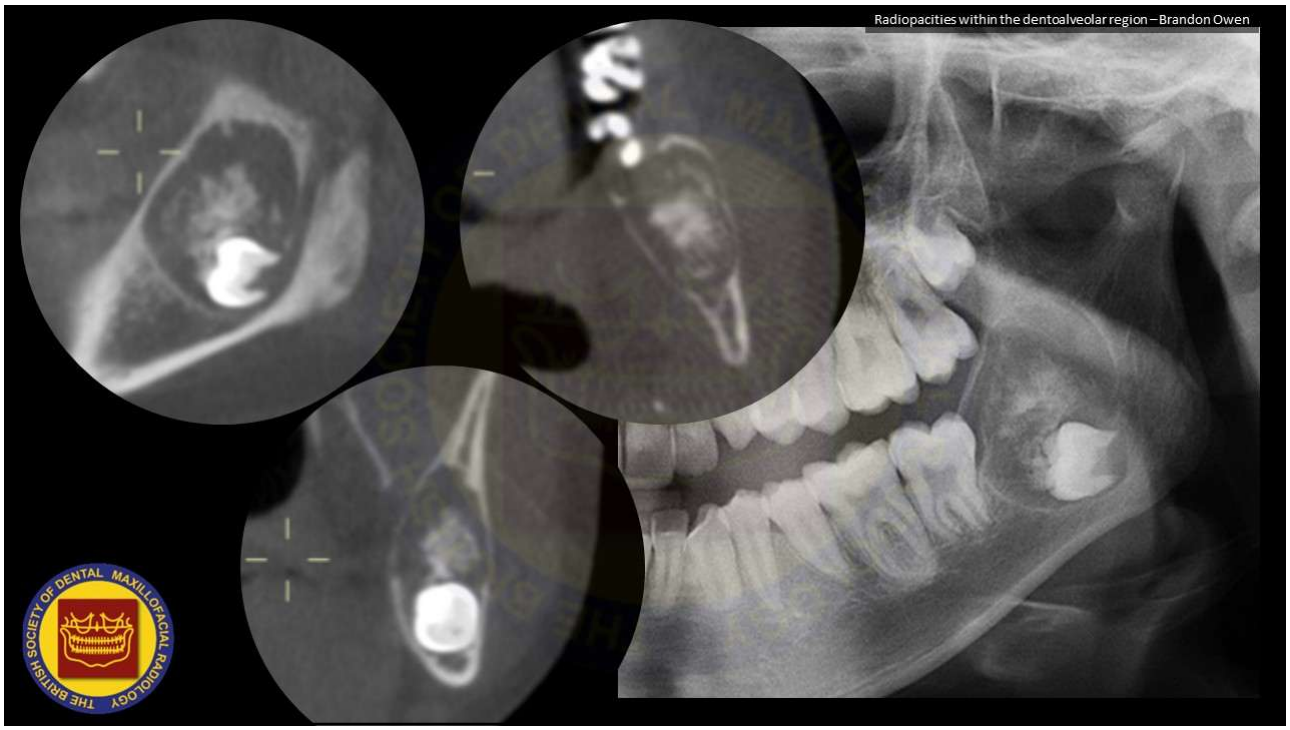
Radiopacities within the dentoalveolar region – Brandon Owen
THE BRITISH SOCIETY OF DENTAL MAXILLOFACIAL RADIOLOGY

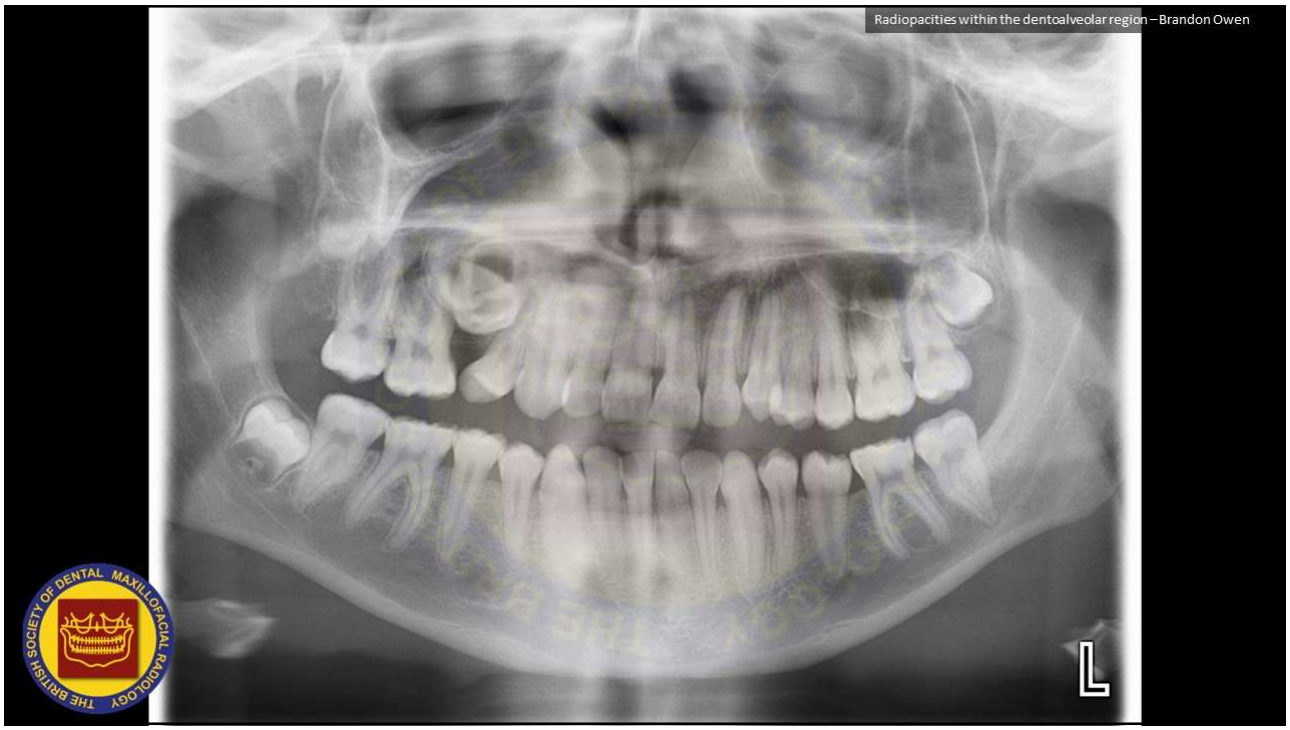
Radiopacities within the dentoalveolar region – Brandon Owen
THE BRITISH SOCIETY OF DENTAL MAXILLOFACIAL RADIOLOGY
L

# Dilated odontome

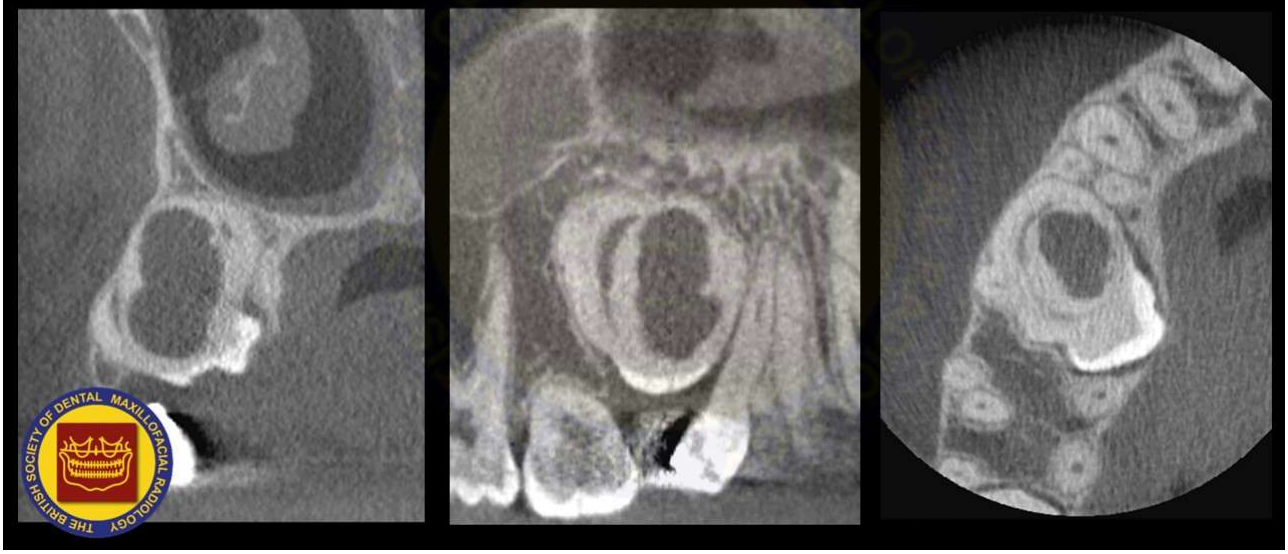



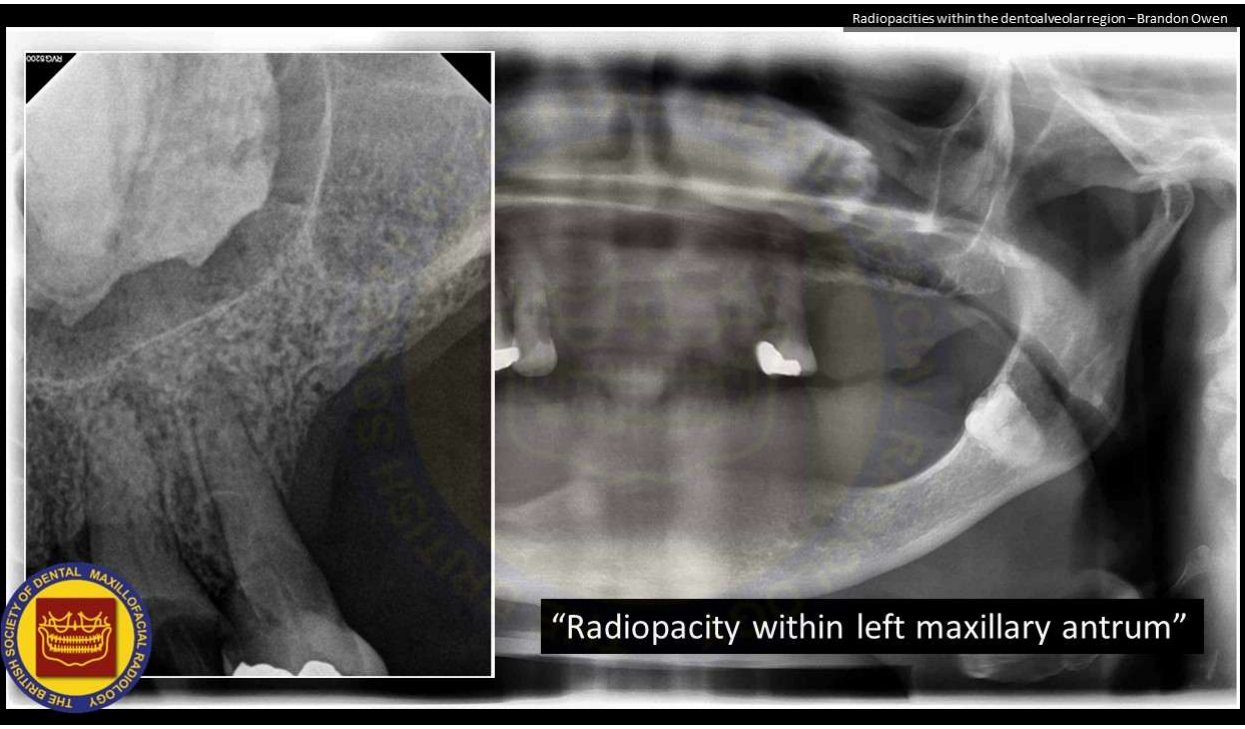

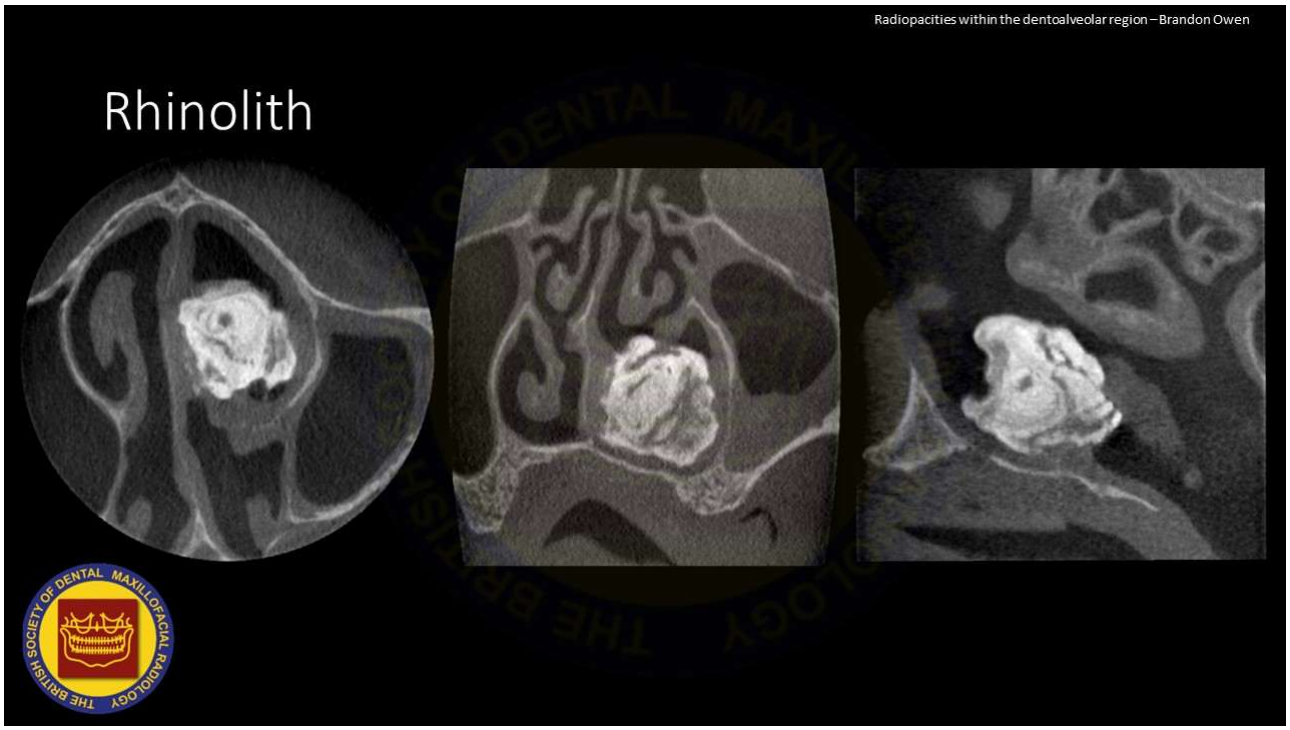
Radiopacities within the dentoalveolar region – Brandon Owen
Rhinolith

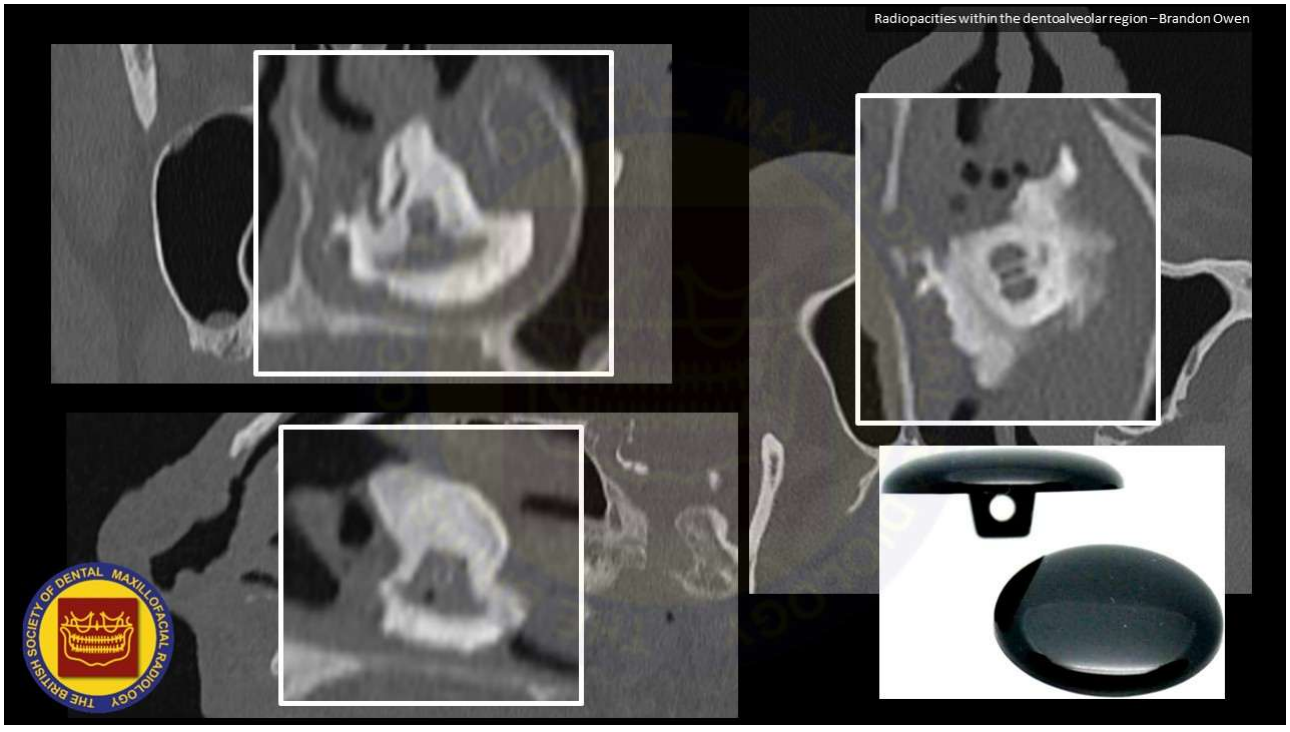
Radiopacities within the dentoalveolar region – Brandon Owen

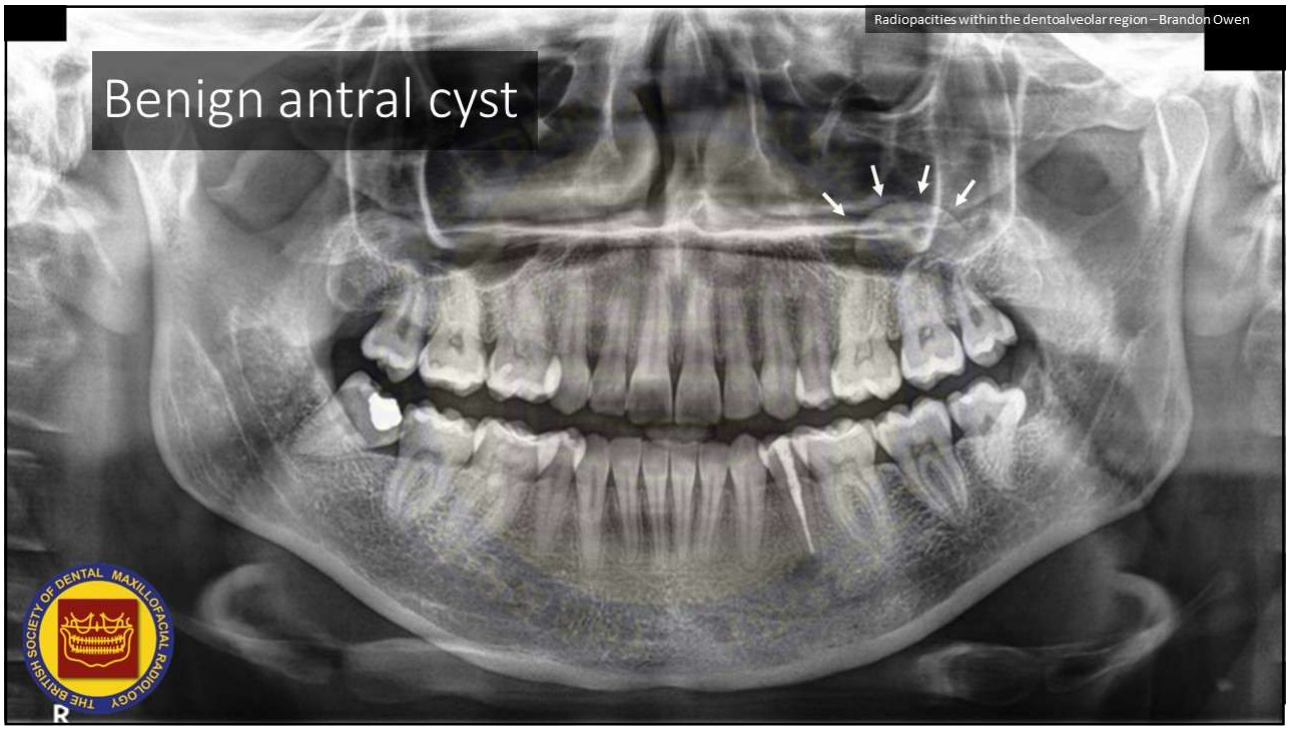
Radiopacities within the dentoalveolar region – Brandon Owen
Benign antral cyst
THE BRITISH SOCIETY OF DENTAL MAXILLOFACIAL RADIOLOGY
R

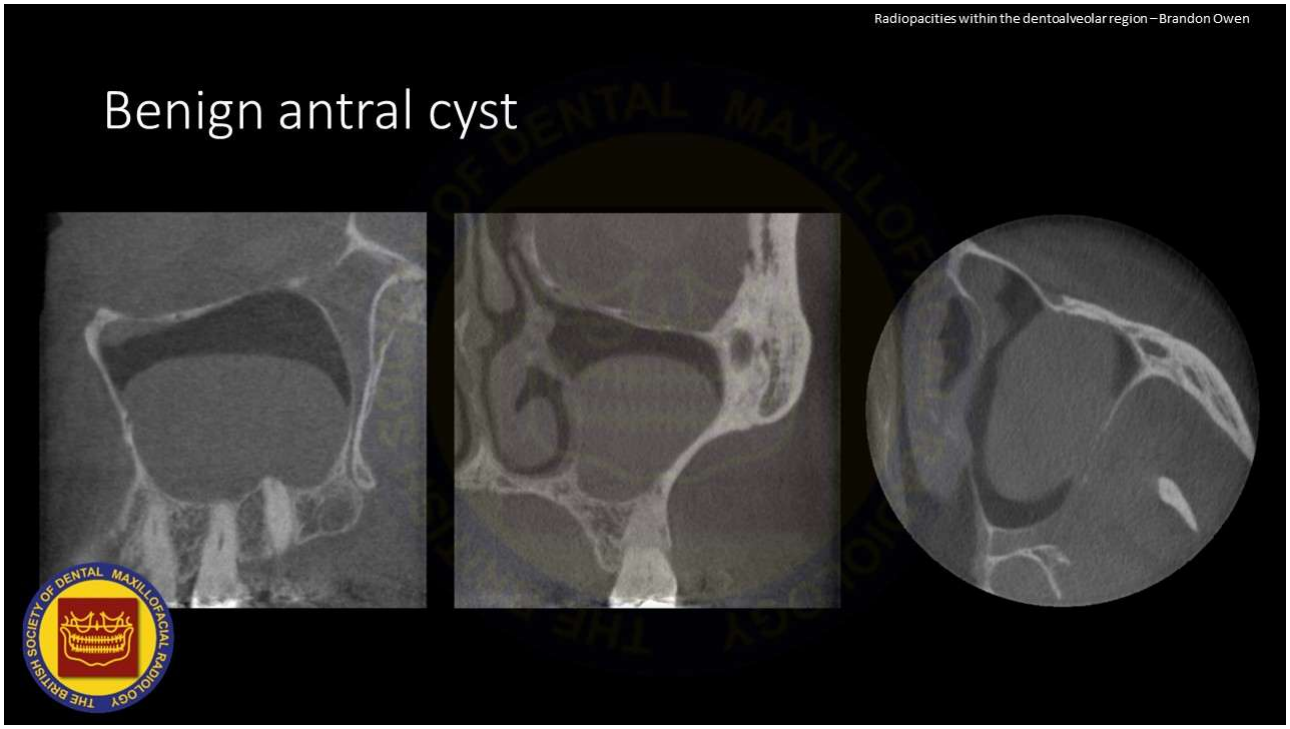
Radiopacities within the dentoalveolar region – Brandon Owen
Benign antral cyst
THE BRITISH SOCIETY OF DENTAL MAXILLOFACIAL RADIOLOGY

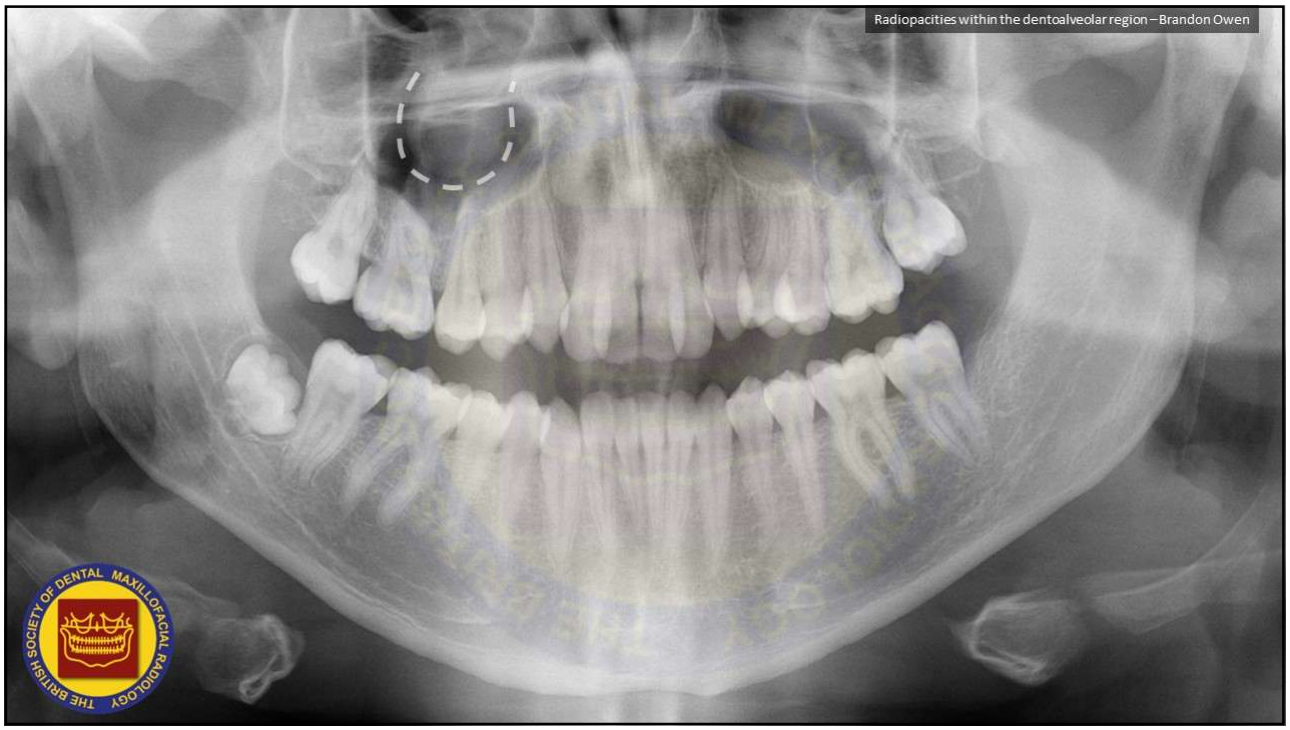
Radiopacities within the dentoalveolar region – Brandon Owen

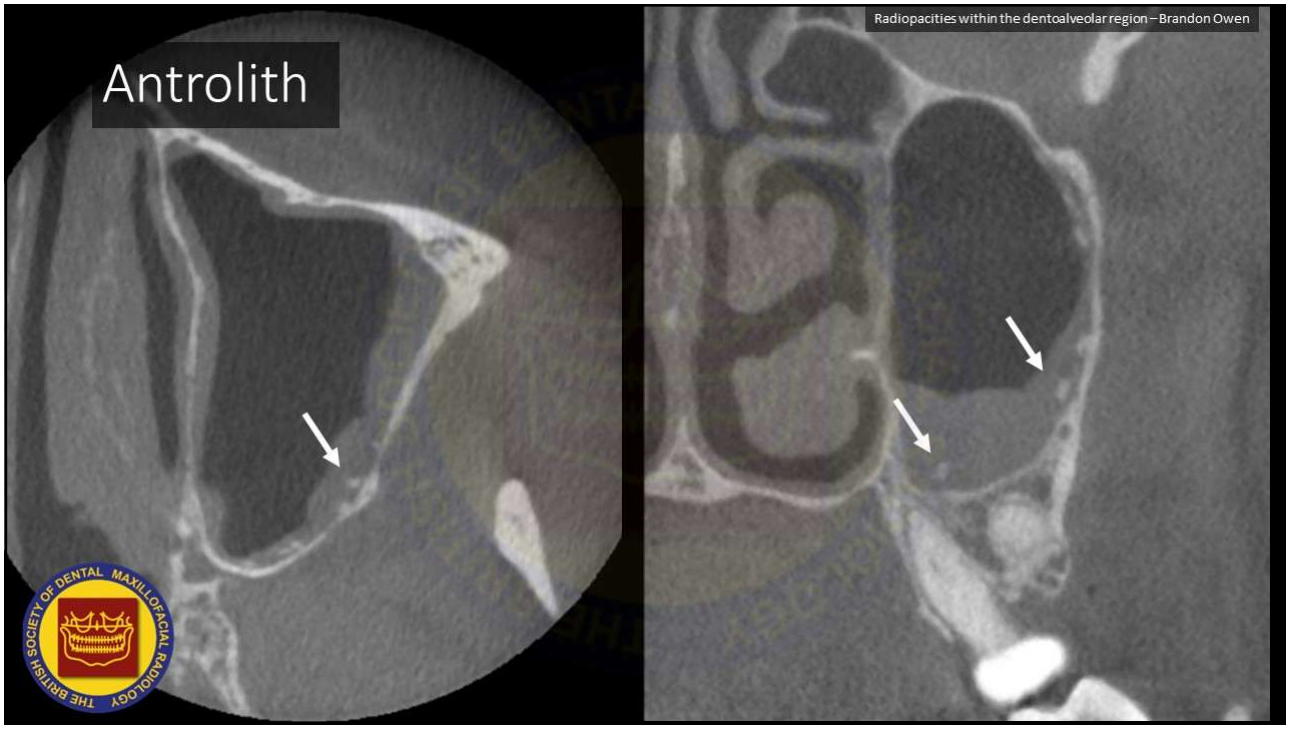
Antrolith
Radiopacities within the dentoalveolar region – Brandon Owen

# Calcinosis cutis

